



*Title:* A case of endocervical blue nevus

*Author:* Erra S.<sup>1</sup>

*Type:* Brief Report

*Keywords:* blue nevus;

### *Summary*

Uterine cervical mucosa is devoid of melanocytes, even if melanocytic lesions have been reported in this site on literature.

In the present article, we report a case of endocervical blue nevus in a postmenopausal woman with vaginal bleeding. Histological diagnosis has been made on a curettage material obtained from the gynaecological service of our hospital.

### *Background*

Blue nevus is a common pigmented lesion of skin , with described cases in oral , ocular and genital mucosa. It consists of spindle-shape, dendritic or epithelioid melanocytes dispersed in connective dermal or subepithelial tissue, sometimes with a pseudo-infiltrating pattern of growth.

Unusually localizations of this pigmented benign neoplasia have been reported on literature in prostate, pulmonary hilus, orbit, spermatic cord, maxillary sinus and breast lymph nodes (1, 2). In most of cases, histological detection of blue nevus has been an incidental finding during surgical removal made for other reasons.

---

<sup>1</sup> S.O.C. Anatomia Patologica  
A.S.L. AL, Casale Monferrato (AL)  
E-mail: [serra@aslal.it](mailto:serra@aslal.it)



### *Case presentation*

A 57 years old woman has been presented in gynaecological service of our hospital for vaginal bleeding. She refers to be in a menopausal status from one year, without assumption of hormonal medication. US and semeiotic pelvic exams have resulted negative.

A curettage has been made for diagnostic purpose and the material obtained has been processed in our surgical pathology department.

The unique paraffin-embedded inclusion and H.E. routine coloration stain obtained by the received champion has revealed endometrial mucosa of estrogenic aspect and a polipoid endocervical fragment of mucosa containing numerous spindle-shape and epithelioid pigmented cells dispersed among fibroblasts in stromal connective tissue (fig.1,2).

Immunostaining for anti human melan A monoclonal antibody (clone A3, Novocastra) has been made, with strong positivity of the described elements (fig.3).

A diagnosis of blue nevus in endocervical uterine polyp has been formulated.

### *Discussion*

Cervical pigmented lesions are rare, because uterine cervix mucosa is devoid of melanocytes. In world literature many pigmented genital lesions are reported such as melanosis (Deppisch, 1983), lentigo simplex (Schneider et al, 1981), one case of primitive malignant melanoma of cervix (Barauah et al, 2009) and sixty-three cases of blue nevus (Donofrio et al. 1992, Handa et al. 2007, Patel et al. 1985 ).

The first case referred in medicine dates 1883 in England and it was reported in a Britain article of 1922 (Bland-Sutton), where the author describes two similar cervix lesion in black women with uterine prolapse.

From 1959 to 2007 various reports have been made, the most representative being that published in 1985 on Human Pathology by Patel and Bhagavan , presenting a comprehensive review of the previously observed cases with detailed description of their three new lesions. These authors report fifty described cervical blue nevus, most of wich detected on hysterectomy specimens , only one case observed on curettage material and one case reported in a cervical polyp.

In recent years two Italian groups have reported pigmented endocervical lesions: five cases by Casadei and coll. in 1987 and one by Donofrio and coll. in 1992. Two Japanese groups (Uehara T et al) have published respected cases in 1991, and a Spanish one in 2004



(Zevallos-Giampietri et al), while in 2005 the coexistence of vulvar melanoma and blue cervical nevus in a same patient has been described (Hagiwara et al).

In 2007 an American group (Craddock et al) adds other two cases to the total described , a rare case of primary cervical melanoma being described two years later (Barauah et al). The last case has been reported by Szumilo and coll. in 2010 , while in the same period an American one published a case of blue nevus in the uterine myometrium (Eskue et al, 2010).

Examination of all the articles published and mentioned on this kind of lesion put in evidence three characteristics of cervical blue nevus: the absence of a preferred age, even if it results more frequent in postmenopausal women, the fact that it seems to be considered asymptomatic lesions and the serendipity of the most of the reported lesions. In fact, all the cases are referred as incidental findings histologically detected on surgical or bioptic specimens obtained for other purposes, generally for uterine fibromatosis or prolapse.

Our case represents the second reported one revealed in an endocervical curettage material and the second case described in a polyp. The postmenopausal woman affected by the endocervical blue nevus lamented occasional vaginal bleeding, caused from the endocervical polyp and not depending on the blue nevus.

As regards the histogenetic hypothesis of cervical blue nevus, the actually accepted one is that these pigmented lesions derive from immature melanoblasts migrating from the neural crest to the mullerian tract during embrional life. Ultrastructural and immunohistochemical studies support this theory, invalidating one of the previous hypotheses referring a Schwannian origin of the melanocytes in cervical mucosa. In some patient, hormonal climateric instability and mechanical local injury such as chronic irritation or presence on endocervical polyp could have a role in activating local melanocytic differentiation during the repair process of cervical epithelium.

Even if cervical blue nevus represents a clinical indolent pathology, it is useful to recognize this lesion, making a correct differential diagnosis with primary and metastatic malignant melanoma.





Figure 1: 10x

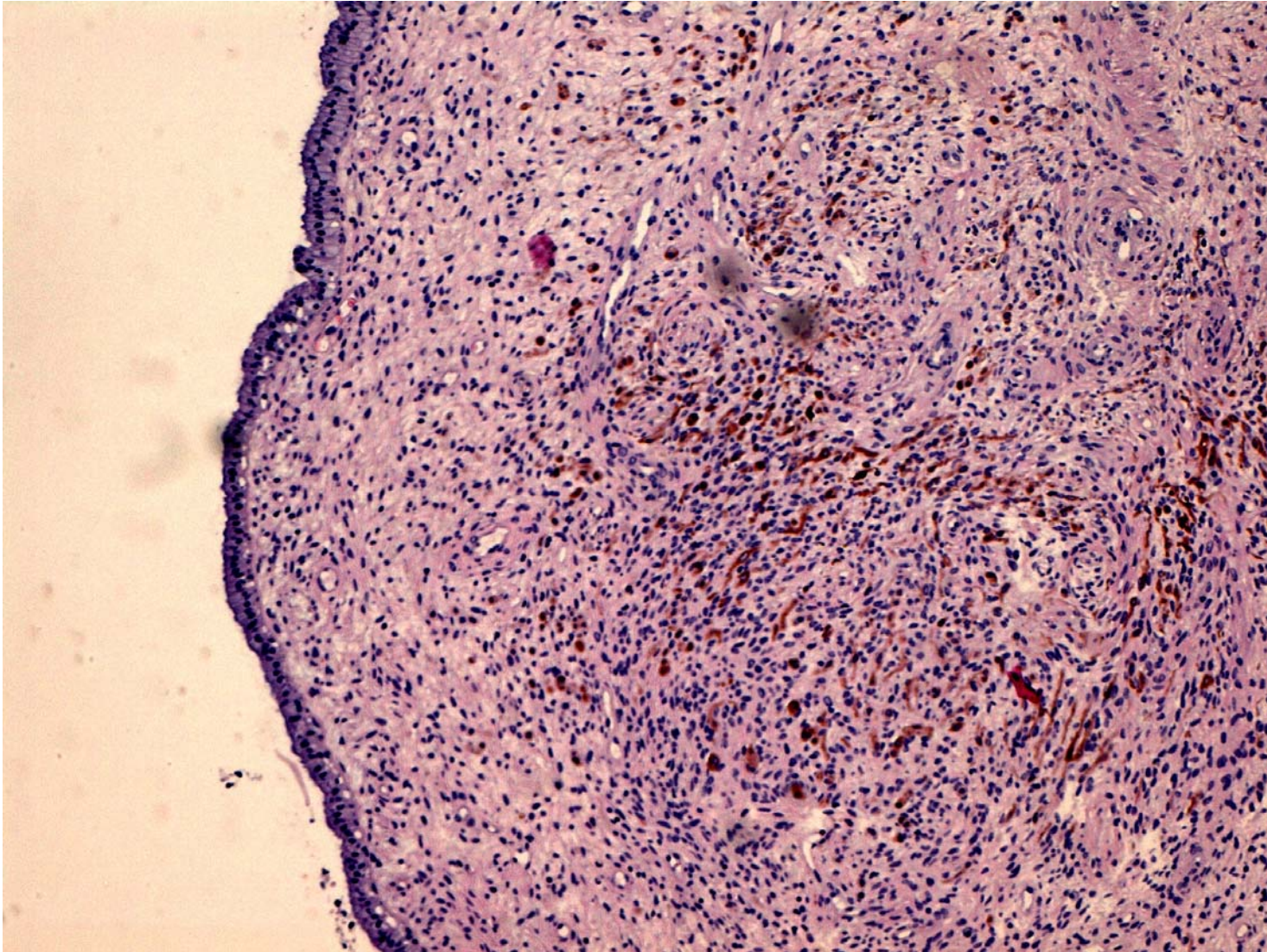
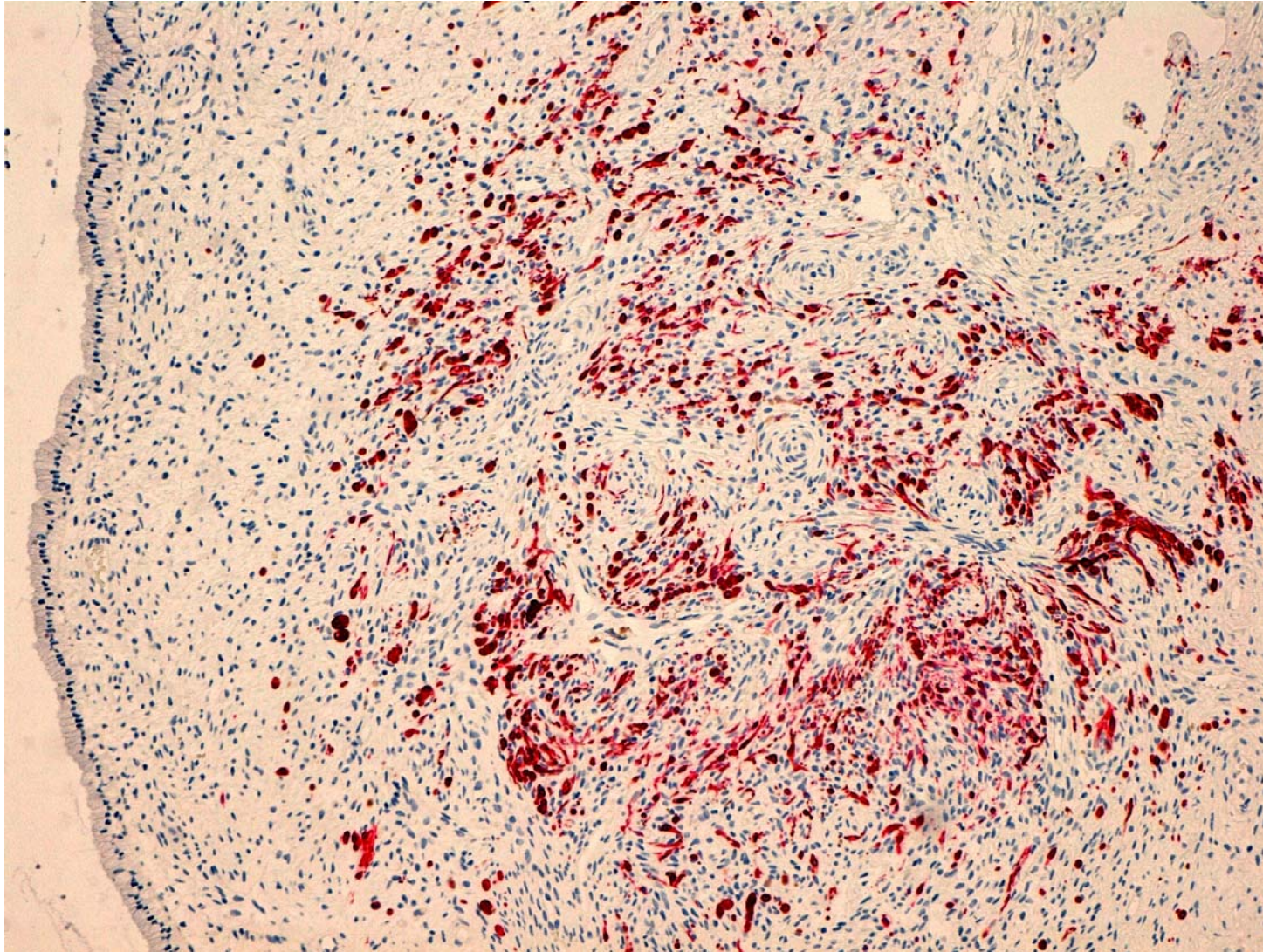






Figure 2: 10XIHC





*References:*

1. Barauah J, Roy KK, Kumar L. A rare case of primary malignant melanoma of cervix. *Arch Gynecol Obstet* 2009;280: 453-456.
2. Bland-Sutton. J. Tumors: innocent and malignant. London: Cassell 1922;122-3.
3. Casadei GP, Grigolato P, Cabibbo E. Blue nevus of the endocervix. A study of five cases. *Tumori* 1987;73(1): 75-9.
4. Cid JM. La pigmentation melanique de l'endocervix: un argumento visceral neurogenique. *Ann Anat Pathol (Paris)* 1959;4: 617-628.
5. Craddock KJ, Bandarchi B, Khalifa MA. Blue nevi of the Müllerian tract: case series and review of the literature. *J Low Genit Dis* 2007;11: 284-289.
6. Deppisch LM Cervical melanosis. *Obstet Gynecol* 1983;62: 525-526.
7. Donofrio V, Terracciano LM, Boscaino A, De Rosa G, Buffa D. Blue nevus of the uterine cervix. *Pathologica* 1992;83: 539-545.
8. Eskue K, Prieto VG, Malpica A. Cellular blue nevus of the uterus: a case report and review of the literature. *Int J Gynecol Pathol* 2010; 29(6):583-6.
9. Gonzalez-Campora R, Galera-Davidson H, Vazquez-Ramirez FJ et al. Blue nevus: classical types and new related entities. A differential diagnostic review. *Pathol Res Pract* 1994; 190(6): 627-35.
10. Hagiwara T, Kaku T, Kobayashi H, Hirakawa T, Nakano H. Coexisting vulvar malignant melanoma and blue nevus of the cervix. *Gynecol Oncol* 2005;99: 519-520.
11. Handa U, Mohan H, Garg S. Incidental detection of pigmented lesions in the cervix. *Aust N Z J Obstet Gynaecol* 2007;47: 254-255.
12. Patel DS, Bhagavan BS. Blue nevus of the uterine cervix. *Hum Pathol* 1985;16: 79-86.
13. Schneider V, Zimberg ST, Kay S The pigmented portio: benign lentigo of the uterine cervix. *Diagn Gynecol Obstet* 1981; 3: 269-272.
14. Szumilo J, Patel A, Patel S, Burdan F. Blue nevus of the endocervix. *Folia Morphol* 2010;69(1): 62-64.
15. Uehara T, Izumo T, Kishi K, Takayama S, Kasuga T. Stromal melanocytic foci ("blue nevus") in step section of the uterine cervix. *Acta Pathol Jpn* 1991;41: 751-756.



16. Uehara T, Takayama S, Takemura T, Kasuga T. Foci of stromal melanocytes (so-called blue naevus) of the uterine cervix in Japanese women. *Virchows Arch A Pathol Anat Histopathol* 1991;418:327-331.
17. Zevallos-Giampietri EA, Barrionuevo C. Common Blue nevus of the uterine cervix: case report and review. *Appl Immunohistochem Mol Morphol* 2004;12: 79-82.