

## A case of ocular thelaziasis in a 2.5 years old Holstein heifer

Mousa Daradka, Zuhair Bani Ismail

Department of Veterinary Clinical Sciences, Faculty of Veterinary Medicine, Jordan University of Science and Technology, Irbid, Jordan

### Abstract

A 2.5-years-old, Holstein lactating dairy cow was presented to the Veterinary Health Center with severe conjunctivitis and exuberant granulation tissue formation of the left eye. Upon close examination of the eye, a 2-cm long slender-shaped nematode was found in the conjunctival sac. The nematode was examined by a veterinary parasitologist and determined to be *Thelazia* species. The exuberant granulation tissue was surgically removed and a total of 0.5 mL of 1% levamisole was injected subconjunctivally. Levamisole was also injected subcutaneously at a dose of 10 mg/kg of body weight and repeated after 15 days. The cow made a complete recovery within 25 days following treatment. This is the first case report of ocular thelaziasis in dairy cattle in Jordan.

### Introduction

*Thelazia* is a nematode parasite that belongs to the order Spirurida of the superfamily Spiruroidea.<sup>1,3</sup> This nematode is known to infect the orbital tissues and has been found in several mammals, including cattle, horses, dogs and humans.<sup>4,5</sup> The parasite transmits between animals by means of non-biting dipteran flies of the genus *Musca* (*Muscidae*).<sup>6</sup> Third stage larvae (L3) are deposited in the eye while the adult fly feeds on lacrimal secretions where it molts into L4 and L5 stages.<sup>2,6</sup> Adult parasites live in the orbital tissues of the definitive host and both the larval stage and adults can cause ocular signs.<sup>2,6</sup> Ocular infection is characterized by excessive lacrimation, epiphora and conjunctivitis and in some cases severe keratitis and corneal ulceration.<sup>1,2,5</sup> Thelaziasis in cattle is caused by 3 species of *Thelazia* namely *Thelazia gulosa*, *Thelazia rhodesi* and *Thelazia skrjabini*.<sup>5</sup> Clinically, the disease is considered important because of its zoonotic nature.<sup>3,7</sup> The disease occurs in many countries including Europe, Africa and Asia.<sup>1,3</sup> This is the first case report of ocular thelaziasis in dairy cattle in Jordan.

### Case Report

A 2.5-years-old, Holstein lactating dairy cow was presented to the Veterinary Health Center of Jordan University of Science and Technology with conjunctivitis and exuberant granulation tissue formation of the left eye. The owner has noticed the problem in this eye for over 6 weeks. The cow was vaccinated against foot and mouth disease. Upon admission, the cow was in good body condition (BSC, 3 out of 5). The pulse, respiration rate and body temperature were within normal range for adult cows. The left eye was swollen and the eye ball fixed in position and extruded out of its socket. The conjunctiva was congested and protruding out of the eyelids and the third eyelid was swollen and edematous. The cornea was intact with slight opacity. Close examination of the eye was aided by performing a temporozygomatic nerve block using 10 mL of 2% lidocaine. The lacrimal duct was flushed using 22 g butterfly catheter and normal saline. A 2-cm long, slender-shaped nematode was found in the conjunctiva sac (Figure 1). A swap and slide imprint were taken from the conjunctival mucosa and a 1-cm<sup>3</sup> tissue sample was taken from the granulation tissues for histopathology. Histopathological examination of the lesion revealed an extensive infiltration of the third eyelid by large numbers of heterogeneous population of eosinophils, macrophages, lymphocytes, multinucleated giant cells and less frequently plasma cells. Marked fibroplasia, mul-

Correspondence: Mousa Daradka, Department of Veterinary Clinical Sciences, Faculty of Veterinary Medicine, Jordan University of Science and Technology, Ar Ramtha, Irbid 22110, Jordan.  
Tel.: +962.720.1000/22018 - Fax: +962.720.1081.  
E-mail: daradka@just.edu.jo

Key words: *Thelazia* species, conjunctivitis, dairy cattle, levamisole.

Contributions: the authors contributed equally.

Conflict of interests: the authors declare no potential conflict of interests.

Received for publication: 16 July 2014.  
Accepted for publication: 20 August 2014.

This work is licensed under a Creative Commons Attribution NonCommercial 3.0 License (CC BY-NC 3.0).

©Copyright M. Daradka and Z.B. Ismail, 2014  
Licensee PAGEPress srl, Italy  
Veterinary Science Development 2014; 5:5555  
doi:10.4081/vsd.2014.5555

tifocal areas of lytic and coagulative necrosis and mild edema were evident throughout the section. The exuberant granulation tissue was surgically removed and a total of 0.5 mL of 1% levamisole was injected subconjunctivally. Levamisole was also injected subcutaneously at a dose of 10 mg/kg of body weight and

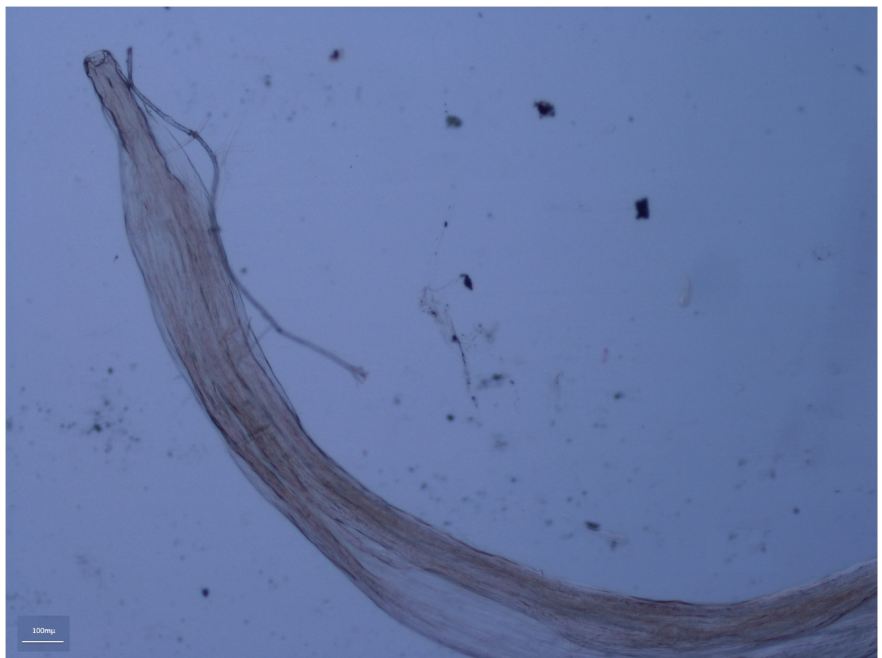


Figure 1. A photograph of the anterior portion of the nematode identified to be *Thelazia* species recovered from the conjunctival sac of a 2.5-years old Holstein heifer with conjunctivitis. Bar 100  $\mu$ m.

repeated after 15 day. The cow made a complete recovery within 25 days following treatment.

## Discussion and Conclusions

Thelaziasis is well known in the tropical zone of the world. Jordan lies in the temperate zone above the tropic line of the cancer (31°0'0"N; 36°0'0"E). The intermediate host of the parasite has a seasonal high activity during the spring and summer in Jordan. Human thelaziasis have been reported in several regions over the world.<sup>3,7</sup> Human thelaziasis is characterized by slight irritation of the conjunctiva, eye discomfort, and follicular hypertrophy.<sup>3,7</sup> Although, not well documented, *Thelazia* species infecting cattle could be contagious to farmers and care should be exercised where the disease is present.

While conjunctivitis is not uncommon in cattle, the list of differential diagnoses for a cow with conjunctivitis, granulation tissue formation, and excessive lacrimation may include cases of traumatic lesions to the conjunctiva and eye ball, foreign body in the conjunctival sac, squamous cell carcinoma, occlusion of the lacrimal duct, bacterial keratoconjunctivitis (*Moraxella bovis*), viral infections such as malignant catarrhal fever, infectious bovine rhinotracheitis, fungal infections, and myiasis (dirofilariosis and habronomiasis).<sup>5,8</sup> The diagnosis of *Thelazia* infection can only be confirmed by finding the adult or larval stage

in the eye as it was in this case.

Bovine thelaziasis can be successfully treated using local and systemic antiparasitic drugs.<sup>8-11</sup> Symptomatic treatment to ease ocular pain and inflammation is usually indicated. In this case, the cow made a full recovery following a single, subconjunctival administration of levamisole and subcutaneous administration of the drug twice, 2 weeks apart. The mass of granulation tissue that was surgically removed may have formed as a result of repeated self-inflicted trauma while the cow is trying to scratch the irritated eye by the presence of the parasite. In this report, the clinical presentation of *Thelazia* species ocular infection and its successful treatment is being described for the first time in Jordan.

## References

- Otranto D, Lia RP, Buono V, et al. Biology of *Thelazia callipaeda* (Spirurida, Thelaziidae) eyeworms in naturally infected definitive hosts. *Parasitol* 2004;129: 627-33.
- Otranto D, Traversa D. *Thelazia* eyeworm: an original endo- and ecto-parasitic nematode. *Trends Parasitol* 2005;21:1-4.
- Viriyavejakul P, Krudsood S, Monkhonmu S, et al. *Thelazia Callipaeda*: a human case report. *Southeast Asian J Trop Med Public Health* 2012;43:851-6.
- Koyama Y, Ohira A, Kono T, et al. Five cases of thelaziasis. *Br J Ophthalmol* 2000;84:441.
- Otranto D, Tarsitano E, Traversa D, et al. Differentiation among three species of bovine *Thelazia* (Nematoda: Thelaziidae) by polymerase chain reaction–restriction fragment length polymorphism of the first internal transcribed spacer ITS-1 (rDNA). *Int J Parasitol* 2001;31:1693-8.
- O'Hara JE, Kennedy MJ. Development of the nematode *Thelazia skrjabini* (Nematoda: Thelazioidea) in experimentally infected face flies *Musca autumnalis* (Diptera: Muscidae). *J Parasitol* 1991;77: 417-25.
- Xue C, Tian N, Huang Z. *Thelazia callipaeda* in human vitreous. *Can J Ophthalmol* 2007; 42:884-5.
- Radostits OM, Gay CC, Hinchcliff KW, Constable P. *Veterinary medicine. A textbook of the diseases of cattle, horses, sheep, pigs, and goats*. 10. ed. Philadelphia: Saunders; 2007.
- Kennedy MJ. The efficacy of ivermectin against the eyeworm, *Thelazia skrjabini*, in experimentally infected cattle. *Vet Parasitol* 1992;45:127-31.
- Soll MD, Carmichael IH, Scherer HR, Gross SJ. The efficacy of ivermectin against *Thelazia rhodesii* (Desmarest, 1828) in the eyes of cattle. *Vet Parasitol* 1992;42:67-71.
- Kennedy MJ, Phillips FE. Efficacy of doramectin against eyeworms (*Thelazia* spp.) in naturally and experimentally infected cattle. *Vet Parasitol* 1993;49:61-6.