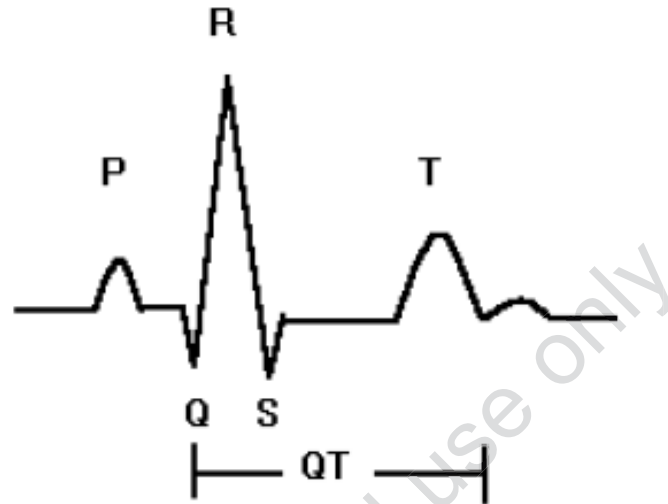
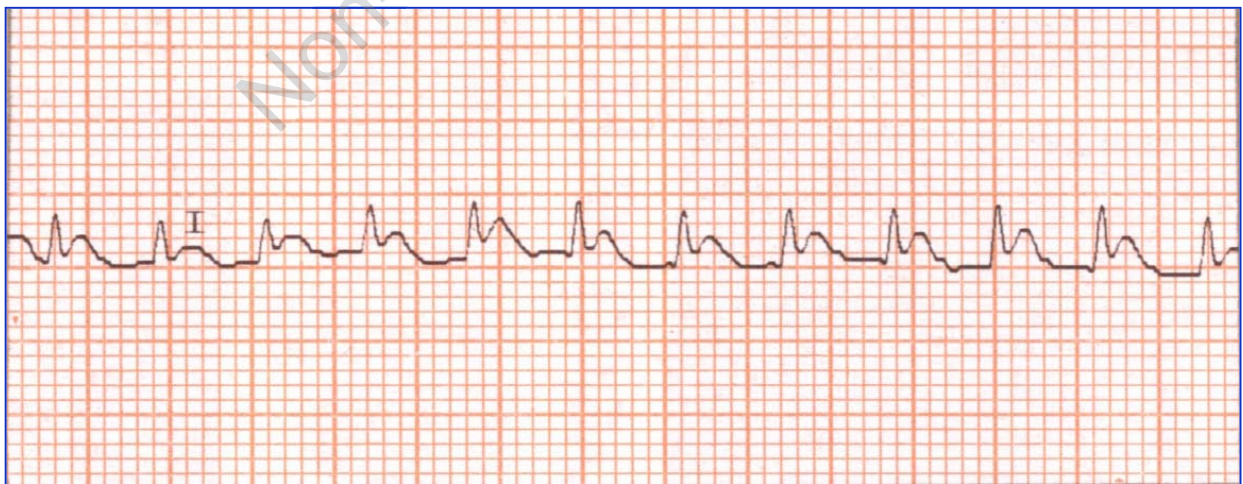

## Additional materials

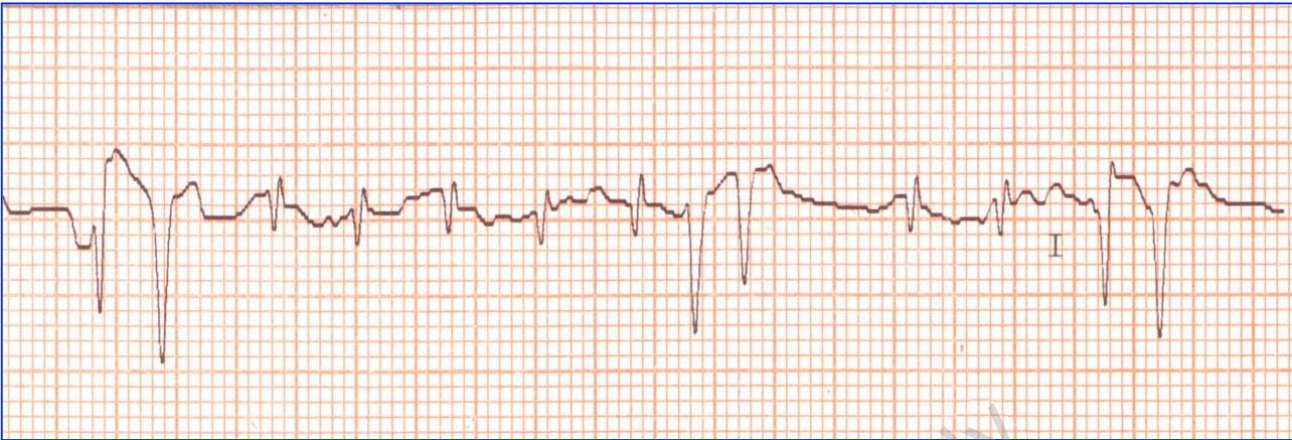Electrocardiogram waves and QT interval.



Electrocardiogram #1 recorded during ischemia.



Electrocardiogram #2 recorded at day 7.



Non-commercial use only