

# Cicatricial alopecia associated with pemphigus

Roberto D'Astolto, Chiara Zangrando, Claudio Feliciani

Dermatology U.O.C, Department of Medicine and Surgery, University of Parma, Italy

## Abstract

Pemphigus is a chronic autoimmune bullous disease associated with the production of autoantibodies directed against desmosomal proteins, such as desmogleins 1 and 3. Here, we present the case of an 83-year-old woman who was referred to us with suspicious cicatricial alopecia of the scalp and a small, eroded lesion on the forehead, previously labeled as atrophic actinic keratosis after a skin biopsy. In our clinic, after a careful examination of the case, we decided to perform two new skin biopsies of the scalp on suspicion of an inflammatory disease.

Correspondence: Chiara Zangrando, Dermatology U.O.C, Department of Medicine and Surgery, University of Parma, Italy.  
Tel.: +39.3347791411.  
E-mail: chiarazangrando11@gmail.com

Key words: pemphigus, cicatricial alopecia, bullous disease.

Contributions: the authors contributed equally.

Conflict of interest: the authors declare no potential conflict of interest.

Ethics approval and consent to participate: no ethical committee approval was required by the Department for this case report.

Patient consent for publication: the patient gave her written consent to use her personal data for the publication of this case report and any accompanying images.

Funding: none.

Availability of data and materials: all data underlying the findings are fully available.

Received for publication: 21 December 2022.

Accepted for publication: 10 January 2023.

Early view: 14 June 2023.

This work is licensed under a Creative Commons Attribution-NonCommercial 4.0 International License (CC BY-NC 4.0).

©Copyright: the Author(s), 2023

Licensee PAGEPress, Italy

Dermatology Reports 2023; 15:9653

doi:10.4081/dr.2023.9653

*Publisher's note: all claims expressed in this article are solely those of the authors and do not necessarily represent those of their affiliated organizations, or those of the publisher, the editors and the reviewers. Any product that may be evaluated in this article or claim that may be made by its manufacturer is not guaranteed or endorsed by the publisher.*

## Introduction

Pemphigus is an autoimmune bullous disease with a chronic intercourse and potentially fatal prognosis related to the self-production of antibodies against desmogleins (DSG), fundamental proteins for the cohesion of keratinocytes.

The process of separation of keratinocytes, *i.e.* acantholysis, according to its localization allows the distinction between the superficial (pemphigus foliaceus, pemphigus erythematous or seborrheic) and deep [pemphigus vulgaris (PV), pemphigus vegetating] forms; variants are recognized.

PV is the most common form and affects both the skin and the mucous membranes: the mucous form is generally associated with antibodies against DSG3, and the mucocutaneous form with both DSG3 and DSG1.

The diagnosis of pemphigus is established on the basis of histopathological findings on perilesional skin biopsies and immunofluorescence techniques on the serum or skin of patients, which show the presence of autoantibodies directed against the DSG of keratinocyte membranes. The therapeutic gold standard is represented by corticosteroids (topical or oral), which have recently been overtaken by CD20 monoclonal antibodies (rituximab) in mild-severe and severe forms.<sup>1</sup>

We report the case of a woman with an unusual cicatricial alopecia of the scalp, clinically indistinguishable from the pemphigoid of Brusting-Perry,<sup>2</sup> or other inflammatory skin diseases such as discoid lupus erythematosus or lichen planopilaris.

## Case Report

An 83-year-old woman was sent to our dermatology clinic with a large erythematous burning plaque on the scalp, covered by yellow crusts. Areas of cicatricial alopecia with follicular hyperkeratosis in the context of the lesion were present (Figure 1a).

This lesion manifested one year earlier with progressive worsening. She previously performed an incisional skin biopsy with a histological diagnosis of atrophic actinic keratosis with acantholytic aspects and ulceration. As for the rest of the skin and mucosal surface area that can be involved, different types of trauma may precipitate a flare-up of lesions;<sup>3</sup> this may explain why, after years of erroneous therapies aimed at the treatment of suspected actinic keratoses, there has been a drastic worsening of the general scalp conditions. We oriented our diagnostic spectrum toward an inflammatory and not neoplastic disease, so we decided to perform a deeper skin biopsy. The histological outcome showed a marked hyperparakeratosis with erosion and diffuse suprabasal acantholysis, with an expanded papillary dermis, fibrotic with a discrete mixed inflammatory infiltrate, compatible with a superficial form of pemphigus. Moreover, the Biochip Array technique was performed, looking for the main antibodies associated with autoimmune bullous diseases: it tested positive for antibodies directed against spiny cells and DSG3; it tested negative for antibodies directed against DSG1 and all the proteins related to

bullous pemphigoid (including BP180, BP230, type VII collagen, and laminin 332).

The patient then undertook pickling therapy associated with topical and oral steroids; after a month, there was an important improvement in the general clinical and dermatological presentation, despite the discontinuation of the treatment after three weeks due to the onset of hypertensive peaks (Figure 1b).

Ten months after decalage of the oral steroids, she had a complete remission of the lesions of the scalp (Figure 1c).

Total-body ultrasound scans and blood tests required were basically normal, but when she performed a colonoscopy, it revealed a stenosing lesion of the large intestine. The diagnosis after a biopsy of the mass was compatible with a large intestine adenocarcinoma.

## Discussion

We present a case of secondary cicatricial alopecia with follicular hyperkeratosis clinically close to Brunsting-Perry pemphigoid, with which, however, it does not share the positivity of the antibodies against BP180 and BP230.

In the literature, cases of PV associated with anagen hair loss, tufted hair folliculitis, and patchy alopecia have been described.<sup>4-6</sup> Anyway, hair loss and areas of cicatricial alopecia with follicular hyperkeratosis are very rare, even in patients with scalp erosions.

Our patient has a peculiar form of pemphigus, described as superficial by the histopathologist, with positivity of DSG3 and no mucosal involvement. Furthermore, the Biochip Array showed positivity for anti-DSG3 antibodies, located in the basal layer of the epidermis close to the dermoepidermal junction; it approached our patient near the spectrum of pemphigoid, where antibodies anti-subepidermal proteins are involved.

In patients with pemphigus, flaccid blisters and erosions of the scalp are observed in up to 60% of cases, mostly in men.<sup>7</sup> This could be due to the abundance of DSG localized in hair follicles.

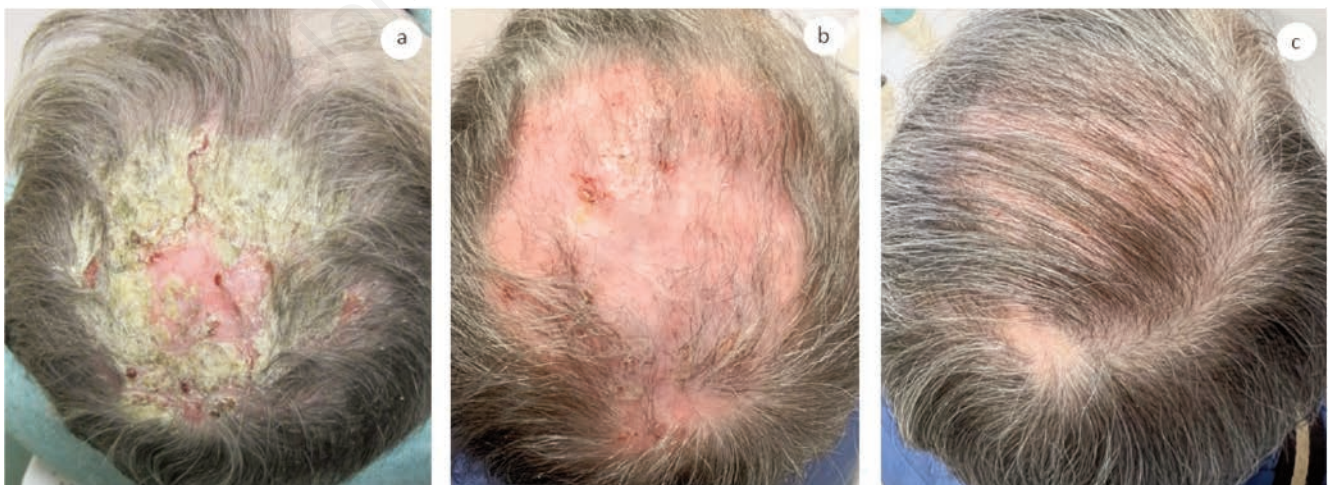
Despite the fact that the scalp is a fairly common area of pemphigus, alopecia is considered rare,<sup>8</sup> with an estimated frequency of 5.4% in patients with PV.<sup>9</sup> Furthermore, the expression of DSG has been shown to be related to the state of differentiation of defined cell populations within the hair follicle.

In fact, DSG2 is highly expressed by the least differentiated cells of the skin epithelium, the hair follicle bulge, bulb matrix cells, and the basal layer of the outer root sheath, while DSG1 is more present in more differentiated cell populations of the cutaneous epithelium, in the inner root sheath, and in the innermost layers of the outer root sheath. Instead, DSG3 is related to different types of keratinization,<sup>10</sup> and it is necessary for anchoring cells of the deep stratified epithelium and the telogen hair to the sheath of the outer root of the follicle.<sup>11</sup> This underlines the link between DSG3 and hair anchoring to the scalp; it is then possible that the lower efficiency of DSG3 seen in our patient could explain cicatricial alopecia. We could introduce a new form of Brunsting-Perry-like pemphigus, never described till now, although more studies are required to confirm this hypothesis.

## Conclusions

To conclude, the scalp is a common area for pemphigus because of the high load of DSG distributed in hair follicles. However, what is uncommon is the presence of cicatricial alopecia. We cannot say for sure if there is a common antigen between the two bullous diseases of the scalp; what is sure is that it is clinically indistinguishable from a Brunsting-Perry bullous pemphigoid, where BP180 has been identified as a target autoantigen in 80.0% of cases, BP230 in 33.3%, and laminin 332 in 20.0%.<sup>12</sup>

The case reported here presents a rare form of cicatricial alopecia related to PV in which, after setting up adequate therapy, there was a clinical and symptomatic improvement despite the poor compliance of the patient.



**Figure 1.** a) Extended vulgaris crusty pemphigus with erosions and cicatricial alopecia of the scalp; b) after 8 weeks of treatment with topical 10% salicylic vaseline, topical, and oral steroids; c) after 10 months of treatment with topical 10% salicylic vaseline, topical, and oral steroids.

## References

1. Schmidt E, Kasperkiewicz M, Joly P. Pemphigus. *Lancet* 2019;394:882-94.
2. Reis Gavazzoni Dias MF, Aparecida Guedes Vilar E, de Oliveira Bento C, et al. Brunsting-Perry type pemphigoid causing secondary cicatricial alopecia in 2 patients. *Skin Appendage Disord* 2018;4:308-11.
3. Daneshpazhooh M, Fatehnejad M, Rahbar Z, et al. Trauma-induced pemphigus: a case series of 36 patients. *J Dtsch Dermatol Ges* 2016;14:166-71.
4. Daneshpazhooh M, Mahmoudi HR, Rezakhani S, et al. Loss of normal anagen hair in pemphigus vulgaris. *Clin Exp Dermatol* 2015;40:485-8.
5. Jappe U, Schröder K, Zillikens D, Petzoldt D. Tufted hair folliculitis associated with pemphigus vulgaris. *J Eur Acad Dermatol Venereol* 2003;17:223-6.
6. Veraitch O, Ohyama M, Yamagami J, Amagai M. Alopecia as a rare but distinct manifestation of pemphigus vulgaris. *J Eur Acad Dermatol Venereol* 2013;27:86-91.
7. Esmaili N, Chams-Davatchi C, Valikhani M, et al. Pemphigus vulgaris in Iran: a clinical study of 140 cases. *Int J Dermatol* 2007;46:1166-70.
8. Sar-Pomian M, Rudnicka L, Olszewska M. The significance of scalp involvement in pemphigus: a literature review. *Biomed Res Int* 2018;2018:6154397.
9. Sar-Pomian M, Czuwara J, Rudnicka L, Olszewska M. Increased risk of severe course of pemphigus in patients with pemphigus-associated alopecia: a prospective observational study. *Clin Exp Dermatol* 2019;44:e73-e80.
10. Wu H, Stanley JR, Cotsarelis G. Desmoglein isotype expression in the hair follicle and its cysts correlates with type of keratinization and degree of differentiation. *J Invest Dermatol* 2003;120:1052-7. Erratum in: *J Invest Dermatol* 2003;121:434.
11. Koch PJ, Mahoney MG, Cotsarelis G, et al. Desmoglein 3 anchors telogen hair in the follicle. *J Cell Sci* 1998;111:2529-37.
12. Aromolo IF, Maronese CA, Moltrasio C, et al. Brunsting-Perry pemphigoid: a systematic review. *Int J Dermatol* 2022;61:1353-8.