

Combined cetuximab and volumetric modulated arc-radiotherapy in advanced recurrent squamous cell carcinoma of the scalp

Uwe Wollina,¹ Andreas Schreiber,²
Knut Merla,² Gunter Haroske³

¹Department of Dermatology and Allergology, ²Department of Radiology, and ³Institute of Pathology Georg Schmorl, Academic Teaching Hospital Dresden-Friedrichstadt, Dresden, Germany

Abstract

A 77-year old male patient presented with an ulcerated exophytic tumor (T2, N0, M0) with three macroscopically visible satellite metastases in the right temporo-occipital region. Mohs surgery could not control the disease due to lymphangiosis carcinomatosa and perineural infiltration, and recurrence of satellite skin metastases. Re-staging demonstrated a T2, N1, M0 profile (stage III, AJCC). Chemotherapy was limited by the patient's co-morbidities. Therefore, we used targeted therapy with monoclonal anti-epidermal growth factor receptor antibody cetuximab in combination with volumetric modulated arc- radiotherapy (VMAT). Cetuximab was well tolerated except for the loading dose when the patient developed fever chills. To verify the correct application of VMAT, it was applied to a 3-dimensional measuring phantom prior to the patient's first treatment session. To minimize these tolerances, patient set-up was checked and corrected by orthogonal fluoroscopic images recorded daily by the on-board imager used in our Varian accelerator. The average daily beam time was 6 min (6 arcs, 767 monitor units); the total treatment time including patient set-up and set-up correction was less than 20 min. Combined therapy was well tolerated and complete remission was achieved.

Introduction

Squamous cell carcinoma (SCC) is one of the most important non-melanoma skin cancers (NMSC) because of its frequency and because it has a more aggressive course than basal cell carcinoma (BCC), the most common NMSC. SCC development has been linked to chronic UV exposure with an Odds Ratio of 1.77.¹ Patient related incidence rates for cuta-

neous SCC in Germany has been estimated at 9.7 for females and 17.4 for males.² Higher incidence rates in Europe have been reported for Scotland (34.7)³ and Spain.⁴

Diagnosis of SCC depends on clinical data and histopathology. Tumor staging is dependent on tumor diameter, invasion into cranial bone, tumor thickness and invasion level, differentiation, perineural invasion and anatomic location. Furthermore, regional lymph nodes and distant metastases have to be considered.⁵ The standard treatment of SCC of the head and neck area is Mohs surgery or delayed Mohs. For advanced SCC, radiation therapy is another therapeutic option.^{6,7}

Since conventional chemotherapy in head and neck SCC (HNSCC) of the mucous membranes is associated with significant toxicity, alternatives for cutaneous SCC have emerged. A phase III trial with bleomycin versus other chemotherapy protocols, and prospective observational studies using bleomycin, cisplatin, doxorubicin or oral 5-fluorouracil (5-FU), had low rates of complete responses (0-33%) but significant adverse effects.⁸ Interferon in combination with capecitabine (an oral prodrug of 5-FU) is effective in SCC of the head and neck region⁹ and in the reduction of SCC developing in transplant recipients.¹⁰ Response rates of 100% and complete responses of up to 50% have been reported.^{9,10}

Advanced SCC shows numerical aberrations in the epidermal growth factor-receptor (EGFR) gene and overexpression of EGF/EGFR.¹¹⁻¹⁴ Therefore, targeted therapy against EGF-receptor (EGFR) would be another option. Recently, monoclonal antibodies against EGFR have become available, including gefitinib, erlotinib, cetuximab and panitumumab.¹⁵

Cetuximab is a 152 kDa chimeric IgG1 monoclonal antibody of 65% human and 35% murine origin. It specifically binds to EGFR at an extracellular epitope in the ligand-binding domain.¹⁶ Pharmacokinetics of single and multiple doses have been extensively evaluated. The drug half-life is 70-100 h.¹⁷

There are encouraging data from HNSCC using cetuximab in the treatment of recurrent or metastatic tumors, either alone or in combination with radiation or chemotherapy. Response rates vary between 10-71%. Since 2006, cetuximab is approved for use in combination with radiotherapy in patients with locally advanced HNSCC.¹⁸⁻²²

There are limited data available for cetuximab therapy in advanced cutaneous SCC of the head and neck region.²³⁻²⁷ We present a patient who was successfully treated by cetuximab combined with radiation for locally advanced cutaneous SCC of the scalp.

Correspondence: Uwe Wollina, Department of Dermatology and Allergology, Academic Teaching Hospital Dresden-Friedrichstadt, Friedrichstrasse 41, 01067 Dresden, Germany.
E-mail: wollina-uw@khdf.de.

Key words: advanced squamous cell carcinoma, cetuximab, volumetric modulated arc-therapy

Conflict of interest: the authors have no conflict of interest.

Received for publication: 20 October 2011.

Accepted for publication: 22 October 2011.

This work is licensed under a Creative Commons Attribution NonCommercial 3.0 License (CC BY-NC 3.0).

©Copyright U. Wollina et al., 2011

Licensee PAGEPress, Italy

Dermatology Reports 2011; 3:e57

doi:10.4081/dr.2011.e57

Case Report

A 77-year old male patient presented with a large tumor of the scalp that had grown over a period of more than 24 months. He suffered from arterial hypertension, hyperlipidemia, hyperuricemia, and liver cirrhosis.

On examination, we observed an ulcerated exophytic tumor (approx. 4 cm in diameter) with three macroscopically visible satellite metastases in the right temporo-occipital region (Figure 1). We performed delayed Mohs surgery for both the tumor and the metastases. The defect was covered by large transposition flaps leaving a central area that was closed with a full thickness skin graft. Healing was unremarkable and complete (Figure 2).

Histological examination of the species revealed a moderately differentiated SCC (T2, N0, M0; stage II, American Joint Committee on Cancer (AJCC)) with lymphangiosis carcinomatosa, and perineural infiltration and satellitosis (Figure 3). Because of the age of the patient and his co-morbidities, we decided against further surgery but initiated a closer follow up.

Eight weeks later, the patient presented with ulcerated satellitosis in the frontal and right fronto-temporal area of the scalp. Re-staging demonstrated a T2, N1, M0 profile (stage III, AJCC).

The situation was not controllable by surgery. Chemotherapy was limited by the patient's co-morbidities. Therefore, we decided to use targeted therapy with monoclonal anti-epidermal growth factor receptor (EGFR) antibody cetuximab (Erbix[®]; Bristol-Meyers Squibb) in combination with radiotherapy. After the loading dose of 400 mg/m², the patient

received 250 mg/m² once a week for six weeks. Pre-medication consisted of 100 mg prednisolone i.v., 4 mg dimetindene maleate i.v., 50 mg ranitidine i.v. and 8 mg ondansetron p.o. Cetuximab was well tolerated except for the loading dose when the patient developed fever chills. We gave him dimetinden maleate intravenously and lowered the infusion speed. There was a fast recovery within a couple of hours. From the second infusion onwards, no further adverse effects of this kind were observed. Within the first week of monoclonal antibody treatment, the patient developed rosacea-like pustules on facial and neck skin. The reaction was scored grade II according to the NCI-CTC scoring system.²⁸ These cutaneous lesions were treated with metronidazole gel and there was a marked improvement within two weeks.

The tumor response was visible within the first two weeks of treatment. Nodules became flat and no new nodules developed. The lymph node swelling disappeared. There was an almost complete clinical response at the end of cetuximab therapy.

After two weeks of monotherapy, radiotherapy was added. Irradiation was realized by volumetric modulated arc-therapy (VMAT). In this irradiation technique, the gantry of the accelerator moves 360° around the patient. Due to the use of a dynamic multileaf collimator, variable dose rates and variable gantry speeds, this technique allows the generation of a very complex dose distribution in one or two optimized arcs around the patient. Through continuously modulating the applied dose, high doses to the entire tumor volume can be delivered while at

the same time sparing normal healthy tissue. Another major advantage of VMAT is the dramatically shorter treatment time compared to all existing methods, including tomotherapy.

In the application of this technique, the exact and reproducible set-up of the patient during every treatment session is of crucial importance. We used a custom-formed 1 cm thick thermoplastic head-mask for immobilization and fixation. This mask was lined inside

with bolus material to shift the dose maximum in the superficial treatment area.

The physical treatment plan was designed according to a proposal of Skinner²⁹ consisting of 3 non-coplanar arcs. This technique provides homogeneous dose distribution and target coverage but still results in a relevant dose to brain (mean dose 28 Gy) and eyes.

We modified this approach in order to improve the protection of brain and eyes: both

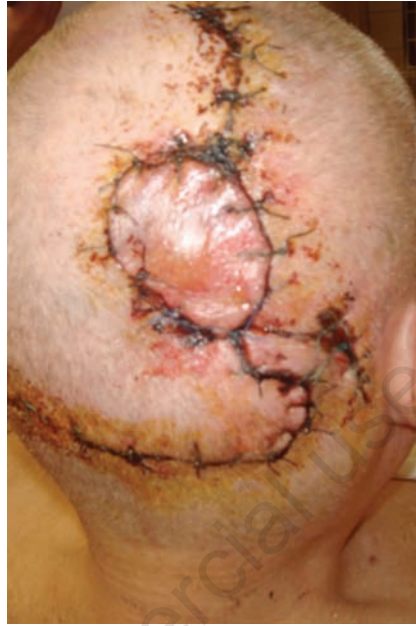

Figure 2. Clinical presentation nine days after after Mohs surgery.

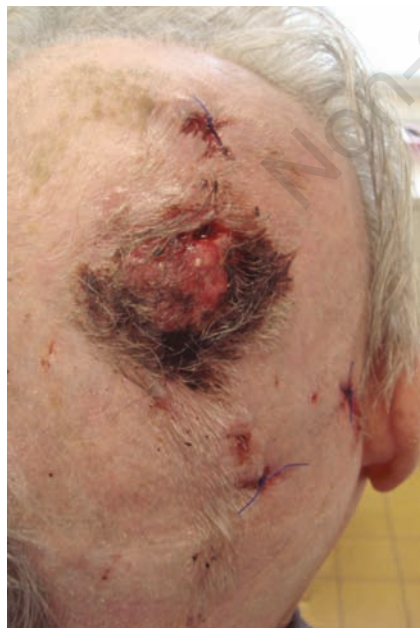


Figure 1. Initial presentation of cutaneous squamous cell carcinoma of the scalp with satellitosis.

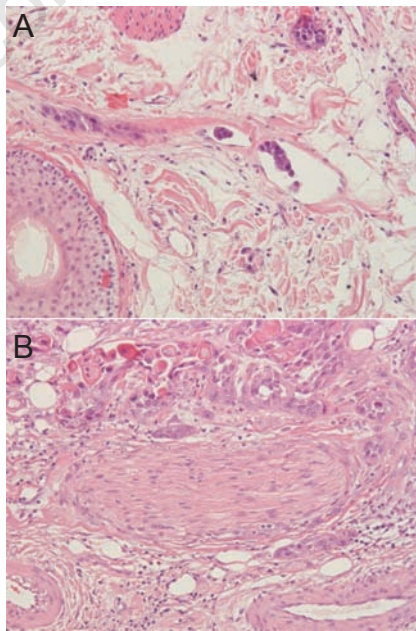


Figure 3. Histological evaluation demonstrates (A) lymphatic and (B) perineural invasion (hematoxylin-eosin, x20).

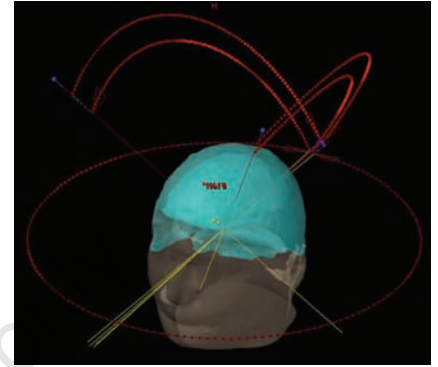


Figure 4. Improved treatment technique is based on 2 coplanar and 4 non-coplanar arcs.

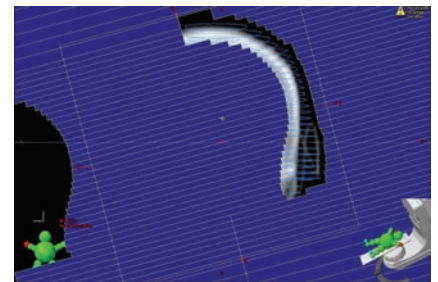


Figure 5. Image of one partial non-coplanar arc demonstrating the dose deposition mainly in a tangential direction to the target volume.

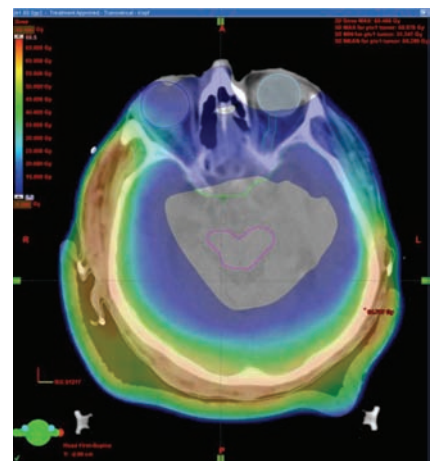


Figure 6. Image of one partial non-coplanar arc demonstrating the dose deposition mainly in a tangential direction to the target volume.

the non-coplanar arcs were divided into two partial arcs (Figure 4). In summary, the dose deposition in the target volume is built up mainly by tangential irradiation (Figure 5) and optimal sparing of all organs at risk is achieved (Table 1, Figure 6). To verify the correct application of this treatment plan, it was applied to

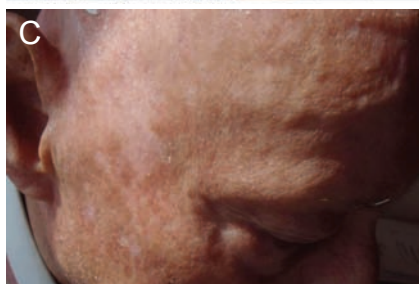
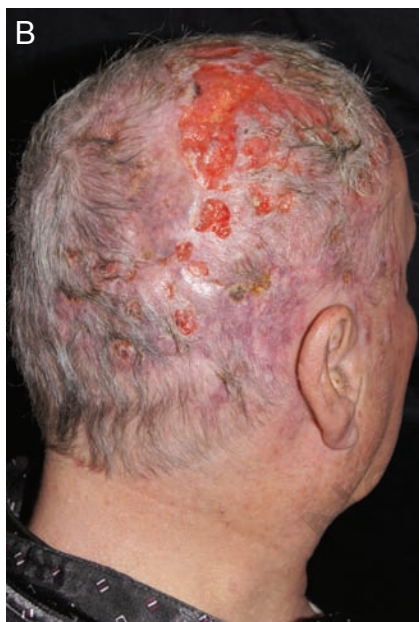
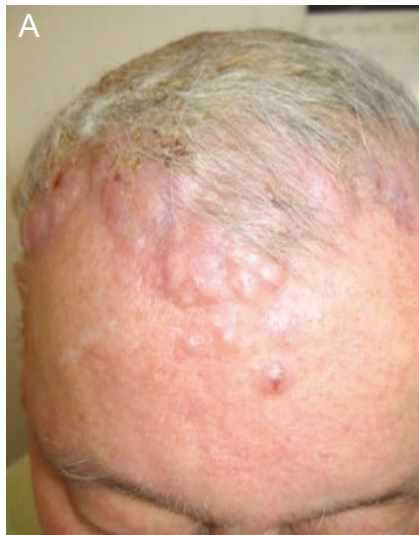Figure 7. Treatment course with cetuximab and radiotherapy. (A) Relapse with multiple ulcerated satellites eight weeks after Mohs surgery. (B) At the end of radiotherapy. Ulcers were tumor free. (C) After three months.

a 3-dimensional measuring phantom (ArcCheck, Sun Nuclear Corp., Melbourne/FL, USA) prior to the patient's first treatment session. This showed good agreement between calculated and measured dose distributions [γ (3%, 3 mm) = 95.4]. Additional checks were carried out to investigate influences of deviations in daily patient set-up or bolus attachment on the dose distribution, in target volume and organs at risk. All results demonstrated that a safe application of this treatment plan is guaranteed, taking account of the tolerance levels achievable in daily routine clinical practice. To minimize these tolerances, patient set-up was checked and corrected by orthogonal fluoroscopic images recorded daily by the on-board imager (OBI) used in our Varian accelerator.

Average daily beam time was 6 min (6

arcs, 767 monitor units). Total treatment time, including patient set-up and set-up correction, was less than 20 min. Radiotherapy was well tolerated and the patient achieved complete remission (Figure 7).

Discussion

Advanced cutaneous SCC has a risk of metastases and relapse. In a prospective analysis of 653 patients, tumor thickness more than 2mm and tumor size more than 6 mm are the major risk factors for these phenomena. Other features characterizing high-risk cutaneous SCC include poor differentiation, perineural or lympho-vascular infiltration, and bone invasion.^{5,30,31}

Table 1. Main values characterizing dose distribution in planning target volume and organs of risk.

PTV	Volume > 95 % dose	92%
Brain	maximum dose	17.2 Gy
Spinal cord	maximum dose	34.3 Gy
Optic nerves (left/right)	maximum dose	16.4/22.0 Gy
Chiasma	maximum dose	7.3 Gy
Eyes (left/right)	maximum dose	11.1/28.2 Gy
Eye lenses (left/right)	maximum dose	4.1/9.0 Gy

Table 2. Case reports of cutaneous Squamous cell carcinoma treated with cetuximab.

Patients	Tumor site	Treatment	Outcome	References
1. 92 yrs, male	Forehead	Cetuximab weekly for 3 months	CR for at least 10 months	Kim <i>et al.</i> 2011 ²³
2. 79 yrs, male	Back	3 cycles of cetuximab weekly for 4 weeks	CR for at least 26 months	Miller <i>et al.</i> 2010 ²⁴
3. 73 yrs, male	Scalp	Weekly cetuximab	CR	Baumann <i>et al.</i> 2007 ²⁵
4. 71 yrs, female	Nose	Weekly cetuximab	Almost cleared	
5. 67 yrs, male	Ear	7 weeks cetuximab and radiotherapy	CR, 3 months	Giacchero <i>et al.</i> 2011 ²⁷
6. 69 yrs, female	Nose	32 weeks cetuximab and radiotherapy	PR, > 18 months	
7. 72 yrs, male	Ear	7 weeks cetuximab and radiotherapy	CR, 5 months	
8. 79 yrs, male	Scalp	16 weeks cetuximab and radiotherapy	CR, >21 months	
9. 82 yrs, female	infra-orbital	46 weeks cetuximab	SD, 11 months	
9. 69 yrs, male	temple	11 weeks cetuximab	PD	
10. 57 yrs, male	sacrum	9 weeks cetuximab and radiotherapy	PR, 6 months	
11. 78 yrs, male	scalp	7 weeks cetuximab and radiotherapy	PR, not reported	
12. 24 yrs, female	arm	12 weeks cetuximab	PR; > 3 months	Arnold <i>et al.</i> 2009 ²⁶
12. 77 yrs, male	scalp	6 weeks cetuximab and radiotherapy	CR, > 3 months	Present

We report a successful treatment of advanced cutaneous SCC with regional lymphnode involvement of the scalp with the anti-EGFR drug cetuximab and radiation after primary surgery. There are limited data available in this indication for cutaneous SCC despite approval for HNSCC²³⁻²⁷ (Table 2). A single phase II trial performed in France has only been published as an abstract. Thirty-six patients with advanced cutaneous SCC were involved. Cetuximab therapy alone was able to control the disease in 69% of patients making this well tolerated treatment of interest for elderly patients with SCC.³²

HNSCC and cutaneous SCC over-express EGFR, a 170 kDa transmembrane protein, linked to tumor progression and autonomous tumor cell growth. EGFR signaling in the cell is mediated by three major pathways: RAS-MAP kinases, PI3K-AKT, and SCR-STAT. Response to cetuximab in these tumors has been associated to overexpression of signal transducers and activators of transcription (STAT) gene STAT5A and ephrin receptor gene EPHA2.³³ Cetuximab demonstrated *in vitro* antiproliferative activity, direct cytotoxicity, and the potentiation of chemo- or radiotherapy^{18,19} in HNSCC. *In vitro* studies using cell lines derived from cutaneous SCC further substantiated these results. Xenograft tumor models gave evidence for the anti-angiogenic, apoptotic and anti-proliferative activity of cetuximab.³⁴

A great advantage of cetuximab compared to traditional chemotherapy is the fact that there is no additional hepatotoxicity.³⁵ EGFR-inhibitors can induce skin reactions like papulopustular rash or periungual inflammation, compromised hair growth, skin dryness and itching. These types of adverse effects have been linked to better outcome in patients with colorectal cancer and targeted therapy against EGFR.³⁶

In a recent investigation, 49% of patients with HNSCC developed a grade III to IV radiation dermatitis with concurrent cetuximab.³⁷ A possible explanation is the reduction of a major anti-oxidant enzyme, i.e. glucose-6-phosphate dehydrogenase by cetuximab.³⁸ In the present case, however, severe radiation dermatitis was not observed. Other EGFR inhibitors have been developed, such as erlotinib and gefitinib, but there are limited reports of experience with these drugs in cutaneous SCC.^{8,33}

Radiotherapy was added with intention to cure. Given this, a total dose of at least 60 Gy in six weeks based on daily doses of 2.0 Gy is necessary when using percutaneous irradiation.²⁷ Traditionally these lesions were treated by two different methods:³⁹

by afterloaded Iridium-192 skin moulds. Unfortunately, this technique is very time-consuming in terms of preparation, planning, quality assurance and implementa-

tion. Additionally, it results in high doses to brain and optical structures, and the actually delivered dose may vary from the planned dose;

most commonly combined photon-electron plans are used. This is technically very complex due to necessary shiftings of match-lines between different fields during the treatment course, and results in less conformal plans with large dose gradients in the target volume.

Therefore, studies using the application of helical tomotherapy were initiated to overcome these problems.⁴⁰ In recent publications, volumetric modulated arc-therapy (VMAT) has also been demonstrated to be an alternative option; it is clinically acceptable and comparable to tomotherapy.⁴¹ It provides significantly more homogeneous dose distribution and reduces high-dose regions in the brain to a larger degree than all conventional methods. An additional advantage is the short treatment time.

In conclusion, the present case report and other reports from the literature (Table 2) suggest that the combination of monoclonal EGFR antibody and radiotherapy is effective in controlling advanced cutaneous SCC with or without metastases in analogy to HNSCC. The recent advances in radiotherapy offer an effective and well tolerated treatment option. In summary, VMAT is an excellent method for total scalp irradiation comparable to helical tomotherapy. The treatment achieved a complete stable remission without major toxicities.

References

- Schmitt J, Seidler A, Diepgen TL, Bauer A. Occupational ultraviolet light exposure increases the risk for the development of cutaneous squamous cell carcinoma: a systematic review and meta-analysis. *Br J Dermatol* 2011;164:291-307.
- Stang A, Ziegler S, Büchner U, et al. Malignant melanoma and nonmelanoma skin cancers in Northrhine-Westphalia, Germany: a patient- vs. diagnosis-based incidence approach. *Int J Dermatol* 2007; 46:564-570.
- Brewster DH, Bhatti LH, Inglis JH, et al. Recent trends in incidence of non-melanoma skin cancer in the East of Scotland, 1992-2003. *Br J Dermatol* 2007; 156:1295-300.
- Revenga Arranz F, Paricio Rubio JF, Mar Vázquez Salvado M, del Villar Sordo V. Descriptive epidemiology of basal cell carcinoma and cutaneous squamous cell carcinoma in Soria (north-east Spain) 1998-2000: a hospital-based survey. *J Eur Acad Dermatol Venereol* 2004;18:137-41.
- Farasat S, Yu SS, Neel VA, et al. A new American Joint Committee on Cancer staging system for cutaneous squamous cell carcinoma: Creation and rationale for inclusion of tumor (T) characteristics. *J Am Acad Dermatol* 2011;64:1051-9.
- Ho T, Byrne PJ. Evaluation and initial management of the patient with facial skin cancer. *Facial Plast Surg Clin North Am* 2009;17:301-7.
- Jambusaria-Pahlajani A, Miller CJ, Quon H, et al. Surgical monotherapy versus surgery plus adjuvant radiotherapy in high-risk cutaneous squamous cell carcinoma: a systematic review of outcomes. *Dermatol Surg* 2009;35:574-85.
- Cranmer LD, Engelhardt C, Morgan SS. Treatment of unresectable and metastatic cutaneous squamous cell carcinoma. *Oncologist* 2010;15:1320-8.
- Wollina U, Hansel G, Koch A, Köstler E. Oral capecitabine plus subcutaneous interferon alpha in advanced squamous cell carcinoma of the skin. *J Cancer Res Clin Oncol* 2005;131:300-4.
- Jirakulaporn T, Endrizzi B, Lindgren B, et al. Capecitabine for skin cancer prevention in solid organ-transplanted recipients. *Clin Transplant* 2010;doi:10.1111/j.1399-0012.2010.01348.x.
- Wollina U, Prochnau D, Hoffmann A, et al. Vasoactive intestinal peptide and epidermal growth factor: co-mitogens or inhibitors of keratinocyte proliferation *in vitro*? *Int J Mol Med* 1998;2:725-30.
- Maubec E, Duvillard P, Velasco V, et al. Immunohistochemical analysis of EGFR and HER-2 in patients with metastatic squamous cell carcinoma of the skin. *Anticancer Res* 2005;25:1205-10.
- Schlauder SM, Calder KB, Moody P, Morgan MP. HER2 and EGFR expression in cutaneous spindle squamous cell carcinoma. *Am J Dermatopathol* 2007;29:559-63.
- Toll A, Salgado R, Yébenes M, et al. Epidermal growth factor receptor gene numerical aberrations are frequent in actinic keratoses and invasive cutaneous squamous cell carcinoma. *Exp Dermatol* 2010;19:151-3.
- Amini S, Viera MH, Valins W, Berman B. Nonsurgical innovations in the treatment of nonmelanoma skin cancer. *J Clin Aesthetic Dermatol* 2010;3:20-34.
- Goldstein NI, Prewett M, Zuklys K, et al. Biological efficacy of a chimeric antibody to the epidermal growth factor receptor in a human tumor xenograft model. *Clin Cancer Res* 1995;1:1311-8.
- Humbert Y. Cetuximab: an IgG1 monoclonal antibody for the treatment of epidermal growth factor receptor-expressing tumours. *Expert Opin Pharmacother* 2004;

- 5:1621-33.
18. Specenier P, Vermorken JB. Cetuximab in the treatment of squamous cell carcinoma of the head and neck. *Expert Rev Anticancer Ther* 2011;11:511-4.
 19. Harrington KJ, Kazi R, Bhide SA, et al. Novel therapeutic approaches to squamous cell carcinoma of the head and neck using biologically targeted agents. *Indian J Cancer* 2010;47:248-59.
 20. Tejani MA, Cohen RB, Mehra R. The contribution of cetuximab in the treatment of recurrent and/or metastatic head and neck cancer. *Biologics Targets Therapy* 2010;4:173-85.
 21. Dequanter D, Shala M, Paulus P, Lothaire P. Cetuximab in the treatment of head and neck cancer: preliminary results outside clinical trials. *Cancer Management Res* 2010;2:165-8.
 22. Ho C. Cetuximab in locally advanced head-and-neck cancer: defining the population. *Curr Oncol* 2010;17:48-51.
 23. Kim S, Eleff M, Nicolaou N. Cetuximab as primary treatment for cutaneous squamous cell carcinoma to the neck. *Head Neck* 2011;33:286-8.
 24. Miller K, Sherman W, Ratner D. Complete clinical response to cetuximab in a patient with metastatic cutaneous squamous cell carcinoma. *Dermatol Surg* 2010;36:2069-74.
 25. Bauman JE, Eaton KD, Martins RG. Treatment of recurrent squamous cell carcinoma of the skin with cetuximab. *Arch Dermatol* 2007;143:889-92.
 26. Arnold AW, Bruckner-Tuderman I, Zuger C, Itin PH. Cetuximab therapy of metastasizing cutaneous squamous cell carcinoma in a patients with severe recessive dystrophic epidermolysis bullosa. *Dermatology* 2009;219:80-3.
 27. Giacchero D, Barrière J, Benezery K, et al. Efficacy of cetuximab for unresectable or advanced cutaneous squamous cell carcinoma - a report of eight cases. *Clin Oncol (R Coll Radiol)* 2011; 23: 716-8.
 28. National Cancer Institute Common Terminology Criteria for Adverse Events Version 4.0. Available at: http://evs.nci.nih.gov/ftp1/CTCAE/CTCAE_4.0.2_2009-09-15_QuickReference_8.5x11.pdf pages 73-74.
 29. Skinner M. 2010. Available at: <http://my.varian.com/files/Varian%20AAPM%20Users%20Meeting%202010%20-%20Skinner.pdf>
 30. Brantsch KD, Meisner C, Schönfisch B, et al. Analysis of risk factors determining prognosis of cutaneous squamous-cell carcinoma: a prospective study. *Lancet Oncol* 2008;9:713-20.
 31. Jennings L, Schmults CD. Management of high-risk cutaneous squamous cell carcinoma. *J Clin Aesthet Dermatol* 2010;3:39-48.
 32. Maubec E, Petrow P, Duvillard P, et al. Cetuximab as first-line monotherapy in patients with unresectable squamous cell carcinoma: final results of a phase II multicenter study [abstract]. *J Clin Oncol* 2010;28:8510.
 33. Kotoula V, Lambaki S, Televantou D, et al. STAT-related profiles are associated with patient response to targeted treatments in locally advanced SCCHN. *Translation Oncol* 2011;4:47-58.
 34. Galer CE, Corey CL, Wang Z, et al. Dual inhibition of epidermal growth factor receptor and insulin-like growth factor receptor I: reduction of angiogenesis and tumor growth in cutaneous squamous cell carcinoma. *Head Neck* 2011;33:189-98.
 35. Pessaux P, Panaro F, Casnedi S, et al. Targeted molecular therapies (Cetuximab and bevacicumab) do not induce additional hepatotoxicity: preliminary results of a case-control study. *Eur J Surg Oncol* 2010;36:575-82.
 36. Lacouture ME, Melosky BL. Cutaneous reactions to anticancer agents targeting the epidermal growth factor receptor: a dermatology-oncology perspective. *Skin Therapy Lett* 2007;12:1-5.
 37. Giro C, Berger B, Bölke E, et al. High rate of severe radiation dermatitis during radiation therapy with concurrent cetuximab in head and neck cancer: results of a survey in EORTC institutes. *Radiother Oncol* 2009;90:166-71.
 38. Skvortsova I. Oxidative damage and cutaneous reactions during radiotherapy in combination with cetuximab. *Radiother Oncol* 2009;90:281-2.
 39. Wojcicka JB, Lasher DE, McAfee SS, Fortier GA. Dosimetric comparison of three different techniques in extensive scalp lesion irradiation. *Radiother Oncol* 2009;91:255-60.
 40. Mallik S, Master Z, Gupta T, et al. Brain sparing whole skull/scalp radiotherapy: unique application of helical tomotherapy [abstract]. *Int J Radiation Oncol Biol Physics* 2009;75:729.
 41. Agazaryan N, Tenn S, Chow P, et al. Total scalp irradiation: comparison between volumetric modulated arc therapy, helical tomotherapy and conventional electron and photon field combination. *Med Physics* 2010;37:3319.