

Bullous mycosis fungoides associated with an extensive ulcer and a severe leukemoid reaction

Shuei Sato,¹ Osamu Okamoto,¹
Michifumi Kawamoto,¹
Masaki Oishi,¹ Naomi Yada,²
Kazuhiro Kohno,³ Shigeo Yokoyama,²
Sakuhei Fujiwara¹

¹Department of Dermatology, ²Pathology and ³Hematological Unit of Internal Medicine, Faculty of Medicine, Oita University, 1-1 Idaigaoka, Hasama-machi, Yufu-shi, Oita, Japan

Abstract

This report presents a case of bullous mycosis fungoides associated with an extensive ulcer and a severe leukemoid reaction. The rash began as indurated erythema which was always followed by ulceration. The rashes initially responded to radiation therapy, but multiple recurrences appeared. Several bullae appeared on the trunk during the course of the illness, without any evidence of paraneoplastic pemphigus. Finally, the ulcer covered a large part of the trunk, and the patient died of sepsis with an extreme leukocyte count of 118,000/ μ L. A bone marrow analysis revealed a leukemoid reaction and an autopsy revealed pseudomembranous colitis.

Introduction

Bullous mycosis fungoides (bullous MF) is a rare clinical condition and the cases showing an extensive ulcer are quite problematic. It is supposed that MF patients could become septic following the formation of ulcers, and their prognosis would be poor.

Reactive leukocytosis with a leukocyte count over about 25,000 is called a leukemoid reaction. Various causes of leukemoid reactions, such as infections, malignant tumors, etc., are known,^{1,2} and pseudomembranous colitis is a frequent cause of such infections.^{1,3} Notably, an extensive leukemoid reaction which takes the leukocyte count over 50,000/ μ L has a poor prognosis,³ and the development of a leukocyte count of over 100,000/ μ L is very rare.

This report presents a case of bullous MF demonstrating a strong tendency to form skin ulcers. Another notable abnormality of this case was extreme leukocytosis up to 118,000/ μ L before death. The leukocytosis was

proven to be a leukemoid reaction, and pseudomembranous colitis was revealed by an autopsy. In this case, the ulcer formation due to bullous MF, pseudomembranous colitis, and the leukemoid reaction were all assumed to be related. Therefore, this report presents a thorough description of the case, together with a review of two rare clinical conditions of bullous MF and of a severe leukemoid reaction.

Case Report

A 65-year-old male noted enlarging reddish rashes on his abdomen and left arm in October of 2005. His previous history of rashes was unclear. He was examined at a clinic and a biopsy indicated a diagnosis of cutaneous lymphoma. He was therefore transferred to our hospital and was admitted in January of 2006. An examination revealed freshly-red plaques distributed mainly in non-exposed areas (Figure 1A and 1B), and a tumor on the left upper arm (Figure 1A). Many of the rashes were associated with ulcers (Figure 1A and 1B).

A blood analysis demonstrated 1% atypical lymphocytes in 9,800/ μ L leukocytes, and the soluble interleukin-2 receptor (sIL-2R) level was 21,900 U/mL (normal value: 145-519), but human T cell lymphoma/leukemia virus-1 antibody was negative. There was a monoclonal gene rearrangement in the $\text{C}\beta$ 1 T-cell receptors from lymphocytes from the skin lesion. A biopsy specimen showed Pautrier's microabscesses in the epidermis as well as a prominent epidermotropism (Figure 1C). Dense and patchy infiltrations composed of highly atypical lymphocytes were distributed around dermal blood vessels and in the fat layer (Figure 1C). Over 80 % of the abnormal lymphocytes was CD3(-)/CD4(+)/CD8(+)/CD20(-)/CD30(-)/CD56(-), about 10% of the cells was CD3(-)/CD4(+)/CD8(+)/CD20(-)/CD30(+)/CD56(-), and a minor fraction of the cells were CD3(+). From the clinical symptoms and the laboratory findings, the patient was diagnosed to have MF.⁴ The clinical course of this patient is summarized in Figure 2. Systemic CHOP chemotherapy was initiated; the sIL-2R level significantly decreased, however, no evident change was seen in the skin eruption. Radiation therapy was added at a dose of 30 Gy/lesion beginning in April of 2006. The cutaneous plaques initially ulcerated, but healed 5 months later. No active skin lesions were seen between August of 2006 and April of 2007 (Figure 2), thus an induction of partial remission was successful. In April 2007, a tumor recurred on the left temporal area, followed by the left side of the lip, and the right upper eyelid, in July and September, respectively (Figure 2). These lesions were associated with ulcers

Correspondence: Osamu Okamoto, MD, Department of Dermatology, Faculty of Medicine, Oita University, 1-1 Idaigaoka, Hasama-machi, Yufu-shi, Oita, 879-5593, Japan.
Tel: +81.975.86.5882 - Fax: +81.975.86.5889.
E-mail: ookamoto@med.oita-u.ac.jp

Key words: bullous mycosis fungoides, leukemoid reaction, pseudomembranous colitis.

Conflict of interest: none declared (the authors report no conflict of interest).

Received for publication: 17 March 2011.
Revision received: 16 November 2011.
Accepted for publication: 18 November 2011.

This work is licensed under a Creative Commons Attribution NonCommercial 3.0 License (CC BY-NC 3.0).

©Copyright S. Sato et al., 2011
Licensee PAGEPress, Italy
Dermatology Reports 2011; 3:e54
doi:10.4081/dr.2011.e54

on the surface, and they responded to the radiation therapy in the same fashion as before. In November 2007, several bullae developed on the trunk over the course of several days (Figure 1D). The bullae were formed subepidermally and the covering epidermis contained prominent Pautrier's microabscesses, and appeared degenerative (Figure 1E). Paraneoplastic pemphigus was ruled out by direct immunofluorescence. The patient was, therefore, diagnosed to have bullous MF. Multiple erythema and ulcers rapidly recurred on the trunk by the end of 2007, and these lesions covered a wide area of the trunk by early January of 2008 (Figure 1F). The patient subsequently demonstrated severe hypoproteinemia because of the large amount of exudate from the ulcers, and sepsis, and therefore, the patient was treated with substantial doses of antibiotics. The sIL-2R value was elevated again as the eruptions enlarged (33,200 U/mL; Figure 2). Marked leukocytosis developed on February 11, 2008, and the patient died the next day. The patient's leukocyte count at the time of his death was 118,000/ μ L (stab cell 30%, segment cell 10%, myelocyte 37%, metamyelocyte 8%, lymphocyte 7%, and monocyte 4%), and the blood granulocyte colony stimulating factor (G-CSF) value was 1300 pg/mL (normal value: 5.78-27.5).

An autopsy revealed that the colon was covered with discrete whitish-yellow plaques (Figure 3A). The crypts were disrupted and contained fibrinopurulent necrotic debris in a wedge pattern (Figure 3B). These findings indicated a diagnosis of pseudomembranous colitis, probably due to the administration of antibiotics to treat the sepsis. A CD45-blast gating analysis of the bone marrow indicated

that the major fraction of the cells in the bone marrow to be mature granulocytes, and no blastic change was seen (Figure 3C). Therefore the leukocytosis was determined to be due to a leukemoid reaction. When the pathological specimen was stained with anti-G-CSF antibody, the tumor cells showed negative staining.

Discussion

Because of the wide area of the rashes and a formation of large tumors, we preferred the chemotherapies rather than local therapies such as radiation. However, the effect was marginal, and the fact happened to support a therapeutic guideline of EORTC.⁵ In our case, most of the tumor cells were doubly-positive for CD4 and 8. From other histological findings, this case is diagnosed to have MF,⁶ however, we could rarely find such cases in the literature.⁷ Although the meaning of a double positivity for CD4 and 8 in MF remains to be determined, it is worth recording this finding.

Bullous MF is a rare clinical condition. A review of the literature described 9 cases over 30 years,⁸ and this variant is rarely reported even recently.⁹ The possible mechanisms of bulla formation in MF include epidermal degeneration due to epidermotropism;^{10,11} extensive dermal edema due to lymphoma cell infiltration;¹² and extensive spongiosis.^{8,13} The possibility of epidermotropism for the formation of bulla is consistent with the pathology of the current case. The prognosis of bullous MF is generally poor; with about half of the affected patients dying within 1 year after the appearance of the bulla.⁸ Therefore, the formation of bulla during the course of MF indicates a poor prognosis, and the extensive ulceration seen in the current case may reflect a step toward his ultimate death.

Many causes of leukemoid reaction are known, including infections, malignant tumors, etc.¹² In the current case, the leukemoid reaction was likely caused by the lymphoma or pseudomembranous colitis. Regarding cutaneous lymphoma, the only type which is known to cause a leukemoid reaction to date is anaplastic large cell lymphoma, and the tumor cells usually produce G-CSF.¹⁴ Our patient had MF, and the tumor was negative for G-CSF, therefore, the possibility of MF as the cause of the leukemoid reaction is unlikely. In contrast, pseudomembranous colitis is a more common cause of the reaction; a large clinical study showed that 20 out of 334 cases were associated with a leukemoid reaction.³ Taken together, the leukemoid reaction in the current case was likely caused by the pseudomembranous colitis. Ten of those 20 cases in the clinical study were fatal, and all of the cases had a

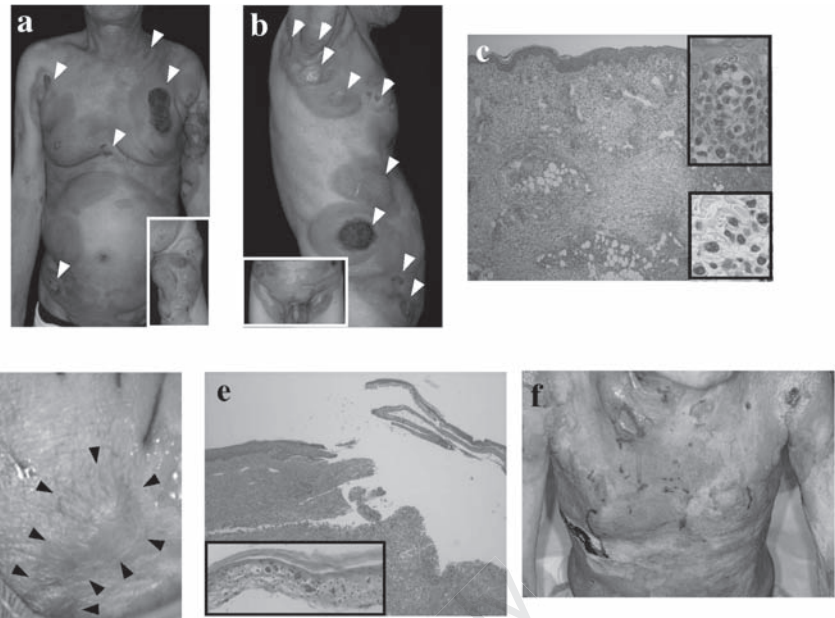


Figure 1. Initial appearance of the patient: a) multiple indurated plaques are present on the trunk and extremities. Inlet: An ulcerated tumor on the left upper arm; b) a view from the right side. Inlet: Rashes around the waist. In (a) and (b), ulcers are indicated by arrowheads. Note that the distribution of most of the rashes was in non-exposed areas, thus representing an underwear distribution; c) histological appearance of a rash on the trunk (original magnification X40). Upper inlet: Pautrier's microabscess in the epidermis (original magnification X400). Lower inlet: Close-up view of the infiltrate (original magnification X400); d) bulla on the trunk; e) histological appearance of the bulla (original magnification X40). Inlet: Roof of the bulla (original magnification X400). Many Pautrier's microabscesses can be seen; f) appearance 3 weeks before death. Most of the trunk is covered by ulcers with serous exudate.

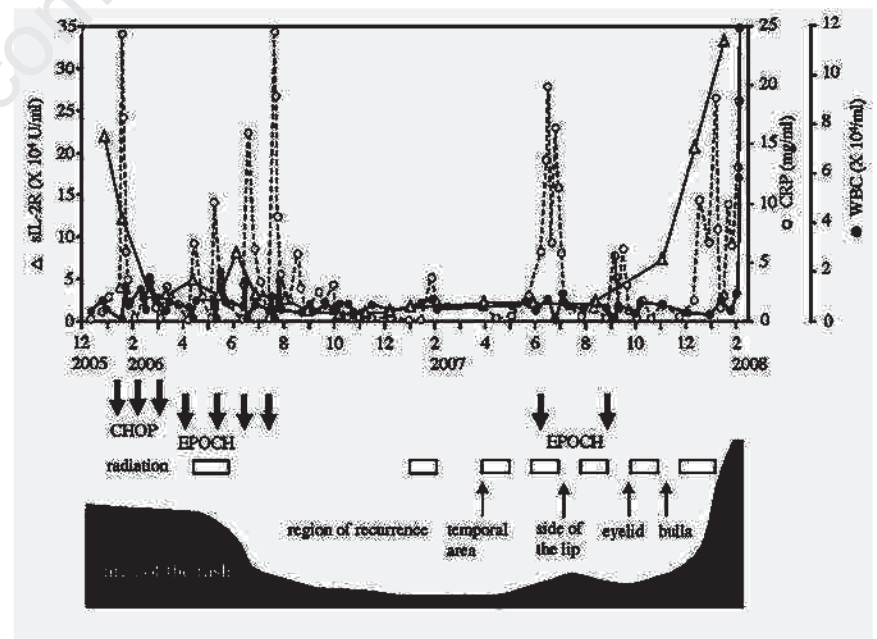


Figure 2. Clinical course of the case. Top panel: Transition of sIL-2R (Δ), CRP levels (\circ) and leukocyte counts (\bullet). Systemic chemotherapies are indicated by the filled arrows; the duration of the radiotherapy is indicated by boxes; recurrent areas are indicated by arrows. The transition of the area of cutaneous ulcers is indicated at the bottom.

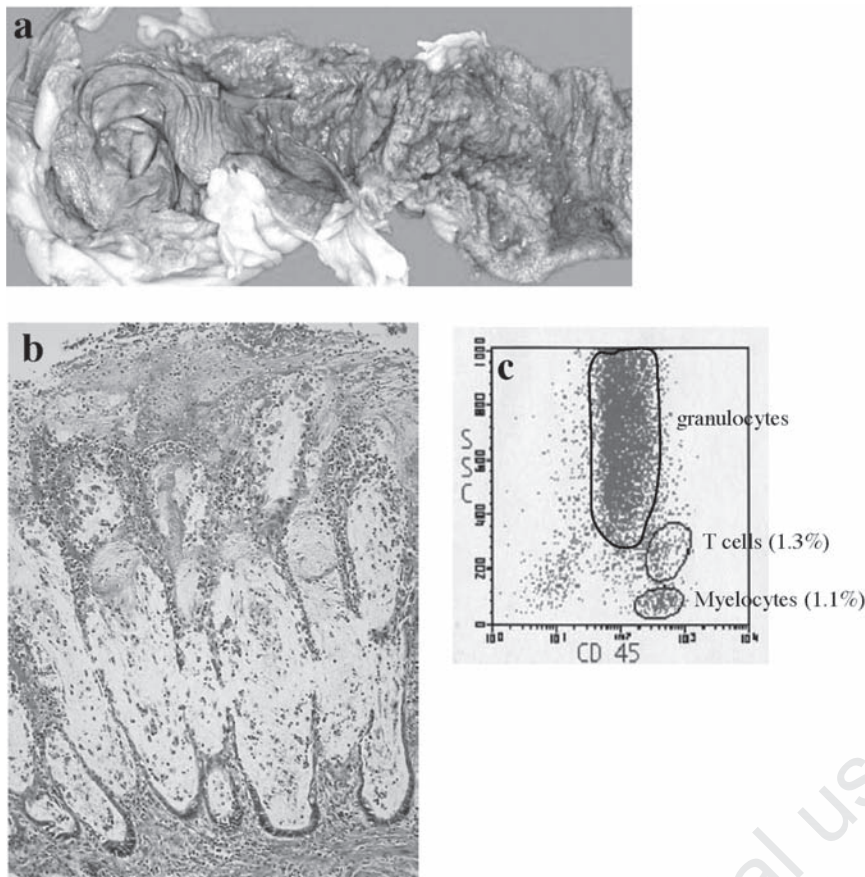


Figure 3. Autopsy findings: a) descending colon, gross view; b) microscopic view of the plaque on the colon (original magnification X100); c) CD 45-blast gating analysis of the bone marrow cells. Representative fractions of the cells are indicated by circles.

leukocyte count over 50,000/ μ L.³ These findings indicate that a higher leukocyte count in the leukemoid reaction is a predictive factor for a poor prognosis. In particular, the severe leukemoid reaction observed in the current case is exceptional: only 2 other cases have been reported to have a leukocyte count of >100,000/ μ L.^{3,15} Pseudomembranous colitis should therefore be considered as an underlying disease when a patient develops a leukemoid reaction.

We reported a case of bullous MF which showed a strong tendency to form ulcers. The recurrent ulcer induced sepsis, and administration of antibiotics lead to pseudomembranous colitis. Finally a severe leukemoid reaction occurred because of the colitis, demonstrating a rare extremely high leukocyte count before death. Although a systemic chemotherapy had a marginal effect, the rashes briefly responded to radiation therapy, enabling a partial remission for 8 months. Considering from the clinical course of the patient, ulcer formation in malignant lymphoma may require certain specific treatment. By accumulating sim-

ilar cases, a therapeutic protocol for treating ulcer-forming malignant lymphoma can be developed.

References

1. Sakka V, Tsioudras S, Giamarellos-Bourboulis EJ, Giamarellou H. An update on the etiology and diagnostic evaluation of a leukemoid reaction. *Eur J Intern Med* 2006;17:394-8.
2. Granger JM, Kontoyiannis DP. Etiology and outcome of extreme leukocytosis in 758 nonhematologic cancer patients: a retrospective, single-institution study. *Cancer* 2009;115:3919-23.
3. Marinella MA, Burdette SD, Bedimo R, et al. Leukemoid reactions complicating colitis due to *Clostridium difficile*. *South Med J* 2004;97:959-63.
4. Ralfkiaer E, Cerroni L, Sander CA, et al. Mycosis fungoides. In: Swerdlow SH, Campo E, Harris NL, et al., editors. WHO

Classification of Tumours of Haematopoietic and Lymphoid Tissues, Lyon: IARC Press, 2008: pp 296–298.

5. Jones GW, Kacinski BM, Wilson LD, et al. Total skin electron radiation in the management of mycosis fungoides: Consensus of the European Organization for Research and Treatment of Cancer (EORTC) Cutaneous Lymphoma Project Group. *J Am Acad Dermatol* 2002;47:364-70.
6. Pimpinelli N, Olsen EA, Santucci M, et al. Defining early mycosis fungoides. *J Am Acad Dermatol* 2005;53:1053-63.
7. Munn SE, McGregor JM, Jones A, et al. Clinical and pathological heterogeneity in cutaneous gamma-delta T-cell lymphoma: a report of three cases and a review of the literature. *Br J Dermatol* 1996;135:976-81.
8. Bowman PH, Hogan DJ, Sanusi ID. Mycosis fungoides bullosa: Report of a case and review of the literature. *J Am Acad Dermatol* 2001;45:934-9.
9. Bernardini ML, Brandozzi G, Campanati A, et al. Bullous-vesicular variant of mycosis fungoides presenting as erythema annulare centrifugum: a case report. *J Eur Acad Dermatol Venereol* 2009;23:839-40.
10. Kamran B, Fatemeh M, Ahmadrza R, et al. Bullous mycosis fungoides: A case report. *Dermatol on line J* 2008;14:11-6.
11. Kartsonis J, Brettschneider F, Weissmann A, et al. Mycosis fungoides bullosa. *Am J Dermatopathol* 1990;12:76-80.
12. Okano M, Nakajima C, Uehara H, et al. Bullous lymphoma of the skin. *Br J Dermatol* 1994;131:709-12.
13. McBride SR, Dahl MG, Slater DN, et al. Vesicular mycosis fungoides. *Br J Dermatol* 1998;138:141-4.
14. El-Osta HE, Salyers WJ Jr, Palko W, et al. Anaplastic large-cell lymphoma with leukemoid reaction. *J Clin Oncol* 2008;26:4356-8.
15. De Toledo FG, Symes SN. Leukemoid reaction due to *Clostridium difficile* infection in acquired immunodeficiency syndrome: two case reports and a review of the literature. *South Med J* 2004;97:388-92.