



## Dermatology Reports

<https://www.pagepress.org/journals/index.php/dr/index>

eISSN 2036-7406



**Publisher's Disclaimer.** E-publishing ahead of print is increasingly important for the rapid dissemination of science. **Dermatology Reports** is, therefore, E-publishing PDF files of an early version of manuscripts that undergone a regular peer review and have been accepted for publication, but have not been through the copyediting, typesetting, pagination and proof-reading processes, which may lead to differences between this version and the final one. The final version of the manuscript will then appear on a regular issue of the journal. E-publishing of this PDF file has been approved by the authors.

*Please cite this article as: Vezzoni GM, Ricci C. "Mosaic graft" technique and surgical dermal glue in Mohs micrographic surgery and general dermatologic surgery. Dermatol Rep 2024 [Epub Ahead of Print] doi: 10.4081/dr.2024.9966*

 © the Author(s), 2024  
Licensee [PAGEPress](https://www.pagepress.org/), Italy

Submitted: 14/02/2024 – Accepted 15/03/2024

Note: The publisher is not responsible for the content or functionality of any supporting information supplied by the authors. Any queries should be directed to the corresponding author for the article.

All claims expressed in this article are solely those of the authors and do not necessarily represent those of their affiliated organizations, or those of the publisher, the editors and the reviewers. Any product that may be evaluated in this article or claim that may be made by its manufacturer is not guaranteed or endorsed by the publisher.

## **“Mosaic graft” technique and surgical dermal glue in Mohs micrographic surgery and general dermatologic surgery**

Gian Marco Vezzoni,<sup>1,2</sup> Cristina Ricci<sup>1</sup>

<sup>1</sup>Vdermastudio, Viareggio; <sup>2</sup>President of the Italian Society of Dermatologic Surgery, Italy

**Correspondence:** Gian Marco Vezzoni, Vdermastudio, 7, Vetraia Street, 55049 Viareggio, Italy.

Tel.: +39.0584361360.

E-mail: gianmarcovezzoni@yahoo.it

**Key words:** graft; full thickness skin graft; surgical glue; Mohs micrographic surgery; wound.

**Contributions:** GMV, study designer, main surgeon, paper writer; CR, surgical assistant, materials organizer, bibliography researcher. All the authors approved the final version to be published.

**Conflict of interest:** Gian Marco Vezzoni is GEM srl (glue producer) consultant. Cristina Ricci declares no potential conflict of interest.

**Funding:** the glue producer (GEM) supplied the material to do the study without paying the authors nor involving them in any commercial association.

**Ethical approval and consent to participate:** no ethical approval needed.

**Availability of data and material:** all data and materials are available.

**Informed consent:** informed consent was collected from the patients.

**Conference presentation:** part of this paper has been presented at the 41<sup>th</sup> ISDS meeting in Thessaloniky, Greece, September 2022.

## **Abstract**

After Mohs Micrographic Surgery dermsurgeons utilise local flaps, full or partial thickness grafts, with good or acceptable cosmetic results. When we are dealing with older and problematic patients, blood thinner users, and non-collaborative people with large facial neoplasms, using flaps may be very difficult and grafts become the best choice. Our aim was to assess a technique to graft very easily, quickly and safely, full thickness skin grafts in facial wounds and have good cosmetic results in those older and problematic people. Ten elderly patients who underwent Mohs Surgery or other surgical procedures have been grafted with this technique that we called “Mosaic graft”, made possible using a dermal glue in a new way. In some cases, for bigger defects, we also assessed the “Stripes” variant of this technique. Graft survival was almost always complete in all cases and after 6 months the cosmetic outcomes were good. This “Mosaic graft” technique and its “Stripes” variant showed good reliability, fast execution, easy harvesting with tissue saving, good cosmetic outcomes, making this technique a very good choice for older and problematic patients.

## **Introduction**

The continuous increase of our populations’ average age, as well as the extensive exposure to the sun for both recreational and work-related reasons, has resulted in a continuous expansion in the number of skin malignancies of epithelial origin.

Of these, many are treated with Mohs Micrographic Surgery (MMS), a technique that provides the best results in terms of neoplasm eradication and minimization of uninvolved skin removal.

Nevertheless, in many cases, the tissue removal necessary to eradicate the neoplasm is extensive and requires complex repair techniques.

In elderly patients with comorbidities, multiple therapies and minor, but not non-existent, aesthetic needs, the autologous graft technique is often used, which speeds up operating times and minimizes the surgical trauma.

This too, however, often takes a long time and is poorly tolerated by the patient. Moreover, large harvest areas are a source of discomfort, healing difficulties and poor aesthetic outcome.

The availability of a dermal glue opens the door to a new way of grafting which allows the overcoming of these problems.

In the literature we founded several papers describing the use of a dermal glue to fix partial thickness skin grafts: this is the first study using only a dermal glue to fix full thickness skin grafts, to our knowledge. (1,2,3,4,5)

The aim is to assess a full-thickness skin grafting technique that is reliable and faster than the traditional technique and that can be used with particular success in the case of large tissue removal.

In addition, the goal is to reduce the amount of the harvested skin, facilitate the closure of the donor area, and achieve good aesthetic results in elderly patients and/or in patients with poor surgical compliance.

## **Materials and Methods**

Here we present a novel technique for full-thickness autologous skin grafts in 10 elderly patients with comorbidities who underwent Mohs surgery for the removal of cutaneous neoplasms of the face, mostly of the nasal pyramid. Principles of the 1975 Declaration of Helsinki were followed and an informed consent was obtained from every patient.

After the removal of the neoplasm using MMS, patients underwent a full-thickness graft harvested from a skin area with similar features to the area to be grafted, usually in the cervical or periclavicular area.

Commercially available cyanoacrylate surgical dermal glue, authorised for intracorporeal and dermal use, was used to fix the grafts.

Cyanoacrylate has been used as a surgical adhesive since the 1960s. This glue is composed of N-butyl-2-cyanoacrylate (NBCA) and Methacryloxysulfolane (MS) monomer. The MS allows to have a lower temperature of polymerization than other monomeric cyanoacrylate derived tissue glues. The addition of MS results in lower toxicity and fewer inflammatory reactions. It has been used and authorised for many surgical procedures, including skin closure of abdominal wounds, suture reinforcement, arteriovenous embolization, endoscopic treatment of bleeding gastro duodenal ulcers and varices, and others.

After grafting, patients were then treated with a compressive pad and an adhesive plaster, without any tie-over bolster.

Images were taken before surgery and the functional and aesthetic results were evaluated postoperatively and again 6 months later.

Surgical technique: after removal, either by Mohs Micrographic Surgery or other surgical technique, the surgical breach is evaluated in terms of area, expressed in squared centimetres. Fig. 1a

The donor site is chosen according to the traditional criteria of similarity to the area to be repaired in terms of thickness, colour and texture.

A stripe of full-thickness skin 1.2 centimetres wide, and as long in centimetres as necessary to reach the extent of the surgical wound area, is taken. We add at least one centimetre of length and do not take into account the stripe's apical areas, which are narrower in width. Fig.1b and 1c

The fat is removed from the stripe as usual and the skin is placed on a gauze pad soaked with saline solution. The stripe is cut into squares or rectangles. The ends form two triangles. Fig.1d

A lower limit for the size of the mosaic tessera of approximately 0.5 x 0.5 cm must be considered in order to allow nutrients to penetrate into the skin. Indeed, we must keep in mind that exchanges are reduced in the central area by the presence of the glue. However, smaller triangles can be used to fill in residual spaces at the edges of the breach by gluing the side of the tessera instead of the bottom.

After careful and gentle haemostasis of the implant area, possibly with compression, saline compresses and light use of bipolar electrocautery, the breach is placed on a horizontal plane.

In order to reduce the bleeding, using anaesthetics with epinephrine is mandatory. In our technique we used lidocaine with epinephrine 1:400,000, which, after at least 10 minutes of waiting, allows optimal visibility of significative bleeding and the necessary delay of complete circulation recovery after the grafting. A 1:400,000 solution is suitable in nearly all patients.

Using a 26 gauges or thinner cannula inserted on the disposable glue vial as a glue dispenser, a few test drops are gently squeezed onto a surgical sheet.

Once we have obtained drops with a maximum diameter of 1 mm. (Fig. 2a) maintaining the vial vertical and applying slight pressure to prevent air from entering it again, we place a drop of glue at the bottom of the breach, in the desired position. Fig. 2b

We immediately place a piece of skin, centring it on the drop and holding it down very lightly for 30 seconds to allow the glue to polymerize. Fig. 2c

As if composing a mosaic, we continue to place tesserae next to each other, taking care not to leave any gaps. The triangular ends of the lozenge are useful to complete the overlay. It is also possible to cut some squares into shapes fitting the remaining spaces. The more precise the overlay, the better the aesthetic outcome of the graft. Fig.3a

In elderly patients, particular precision is not necessary because the aesthetic results are generally good anyway. Fig. 3b

We put in place a greasy gauze wrapping a saline moistened gauze pad, in the customary shape for grafts, fixed with a mildly compressive adhesive plaster, without positioning any tie-over bolster on top.

After four days, we remove the dressing with extreme care, dissolving the scabs with hydrogen peroxide and physiological saline, so as not to dislodge the mosaic tesserae.

The mosaic pieces appear more or less congested, like in a single-flap graft. The dressing is repeated and checked again after three to four days.

At seven to eight days, the graft's hold is defined, sometimes with very small areas of necrosis that are removed and repaired by second intention.

In some cases, after a couple of months, if desired, we refined the outcome with a CO<sub>2</sub> laser.

After 6 months the results are good, both in terms of function and aesthetic outcome. Fig 4a and 4b.

### ***“Mosaic” graft, “Stripes” variant***

For larger surgical breaches, regular in shape, we have developed a variant of this technique, called “Stripes” technique.

A similar procedure to the “Mosaic” technique is carried out by determining the area of skin required for the repair, and harvesting it from the appropriate site.

The removed skin is left in long stripes, glue drops are placed on the breach every 1.5 cm or so, along the central positioning line of each stripe. The skin is laid and held in place in the manner and timing already described for the “Mosaic” technique. Care must be taken to fully lay out the edges of the skin stripe. Fig 5a

In this variant, the same dressing is used and the same control times as above are adopted. Outcomes have been evaluated after 2 months. Fig 5b

## **Results**

All patients successfully completed the graft and none of them needed further surgery. In some cases, small areas of superficial necrosis in some tessera healed by second intention without ever constituting a problem in terms of management or aesthetic outcome.

## **Discussion**

This “Mosaic” technique and its “Stripes” variant have been developed to allow us to treat people who have suffered extensive skin tissue loss with a simple, fast repair, avoiding large local flaps, which are often risky and burdensome for elderly patients and have no better aesthetic results than what we can achieve using this technique.

Moreover, we have aimed at using a full-thickness skin graft, which is the best aesthetic solution for grafts.

A surgical glue has already been used in grafts, but only as a replacement for fixation points on the perimeter of the free flap, as a variation of a traditional graft technique. However, it has never been used with this technique before and for full-thickness grafts.

The main advantages are:

It is easy to find a sufficient amount of full-thickness skin to repair large breaches, since it is a 1.2 cms wide stripe of skin with an almost unlimited length. The length is in fact limited only by the

area chosen for harvesting, which can reach tens of centimetres if taken from the torso and limbs, to the point of extending to very many square centimetres of available skin.

This technique very significantly reduces the operating time, something that in elderly patients with comorbidities is very important.

Using glue avoids the use of stitches and the tie-over bolster, saving a lot of time.

The width of the harvesting, limited to just over one cm, allows the harvest area to be quickly repaired with a primary closure with a running suture. The limited width of the harvesting often makes it possible to harvest from areas adjacent to the surgical breach which, in the case of traditional one-piece full-thickness grafting, would not be suitable as a harvesting area due to their small width.

Fixing each individual piece to the centre with glue allows perfect drainage of any blood and transudate seeping into the spaces between the mosaic “pieces” and guarantees the stability of the piece during the entire time of grafting, during dressing placement and also in the event of removal of the dressing due to accidental causes or to the action of uncooperative patients.

Central fixation of the piece gives another advantage over a traditional graft: it does not require a compression pad to push the central part of the free flap into contact with the wound bed, like in the case with perimeter fixation with stitches.

This feature makes the Mosaic technique, characterized by central fixation with glue, particularly useful in the case of concave areas such as the auricular concha or areas with poor compression options such as the nasal wing.

Grafting into the concha is usually done with one or two pieces, with central fixation with glue replacing the transfixion stitch, which is usually used to ensure adhesion of the centre of the graft to the bottom of the concha.

On the nasal wing, repair options with flaps are often not totally satisfactory. Using the “Mosaic” technique instead of one larger free flap leads to a better aesthetic result due to easier graft camouflage.

## **Conclusions**

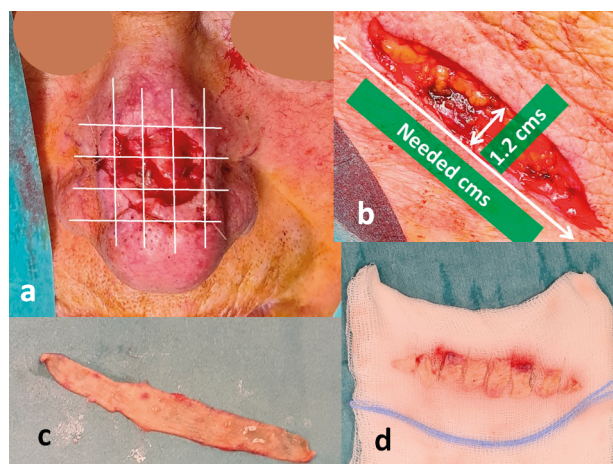
The “Mosaic” grafting technique and its “Stripes” variant have given both good functional and aesthetic results in the repair of large areas of skin, particularly following Mohs Micrographic Surgery.

Although this technique can be used in all categories of patients, including younger ones, it is especially indicated in elderly patients and patients with comorbidities, where the reduced operating time, low invasiveness and reliability of the technique are crucial.

This “Mosaic graft” technique has an optimal, but not exclusive, indication for non-cooperative older patients who have undergone MMS or other cutaneous surgical procedures with large irregular wounds, when we desire to reach a good cosmetic result and a skin harvest saving.

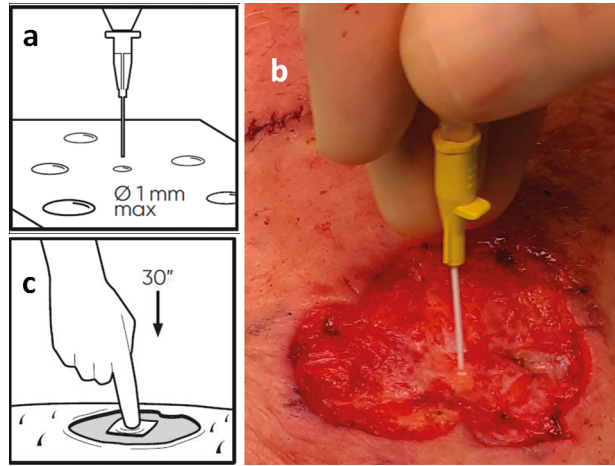
## References

1. Kattan AE, Mortada H, Alkahtani R, Bin Idris R et al. The use of cyanoacrylate glue for skin grafts stabilisation: A retrospective multicenter study. *Int Wound J.* 2023 Jan;20(1):79-84.
2. Mastud K, Lamture Y, Nagtode T, Rewale V. A Comparative Study Between Conventional Sutures, Staples, and Adhesive Glue for Clean Elective Surgical Skin Closure. *Cureus.* 2022 Nov7;14(11):e311196.
3. Grimaldi L, Cuomo R, Brandi C, Botteri G, et al. Octyl-2-cyanoacrylate adhesive for skin closure: eight years experience. *In vivo* 2015 Jan; 29(1) 145-148.
4. Curings P, Vincent P-L, Viard , Gir P, et al. The advantages in using cyanoacrylate glue over skin staples as a method of skin graft fixation in the pediatric burns population. *Ann Chir Plast Esthet.*2018 Jul; 63(4):323-329.
5. Samala CC, Dash S, Agrawal K, Tandon R. Comparative evaluation of three methods of skin graft fixation for split thickness skin graft after release of post burn contracture of the neck. *Burns.* 2019 May;45(3):691-698.

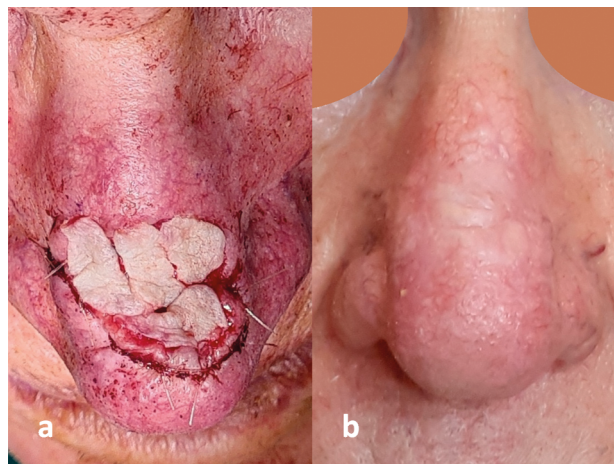




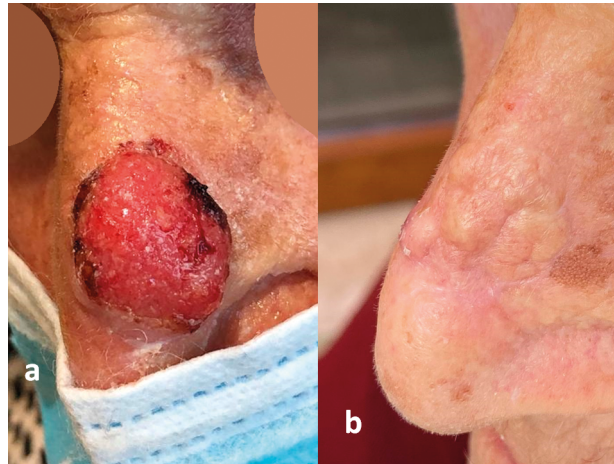
**Figure 1. a. Surgical wound and area calculation (squared cms); b. Donor area; c. Skin stripe of equivalent area; d. Cut mosaic tesserae.**



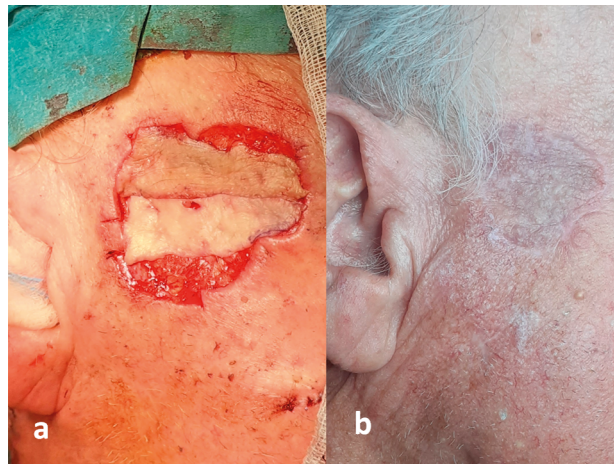
**Figure 2. a. Drop testing; b. Tesserae fixing; c. Positioning of the glue drop on the wound bed.**



**Figure 3. a. Mosaic completed; b. Outcome at three months.**



**Figure 4. a. Spino-cellular carcinoma of the nose; b. Outcome at two months after mosaic graft.**



**Figure 5. a. Mosaic graft, stripes technique variant; b. Outcome at two months.**