



Dermatology Reports

<https://www.pagepress.org/journals/index.php/dr/index>

eISSN 2036-7406



SIDCO

Società Italiana di Dermatologia
Chirurgica, Oncologica, Correttiva ed Estetica

Publisher's Disclaimer. E-publishing ahead of print is increasingly important for the rapid dissemination of science. **Dermatology Reports** is, therefore, E-publishing PDF files of an early version of manuscripts that undergone a regular peer review and have been accepted for publication, but have not been through the copyediting, typesetting, pagination and proofreading processes, which may lead to differences between this version and the final one. The final version of the manuscript will then appear on a regular issue of the journal. E-publishing of this PDF file has been approved by the authors.

Please cite this article as: Montanari A, Caroppo F, Amabile A, et al. Suspect dyskeratotic neoformations in a 7-year-old child with keratitis-ichthyosis-deafness syndrome: diagnostic, surgical and wound care management. Dermatol Rep 2024 [Epub Ahead of Print] doi: 10.4081/dr.2024.9953



© the Author(s), 2024
Licensee PAGEPress, Italy

Submitted: 03/02/2024 – Accepted 14/02/2024

Note: The publisher is not responsible for the content or functionality of any supporting information supplied by the authors. Any queries should be directed to the corresponding author for the article.

All claims expressed in this article are solely those of the authors and do not necessarily represent those of their affiliated organizations, or those of the publisher, the editors and the reviewers. Any product that may be evaluated in this article or claim that may be made by its manufacturer is not guaranteed or endorsed by the publisher.

Suspect dyskeratotic neoformations in a 7-year-old child with keratitis-ichthyosis-deafness syndrome: diagnostic, surgical and wound care management

Alvise Montanari,^{1,2} Francesca Caroppo,^{2,3,4} Antonio Amabile,^{1,2} Anna Fortina Belloni,^{2,3} Franco Bassetto^{1,2}

¹Plastic Surgery Unit, Department of Neuroscience, University of Padua; ²European Network for Rare Skin Disorders (ERN-Skin) Padua; ³Pediatric Dermatology Regional Center, Department of Women's and Children's Health (SDB), University of Padua; ⁴Dermatology Unit, Department of Medicine (DIMED), University of Padua, Italy

Correspondence: Alvise Montanari, Via Trieste 26, 35121, Padua, Italy.

Tel.: +39.3469570090.

E-mail: alvisemontanari@yahoo.it

Key words: kid syndrome; skin neoformations; rare skin disorders; pediatric wound care; medical honey.

Contributions: AM, main contributor to the manuscript, assisted with the surgeries,; AM, FC, reviewed the literature, took care of the patient follow-up; FC, contributed to the introduction section; FC, AFB, contributed to the histological examination part of the manuscript, , provided histological pictures; AA, contributed to the surgical management part of the manuscript, performed the surgeries, provided patient pictures; FB, contributed to the wound care management part of the manuscript, provided NPT and advanced dressing. All the authors reviewed the manuscript and approved the final version to be published.

Conflict of interest: the authors declare no potential conflict of interest.

Funding: none.

Ethical approval and consent to participate: since there was no clinical trial, the case did not require approval from the ethics committee.

Availability of data and material: sensitive data regarding hospitalization, surgical procedures, histological results, and outpatient clinics are stored in the University Hospital of Padua archive, in conformity with Italian legislation.

Consent for publication: the parents of the patient gave their consent for the publication of this case report and any accompanying images.

Abstract

Keratitis-ichthyosis-deafness syndrome (KID) is a rare genetic disorder characterized by the triad of hyperkeratosis, ichthyosis, and congenital prelingual sensorineural deafness, with less than 100 cases described in the literature. In addition to many other extra-cutaneous manifestations, these patients are burdened by two principal increased risk factors involving the skin: the risk of developing infections and the risk of developing malignant skin tumors, especially Squamous Cell Carcinoma and Trichilemmal tumors. We present the case of a 7-year-old girl with a unique genetic variant described to date, who developed 4 dyskeratotic neoformation. Since the dermatoscopic examination was not sufficient to exclude malignancy, excisional and punch biopsies were used. Nonetheless, healing was challenging, with wound dehiscence and infection onset. Ad hoc wound care management resorting to negative pressure therapy and advanced medical honey-based dressings was necessary to achieve complete wound healing.

Introduction

Keratitis-ichthyosis-deafness syndrome (KID) is a rare genetic disorder with less than 100 cases described in the literature. KID syndrome is caused by the GJB2 gene mutation inducing a connexin 26 protein deficit, and is characterized by the triad of hyperkeratosis, particularly of the palms and the soles, ichthyosis with thickened, dry, and fish-scale-like skin and congenital prelingual sensorineural deafness, with a wide range of gravity. A wide spectrum of skin/tegumental affections like keratoderma, scalp alopecia, partial loss of the eyebrows, nail dystrophy, photophobia, and dental anomalies are also commonly described. **1,2**

In addition to all the extra-cutaneous manifestations, which require a careful multidisciplinary approach, especially by audiologists, ophthalmologists, and dermatologists from the first months of life, there are two principal increased risk factors involving the skin in patients with KID syndrome: the risk of developing infections and the risk of developing malignant skin tumors. **3**

Infectious risk

The skin involvement of patients affected by KID syndrome leads to an increased risk of developing skin infections. According to some authors, up to 50% of KID patients develop a skin infection during their lifetime, which especially in the first year of life can lead to potentially fatal septicemia. **4**

The pathogens most frequently detected in infected wounds are *Staphylococcus* and *Streptococcus* species, *Proteus mirabilis*, *Pseudomonas Aeruginosa*, *Serratia marcescens*, *Escherichia coli* and *Klebsiella Pneumoniae*. **5**

Fungal infections are also recurrent in these patients, with the most frequently detected pathogens being *Candida Albicans* and *Trichophyton rubrum*. The most involved sites are the genital area, the oropharyngeal mucosa, and the nail area of the hands and feet. When the nail area is affected, the onset of phenomena such as paronychia or onychomycosis can frequently lead to onychodystrophy.

2

To prevent or treat the onset of infections, although there are no specific guidelines for patients suffering from KID syndrome, treatments can be aimed at preserving skin integrity, with the use of emollients and keratolytic agents, prophylaxis of infections with baths in antiseptics, or to the treatment of infections with antibiotic therapy for OS or antifungals such as ketoconazole. **6**

Oncological risk

Two skin tumors appear to be more closely related to KID syndrome.

Trichilemmal tumors are the most frequently described tumors in patients suffering from KID syndrome. There are different histotypes related to this class of tumor, from benign cysts to highly differentiated tumors up to metastatic malignant ones. Once considered different entities, the current concept is to call them proliferating follicular-cystic neoplasms: a single continuous spectrum, in which benign cystic lesions can progress to become metastatic follicular carcinomas. Although the majority are diagnosed as benign tumors, it is not straightforward to predict their behavior and potential progression to malignant forms, also due to considerable variability between patients and disease rarity. Although these tumors remain more common in patients in the 60-70 years range not affected by KID syndrome, the risk of developing metastases is higher in younger affected patients (30-40 years old). **7,8,9**

The typical histological features are rapid keratinization, a mixed presence of solid or cystic structures with possible areas of necrosis, and different types of cellular atypia. Suspicious traits most associated with malignancy are instead the onset rapidity combined with prompt exophytic growth, the presence of ulcerations, and areas of necrosis. **10**

Given the potential malignancy and the hardship in predicting lesions progression, careful monitoring is critical in order not to delay the diagnosis and intervention with Mohs surgery or extensive surgical exeresis. For metastatic diseases, systemic chemotherapy is indicated. **2,11**

Squamous Cell Carcinoma (SCC) also develops with a certain frequency in patients suffering from KID syndrome. During the sixties, it was the first skin carcinoma associated with this pathology. **12** Incidence is higher in acral areas and those locations subjected to chronic inflammation, such as sites affected by repeated candida infections. Although widespread hyperkeratosis may impede easy diagnosis, red flags are rapid growth in or near acral areas of ulcers/fistulas, granulation tissue, young

age, and associated weight loss. Due to correct diagnosis delays and the significant aggressiveness in patients suffering from KID syndrome, diagnoses of already metastatic diseases are not uncommon, and often limb amputations are required to ensure oncological radicality. According to some authors, metastatic SCC represents the most probable cause of death in these patients, and it is therefore essential not to delay the diagnosis and opt for aggressive and radical surgeries. **2** For invasive cases, radiotherapy has shown a certain efficacy in larger tumors, while the prophylactic use of systemic retinoids has not yet provided concrete evidence and is burdened by some side effects. Nonetheless, some studies showed promising results regarding its prophylactic capacity, thanks to its modulation in connexins expression. **11-13**

Case report

We present the case of a 7-year-old girl with KID syndrome, with a unique genetic variant described to date c.148G>T of GJB2 gene. **14**

Already followed in the Department of Dermatology for recurrent cutaneous infections, bilateral cheilitis, and diffuse dermatitis, this little patient was referred to the Plastic Surgery Unit for two small dyskeratotic neoformations located on the left elbow and left mesogastrium and a bigger one on the pube and left groin. All of them appeared in the prior six months and parents stated that they were rapidly growing in size. Figure 1

Clinical and dermoscopic characteristics of these lesions did not allow us to exclude any potentially malignant tumors like squamous cell epithelioma. Considering the uncertain incidence of neoplastic skin diseases in this very rare syndrome and the clinical evolution, the indication we found most appropriate was the complete excision of the elbow, left abdomen and left groin neoformations, which could be easily closed with a direct suture. A double punch biopsy was preferred instead for the considerably larger pube one, to have histological results before the complete excision.

Surgery was performed under local anesthesia and sedation. The elbow and abdomen histologic exams revealed acute hyperkeratosis and papillomatosis with telangiectasis, while inverted follicular keratosis and traces of panniculitis were additionally found in the pube and groin. The histological examination of pube and groin lesions showed an epidermis with hyperplasia, hyperkeratosis, and pseudoneoplastic acanthosis, while the dermis showed intense inflammation reaching the hypodermis. Furthermore, in the basal layer lymphocytes- and plasma cells- infiltrates were detected with no histological characteristics of atypia. These findings suggested a diagnosis of an inverted follicular keratosis, a benign skin tumor with exophytic or endophytic growth with a parakeratotic plug in the center and without cellular atypia. Figure 2-3

No neoplastic features were found. The histological result of the pube neoformation was later confirmed when the complete excision was performed. For the wound closure we used absorbable monofilament suture threads, to avoid a painful removal and the need for sedation or further outpatient sessions. Figure 4

At the 15 days post-surgical follow-up, the elbow and the left abdomen wounds appeared completely closed, and the scars, in the process of maturation, appeared eutrophic and normochromic without any tendency to keloid degeneration. The pube and groin wounds were instead dehiscent. This could be induced both by greater skin tension, due to the wider excised area, and by the site's proximity to the genitals and urinary tract. Figure 5

Cutaneous swabs on the dehiscent wound were sampled several times, revealing the growth of *Proteus Mirabilis*, *Citrobacter Koserii*, and non-multi-drug resistant *Pseudomonas Aeruginosa*. Systemic antibiotic therapy with amoxicillin and clavulanic acid was therefore set up for six days.

Two months after the first biopsy, surgical revision with an accurate debridement of all non-vital tissues was performed, and Negative Pressure Therapy (NPT) was applied for 10 days to control the exudate and enhance the granulation tissue growth. **15**

The wounds were later successfully treated with medical honey, a medicament whose antibacterial, anti-inflammatory, and pro-healing effects have already been widely described in the literature, and its use is widely considered safe for pediatric patients. **16**

Medical honey-based dressings were changed three times per week and three weeks after the NPT was removed, the wounds were completely healed. Daily massages with silicon-based gels were recommended to support correct scar maturation and favorable esthetic results.

Discussion and Conclusions

According to our experience, and consistent with the literature, the diagnosis of uncertain skin lesions in patients with KID syndrome should be based on biopsy and histological examination.

Clinical characteristics such as widespread hyperkeratosis and the uncertain behavior of the most commonly related tumors, due to the rarity of this syndrome, make it extremely challenging to exclude malignant forms with dermoscopic examination alone. Furthermore, in doubtful cases, oncological radicality should be achieved even at the price of extensive exeresis.

Wound healing complications, often caused by the onset of bacterial or fungal infections, for which these patients are burdened by increased risk, should be addressed using the most appropriate tools, like advanced dressings, NPT, and antibiotic therapy when needed. The use of absorbable threads, in order to avoid their removal but wait for their spontaneous fall, could be among the factors favoring the onset of infectious processes. However, it is good to balance the possible risk with the need to

reduce the stress of hospital visits and sedated procedures, especially in these fragile pediatric patients suffering from rare multifactorial diseases, who frequent hospital environments from a young age. Among absorbable sutures, the most appropriate choice would be monofilament threads, which have demonstrated greater resistance to infections onest. 17

Finally, the medical honey-based resulted very helpful for wound healing management, modulating inflammation, enhancing re-epithelialization, and preventing infections without resorting blindly to antibiotics. We therefore recommend their use, especially in the most fragile patients who can avoid having to resort to oral or systemic drugs.

Conclusions

Although they cannot be considered routine events, in a hub center for rare diseases like ours, it is not an impossible circumstance to come across an extremely rare disease such as KID syndrome, with only a hundred cases described in the literature to date. In the absence of dedicated guidelines, knowledge of the available scientific literature is paramount to guarantee the best treatment for these patients. In our case, the little 7-year-old girl presented both the typical skin-level manifestations of this pathology: the appearance of suspicious lesions with uncertain behavior and the development of skin infections. However, the analysis of the available literature, combined with the know-how of a plastic surgery department accustomed to operating on children, permitted the correct management of the case, avoiding delays in diagnosis or the onset of chronic lesions/infections.

References

1. Dey VK, Saxena A, Parikh S. KID Syndrome: A Rare Genodermatosis. *Indian Dermatol Online J.* 2020 Jan 13;11(1):116-118. doi: 10.4103/idoj.IDOJ_87_19. PMID: 32055527; PMCID: PMC7001397.
2. Cammarata-Scalisi F, Willoughby CE, Cárdenas Tadich A, et al. Clinical, etiopathogenic, and therapeutic aspects of KID syndrome. *Dermatol Ther.* 2020 Jul;33(4):e13507. doi: 10.1111/dth.13507. Epub 2020 Jul 4. PMID: 32367610.
3. Coggshall K, Farsani T, Ruben B, et al. Keratitis, ichthyosis, and deafness syndrome: a review of infectious and neoplastic complications. *J Am Acad Dermatol.* 2013 Jul;69(1):127-34. doi: 10.1016/j.jaad.2012.12.965. Epub 2013 Feb 4. PMID: 23384797.
4. Haruna K, Suga Y, Oizumi A, et al. Severe form of keratitis-ichthyosis-deafness (KID) syndrome associated with septic complications. *J Dermatol.* 2010;37(7):680-682. doi:10.1111/j.1346-8138.2010.00839.x

5. Harms M, Gilardi S, Levy PM, Saurat JH. KID syndrome (keratitis, ichthyosis, and deafness) and chronic mucocutaneous candidiasis: case report and review of the literature. *Pediatr Dermatol*. 1984 Jul;2(1):1-7. doi: 10.1111/j.1525-1470.1984.tb00433.x. PMID: 6390393.
6. Hazen PG, Walker AE, Stewart JJ, et al. Keratitis, ichthyosis, and deafness (KID) syndrome: management with chronic oral ketoconazole therapy. *Int J Dermatol*. 1992 Jan;31(1):58-9. doi: 10.1111/j.1365-4362.1992.tb03524.x. PMID: 1737693.
7. Satyaprakash AK, Sheehan DJ, Sangüeza OP. Proliferating trichilemmal tumors: a review of the literature. *Dermatol Surg*. 2007 Sep;33(9):1102-8. doi: 10.1111/j.1524-4725.2007.33225.x. PMID: 17760602.
8. Ackerman AB, Reddy VB, Soyer HP. Neoplasms with follicular differentiation. 2nd ed. New York: Ardor Scribendi; 2001.
9. López-Ríos F, Rodríguez-Peralto JL, Aguilar A, et al. Proliferating trichilemmal cyst with focal invasion: report of a case and a review of the literature. *Am J Dermatopathol*. 2000 Apr;22(2):183-7. doi: 10.1097/00000372-200004000-00018. PMID: 10770443.
10. Nyquist GG, Mumm C, Grau R, et al. Malignant proliferating pilar tumors arising in KID syndrome: a report of two patients. *Am J Med Genet A*. 2007 Apr 1;143A(7):734-41. doi: 10.1002/ajmg.a.31635. PMID: 17330861.
11. Werchau S, Toberer F, Enk A, Helmbold P. Keratitis-ichthyosis-deafness syndrome: response to alitretinoin and review of literature. *Arch Dermatol*. 2011 Aug;147(8):993-5. doi: 10.1001/archdermatol.2011.216. PMID: 21844472.
12. Lancaster L Jr, Fournet LF. Carcinoma of the tongue in a child: report of case. *J Oral Maxillofac Surg* 1969;27:269-70.
13. Rudkin GH, Carlsen BT, Chung CY, et al. Retinoids inhibit squamous cell carcinoma growth and intercellular communication. *J Surg Res*. 2002 Apr;103(2):183-9. doi: 10.1006/jsre.2001.6346. PMID: 11922733.
14. Caroppo F, Szekeley S, Fortina AB. Novel Variant c.148G>T of GJB2 Gene in a 5-Year-Old Child with KID Syndrome. *Indian Dermatol Online J*. 2020 Nov 8;11(6):1014-1015. doi: 10.4103/idoj.IDOJ_603_20. PMID: 33344363; PMCID: PMC7735005.
15. Santosa KB, Keane AM, Keller M, et al. Inpatient Versus Outpatient Management of Negative Pressure Wound Therapy in Pediatric Patients. *J Surg Res*. 2020 Oct;254:197-205. doi: 10.1016/j.jss.2020.04.025. Epub 2020 May 23. PMID: 32450421; PMCID: PMC7484025.
16. McNamara SA, Hirt PA, Weigelt MA, et al. Traditional and advanced therapeutic modalities for wounds in the paediatric population: an evidence-based review. *J Wound Care*. 2020 Jun 2;29(6):321-334. doi: 10.12968/jowc.2020.29.6.321. PMID: 32530778.

17. Fowler JR, Perkins TA, Buttaro BA, Truant AL. Bacteria adhere less to barbed monofilament than braided sutures in a contaminated wound model. *Clin Orthop Relat Res.* 2013 Feb;471(2):665-71. doi: 10.1007/s11999-012-2593-z. Epub 2012 Sep 22. PMID: 23001503; PMCID: PMC3549181.

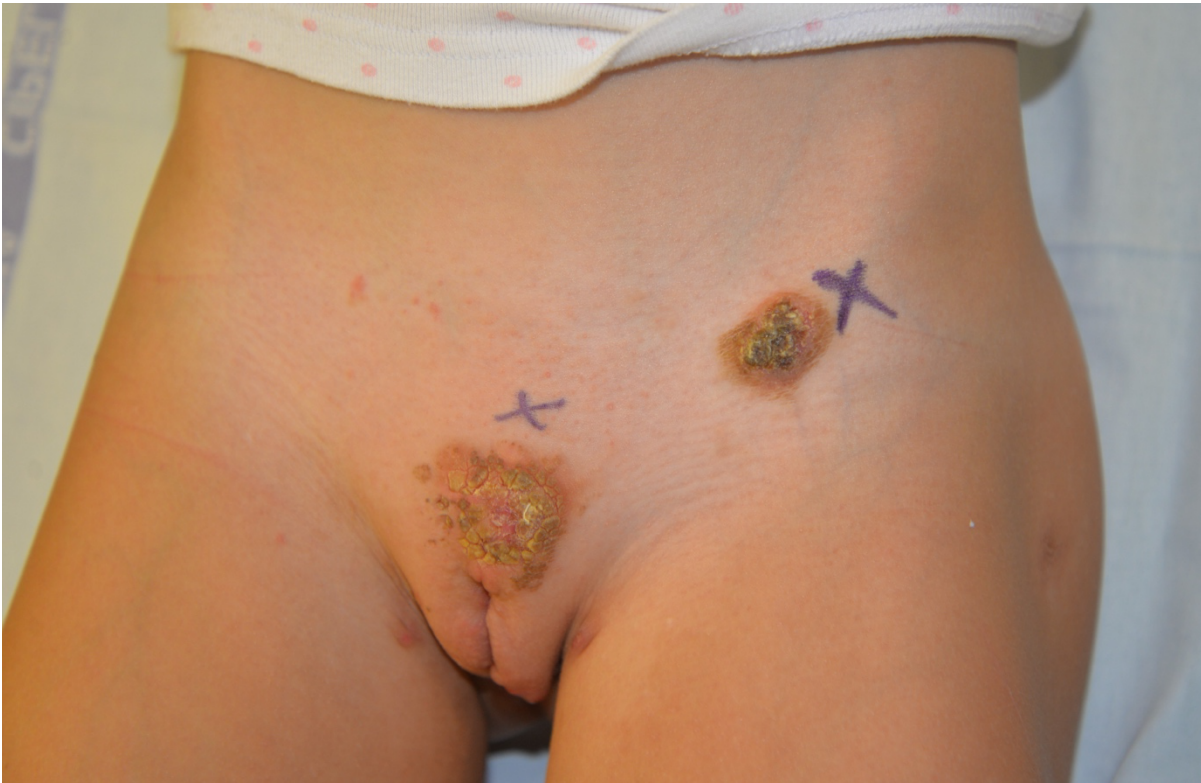

Figure 1. Diskeratotic lesion on the pube and left groin area.

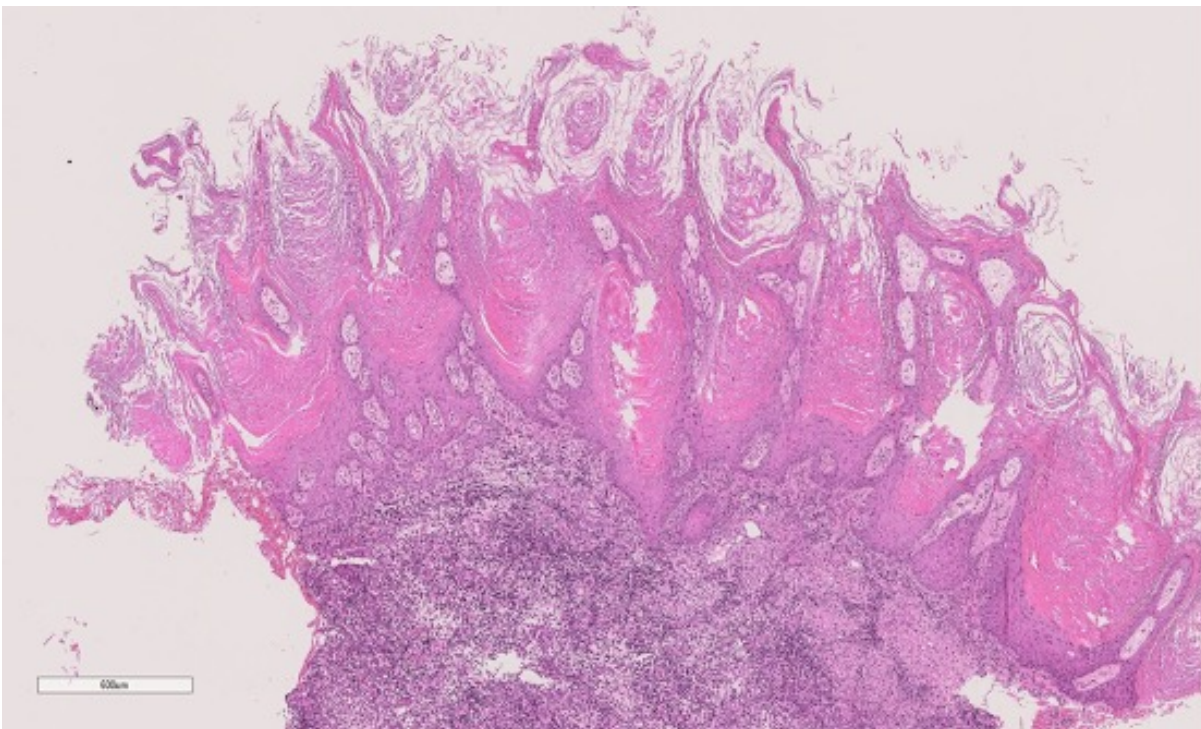


Figure 2. Histological sections (stained with hematoxylin and eosin – H&E) of pube and groin skin lesions were examined by light microscopy under x 10 magnifications. The histological

examination showed epidermidis with hyperplasia, hyperkeratosis and pseudoneoplastic acanthosis. Dermis showed intense inflammation reaching the hypodermis.

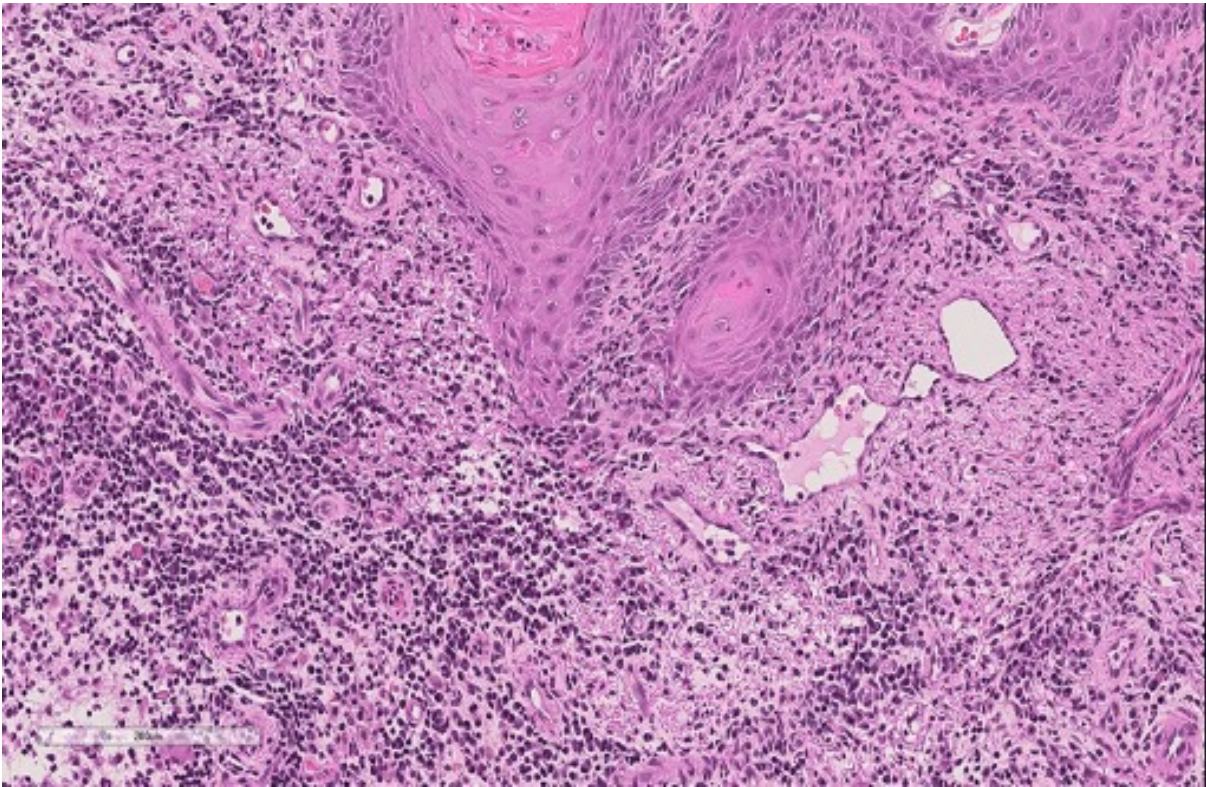


Figure 3. Histological sections were examined by light microscopy under x 30 magnifications. In the basal layer lymphocytes- and plasma cells- infiltrates were detected with no histological characteristics of atypia. These findings suggested a diagnosis of an inverted follicular keratosis, a benign skin tumor with exophytic or endophytic growth with a parakeratotic plug in the centre.

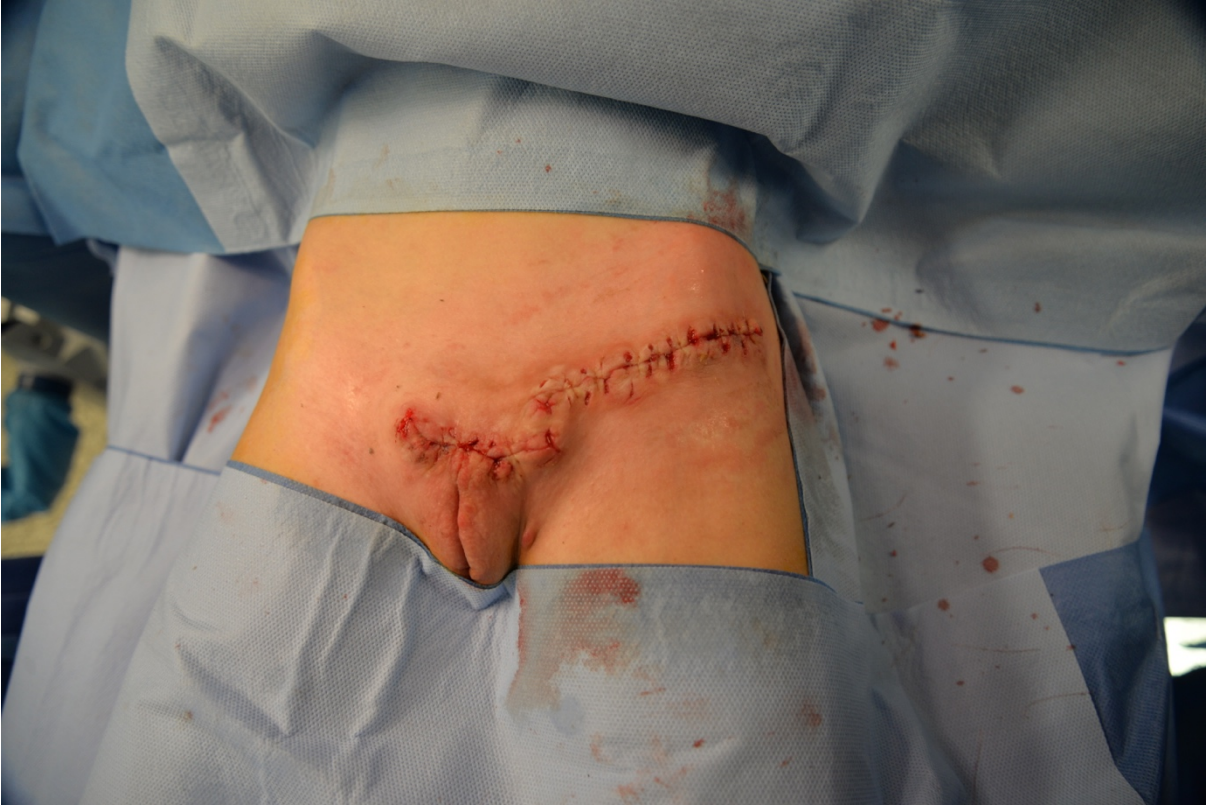

Figure 4. Left groin and pube wounds after complete excision was performed.

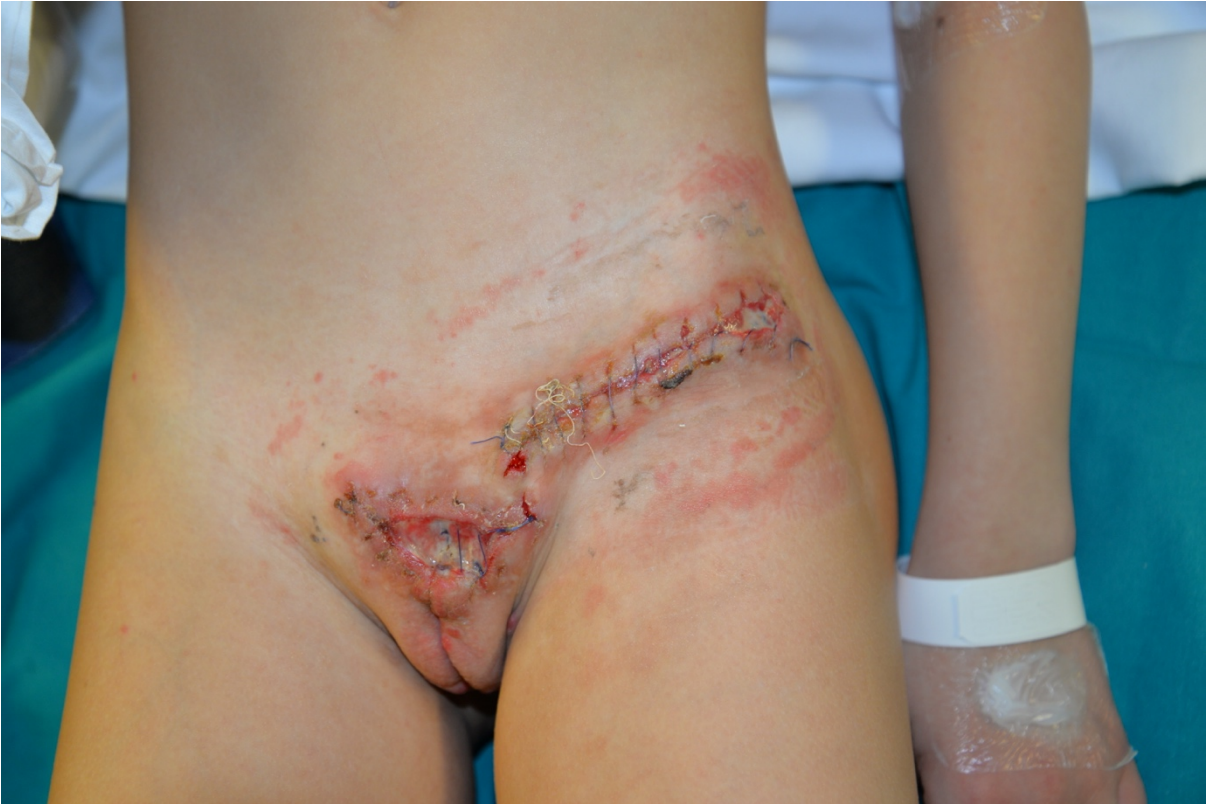

Figure 5. Left groin and pube dehiscent wounds at 15 days follow up.