



Dermatology Reports

<https://www.pagepress.org/journals/index.php/dr/index>

eISSN 2036-7406



ASSOCIAZIONE DERMATOLOGI-VENEREOLOGI
OSPEDALIERI ITALIANI e della SANITÀ PUBBLICA



SIDCO

Società Italiana di Dermatologia
Chirurgica, Oncologica, Correttiva ed Estetica



Publisher's Disclaimer. E-publishing ahead of print is increasingly important for the rapid dissemination of science. **Dermatology Reports** is, therefore, E-publishing PDF files of an early version of manuscripts that undergone a regular peer review and have been accepted for publication, but have not been through the copyediting, typesetting, pagination and proofreading processes, which may lead to differences between this version and the final one. The final version of the manuscript will then appear on a regular issue of the journal. E-publishing of this PDF file has been approved by the authors.

Please cite this article as: Shimada Y, Ono H, Shimizu A. A case of symmetrical subepidermal calcified nodules on the eyelids. Dermatol Rep 2024 [Epub Ahead of Print] doi: 10.4081/dr.2024.9944



© the Author(s), 2024
Licensee PAGEPress, Italy

Submitted: 21/01/2024 – Accepted 04/02/2024

Note: The publisher is not responsible for the content or functionality of any supporting information supplied by the authors. Any queries should be directed to the corresponding author for the article.

All claims expressed in this article are solely those of the authors and do not necessarily represent those of their affiliated organizations, or those of the publisher, the editors and the reviewers. Any product that may be evaluated in this article or claim that may be made by its manufacturer is not guaranteed or endorsed by the publisher.

A case of symmetrical subepidermal calcified nodules on the eyelids

Yoko Shimada, Hiroto Ono, Akira Shimizu

Department of Dermatology, Kanazawa Medical University, Uchinada, Ishikawa, Japan

Correspondence: Akira Shimizu, Department of Dermatology, Kanazawa Medical University, Daigaku 1-1, Uchinada, Ishikawa 920-0293, Japan.

Tel.: +81.762188141.

Fax: +81.762866369

E-mail: ashimizu@kanazawa-med.ac.jp

Key words: subepidermal calcified nodules; xanthoma palpebrarum; idiopathic calcinosis cutis.

Acknowledgments: the authors received no funding pertaining to this report. We gratefully acknowledge the understanding and support of our patient.

Contributions: all the authors contributed equally.

Conflict of interest: the authors declare no potential conflict of interest.

Funding: none.

Informed consent: informed consent has been obtained from the patient.

Dear Editor,

Subepidermal calcified nodules (SCN), are typically asymptomatic, solitary, and idiopathic cutaneous calcinosis.¹ We report a case with two SCN with a symmetrical distribution, where a single nodule was located on the medial aspect of each of the bilateral upper eyelids in a teenage male.

The patient had been aware of the SCN three years earlier but did not seek treatment at the time. Upon clinical examination, two white nodules, each about 8 mm diameter, firm, well-defined, and with mild elevation, one on each medial aspect of the bilateral upper eyelids, were observed (Figure 1A). The nodules were nonpainful, and there was no family history of familial cholesterolemia. Blood samples indicated normal levels of cholesterol and triglyceride ruling out Xanthelasma. The nodules were surgically excised under local anesthesia. Histological examination revealed a uniform basophilic mass in the upper dermis (Figure 1B). Von Kossa staining was positive, calcified materials in the upper dermis, leading to the diagnosis of SCN (Figure 1C). To date, no recurrence has been observed.

Cutaneous calcinosis involves the deposition of calcium in the dermis and subcutaneous tissue. It is clinically classified into five subtypes: dystrophic, idiopathic, metastatic, iatrogenic, and calciphylaxis.² SCN falls under the idiopathic subtype, characterized by absence of any underlying disease or metabolic disorder.

SCN is a common form of cutaneous calcinosis found on the face in young patients, and is typically observed as a solitary lesion. Clinical features include the presence of white papules, usually measuring less than 1 cm, with a verrucous or smooth surface.¹

Differential diagnoses include conditions such as xanthelasma palpebrarum, pilomatricoma, and milia. Pathological findings often reveal granular or lobulated calcified material with basophilic dark staining extending from the epidermis to the subdermis, and Von Kossa staining shows a positive reaction. Treatment options include surgical excision, CO2 laser therapy,³ and liquid nitrogen cryotherapy.

The mechanism of SCN is unknown. Several theories have been proposed, including traumatic calcification due to repetitive irritation, calcification at the site of skin injury, or deposition of calcium on pre-existing lesions such as milia or sweat duct tumors.⁴ The mechanism of xanthelasma palpebrarum involves leakage of plasma lipoproteins through dermal capillaries, phagocytosis by macrophages, and formation of lipid-laden foam cells.⁵ Additionally, the connective tissue of the eyelid is coarse and prone to retention of plasma components, which may leak out when one blinks. In our case, rather than a solitary nodule, two were present, one each on the medial side of both upper eyelids necessitating differentiation from xanthomas.

Unlike previously reported cases of SCN, this case presented with symmetric nodules on the medial

aspect of the bilateral upper eyelids. Pathologically, there were calcareous deposits around the vessels, suggesting that, as in eyelid xanthomas, they may have been caused by leakage of plasma components.

References

1. Patel AD, Bellet JS. That's Not Molluscum! A literature review of 109 cases of subepidermal calcified nodules. *Pediatric Dermatology*. 2021;38(4):759–763.
2. Reiter N, El-Shabrawi L, Leinweber B, Berghold A, Aberer E. Calcinosis cutis: Part I. Diagnostic pathway. *Journal of the American Academy of Dermatology*. 2011;65(1):1–12.
3. Joo YH, Kwon IH, Huh CH, Park KC, Youn SW. A Case of Persistent Subepidermal Calcified Nodule in an Adult Treated with CO2 Laser. *The Journal of Dermatology*. 2004;31(6):480–483.
4. Zeglaoui F, Khaled A, Fazaa B, Riahi O, Zermani R, Kamoun M. Multiple subepidermal calcified nodules on the eyelids with eruptive syringomas: a possible ethiopathogenic relationship. *Journal of the European Academy of Dermatology and Venereology*. 2009;23(3):337–339.
5. Nguyen AH, Vaudreuil AM, Huerter CJ. Systematic review of laser therapy in xanthelasma palpebrarum. *International Journal of Dermatology*. 2017;56(3):e47–e55.

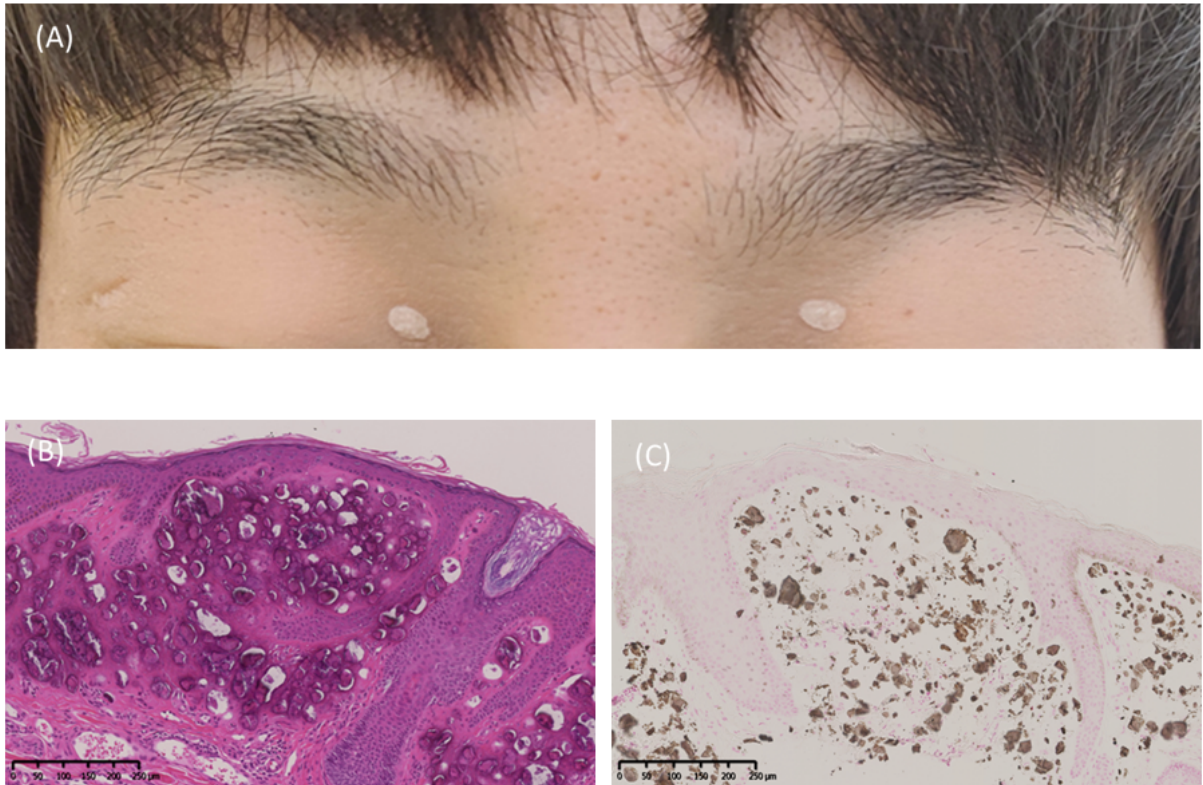


Figure 1. A) Symmetrical white nodules on the medial aspect of both upper eyelids; B) Calcified material with basophilic staining around blood vessels and in the shallow to lower dermis (hematoxylin and eosin stain×100); C) Von Kossa staining was positive (Von Kossa stain×400).