



Dermatology Reports


<https://www.pagepress.org/journals/index.php/dr/index>

eISSN 2036-7406



Publisher's Disclaimer. E-publishing ahead of print is increasingly important for the rapid dissemination of science. **Dermatology Reports** is, therefore, E-publishing PDF files of an early version of manuscripts that undergone a regular peer review and have been accepted for publication, but have not been through the copyediting, typesetting, pagination and proofreading processes, which may lead to differences between this version and the final one. The final version of the manuscript will then appear on a regular issue of the journal. E-publishing of this PDF file has been approved by the authors.

Please cite this article as: Condorelli AG, Paganelli A, Marraccini C, et al. Platelet-rich plasma for the treatment of scleroderma-associated ulcers: a single-center experience and literature review. Dermatol Rep 2023 [Epub Ahead of Print] doi: 10.4081/dr.2024.9878

 © the Author(s), 2024
Licensee PAGEPress, Italy

Submitted: 20/10/2023 – Accepted 04/02/2024

Note: The publisher is not responsible for the content or functionality of any supporting information supplied by the authors. Any queries should be directed to the corresponding author for the article.

All claims expressed in this article are solely those of the authors and do not necessarily represent those of their affiliated organizations, or those of the publisher, the editors and the reviewers. Any product that may be evaluated in this article or claim that may be made by its manufacturer is not guaranteed or endorsed by the publisher.

Platelet-rich plasma for the treatment of scleroderma-associated ulcers: a single-center experience and literature review

Alessandra Grazia Condorelli,^{1*} Alessia Paganelli,^{1*} Chiara Marraccini,² Elena Ficarelli,¹ Alfonso Motolese,³ Luca Contu,¹ Alberico Motolese¹

¹Dermatology Unit, Azienda USL-IRCCS di Reggio Emilia, Arcispedale Santa Maria Nuova, Reggio Emilia; ²Transfusion Medicine Unit, AUSL-IRCCS di Reggio Emilia; ³Section of Dermatology, Department of Clinical and Experimental Medicine, University of Messina, Italy

*These authors contributed equally.

Correspondence: Alessandra Grazia Condorelli, Arcispedale Santa Maria Nuova of Reggio Emilia, Viale Risorgimento 80, 42123, Reggio Emilia, Italy.

Tel.: +39.3335359202.

E-mail: alecondor91@outlook.it

Key words: PRP; scleroderma ulcers; homologous PRP; systemic sclerosis.

Conflict of interest: the authors declare no potential conflict of interest.

Funding: none.

Availability of data and material: data and materials are available by the authors.

Informed consent: the patients involved in this study gave their consent for the publication.

Abstract

Systemic sclerosis (SS) is a complex connective tissue disease characterized by vasculopathy and progressive fibrosis, primarily considered an autoimmune disorder. SS can affect multiple organs and tissues, including the skin, respiratory, gastrointestinal, genitourinary, cardiovascular, and musculoskeletal systems. Skin involvement is common, and SS-related ulcers, especially digital ulcers, occur in roughly 50% of patients. These ulcers not only cause pain but also significantly impact patients' quality of life, and in severe cases, they can lead to infection, gangrene, and amputation. The search for novel therapies for scleroderma-related ulcers remains an ongoing research area. Platelet-rich plasma (PRP) has been investigated as a potential treatment for difficult-to-heal ulcers, including diabetic, pressure, and vascular ulcers. In this study, we share our experience in treating scleroderma ulcers with PRP. Ten patients with confirmed SS and chronic skin ulcers lasting at least six weeks, which had not responded to conventional treatments, were selected for the study. Homologous PRP gel was prepared and applied once a week for up to eight weeks. The ulcers were documented photographically before and after PRP treatment, and pain levels were assessed using a visual analog scale (VAS). We also conducted a systematic review of the literature focusing on the use of PRP in the setting of SS. The results from our casuistry showed that the ten patients, including eight females and two males with a median age of 52.5 years, had ulcer sizes ranging from 0.78 cm² to 28.26 cm². The ulcers were located on fingers, legs, and heels, and they were associated with various forms of SS, including limited and diffuse cutaneous involvement. Raynaud's phenomenon was prevalent, and two patients exhibited organ involvement. The average ulcer size at the end of PRP treatment decreased significantly, with a 78% reduction in ulcerated area. Pain levels also markedly improved, as indicated by a reduction in VAS scores. With regards to systematic revision of literature, we retrieved 45 cases of SS treated with PRP-based therapeutic regimes. However, only a minority of them (n=16) underwent PRP treatment for the treatment of SS-related ulcers. An improvement in wound size and pain has been documented in all cases. Taken together, these data highlight the potential benefits of using homologous PRP in the treatment of scleroderma ulcers, emphasizing its positive impact on ulcer size reduction and pain relief.

Introduction

Systemic sclerosis (SS) is a connective tissue disease characterized by a process of vasculopathy and progressive fibrosis. As for the pathogenesis, SS is considered autoimmune disorder. Due to its systemic basis, SS potentially affects all the organs and tissues of the human body, including the respiratory, gastro-enteric, genito-urinary, cardiovascular and musculoskeletal systems¹. The skin is one of the most frequently involved sites. Skin ulcers, especially digital ulcers, are a frequent

complication of SS, occurring in about 50 percent of patients². SS-related ulcers are often cause of pain and represent an important burden in terms of patients' quality of life. In more severe cases, scleroderma ulcers can lead to infection, gangrene and, eventually, amputation². SS ulcers are typically localized at the metacarpophalangeal, proximal interphalangeal, and distal interphalangeal joints. Lower extremities represent the second most frequent site of occurrence of SS-related ulcers. Several therapeutic strategies have been proposed for the prevention and treatment of skin ulcers in SS. The use of Bosentan, an endothelin-1 receptor antagonist, has been shown to reduce the incidence of cutaneous ulcers, but has demonstrated little efficacy on promoting healing of pre-existing ulcers. The most widely used therapy for the treatment of ulcers in SS is represented by intravenous prostaglandin analogs (e.g., Iloprost), which has been proven to have even higher vasodilator effects when compared to oral administration³. To date, the identification of new therapies is still a growing field of research for patients with scleroderma ulcers. The use of platelet-rich plasma (PRP) has already been described in the literature for the treatment of difficult-to-heal ulcers, including diabetic, pressure, vascular ulcers⁴. PRP is characterized by high concentration of growth factors and cytokines involved in the wound healing process. In the setting of SS, some case reports and small cohort studies indicate the potential effectiveness of PRP for the treatment of cutaneous ulcers (for a detailed overview see the Discussion section). The aim of the present paper is to report our experience on the treatment of scleroderma ulcers with PRP and to provide a comprehensive overview of the available literature on this topic. Therefore, we present a case series of ten subjects treated with PRP gel for SS-related ulcers at our center. We also report the results of systematic literature revision of the available publications focusing on the use of PRP in the setting of SS ulcers.

Materials and Methods

Case series

Ten patients affected by SS-related ulcers were selected at our center (Dermatology Unit, Reggio Emilia Research Institute) according to the following criteria: (i) age > 18; (ii) confirmed diagnosis of SS; (iii) chronic skin ulcers lasting for at least 6 weeks; (iii) resistance to conventional treatments, including prostanoids, phosphodiesterase 5 inhibitors, calcium channel blockers, antiplatelet agents and /or an 8-week course of optimal wound care. Homologous PRP was applied once a week until complete healing, for up to 8 applications. PRP gel was locally applied at the ulcer site and covered with paraffin gauze and secondary bandages. Photographic documentation of ulcers before and after PRP treatment was acquired, and the ulcer area was calculated. Each patient answered the VAS questionnaire to assess pain both at time 0 and at the end of treatment.

Homologous PRP gel was prepared at the Transfusion Medicine Unit of the AUSL-IRCCS of Reggio Emilia according to the following protocol. PRP was obtained by healthy donors with platelet count above 180×10^9 plt/l. Platelet concentrate was collected through an automated apheresis procedure (MCS Collection System, Haemonetics Corp.). The final unit of platelet concentrate had the following main characteristics: minimal residual plasma content, adequate preservative solution content to maintain $\text{pH} > 6.4$ throughout the storage period; average final volume of 180 ml; platelet count of at least 2×10^{11} plt/unit. The units were irradiated at 35Gy and stored at 25°C until all the infectious screening results become available. PRP collected by apheresis was then processed with thrombin and calcium gluconate to obtain the gel preparation before administration.

Systematic literature review

A search was conducted on PubMed/Medline electronic database from inception to present. The detailed search strategy used the following terms: scleroderma [Title/Abstract] AND PRP [Title/Abstract] OR platelet rich plasma [Title/Abstract] OR platelet gel [Title/Abstract] OR metabolite [Title/Abstract]. All the major journals were indexed. Only journal articles were taken into consideration, while books and book chapters were excluded. Articles without full text electronically available and/or English translation were also excluded. Only journal articles focused on scleroderma and PRP treatment were taken into account. Review articles were not included. The search was not restricted on human studies.

The following data was collected for each paper: author, year, type of subject enrolled (human/animal), type of platelet-based product, administration (topical, injection), target of the treatment (sclerosis/ulcer), number of treated patients, site of treatment, controls, results.

Results

Ten patients were treated with PRP (8 females and 2 males), with a median age of 52.5 years. Ulcer size varied from 0.78 cm^2 to 28.26 cm^2 . As for the anatomical sites involved, 5 were located on the fingers, 4 on the legs and 1 on the heel. Chronic skin ulcers were associated in 60% of cases with SS with limited skin involvement and in 40% with diffuse cutaneous SS. Raynaud's phenomenon was present in 90% of patients; telangiectasias, present in the face and/or hands, were also detected in the majority of cases (70%). Two patients presented with organ involvement. Clinical and demographic characteristics of the patients are summarized in Table 1.

Baseline mean ulcer size was 7.57 cm^2 (± 8.53) and mean VAS for pain was $6(\pm 1.2)$. Mean number of PRP applications was 4.7. The average ulcer size at the end of treatment was 1.04 cm^2 (± 0.93), with a 78% reduction in ulcerated area. All patients reported marked improvement in terms of pain

score, with a mean VAS of 2 ± 0.4 (SD) at the end of treatment. For further details on the characteristics of skin ulcers see Supplementary Table 1. Photographic documentation of two enrolled ulcers before and after PRP treatment is shown in Figure 1.

With regards to systematic revision of the literature, the bibliographic research identified 92 publications, with 88 papers being considered after duplicate removal. No complete fulfillment of the other inclusion criteria was found in 78 papers. A total of 10 papers met all the research criteria and were therefore considered for the present work. The main characteristics of selected studies are reported in Table 2.

Globally, the retrieved publications included 45 patients treated with PRP-based therapeutic regimes. The majority of these ($n=29$) were treated for microstomia and facial sclerosis¹⁰⁻¹². PRP was generally combined with other therapeutic strategies (such as SVF, lipofilling or hyaluronic acid) and injected locally. All treated patients experienced significant improvement in terms of mouth's opening and skin elasticity.

With regards to the treatment of scleroderma-associated ulcers, most of the available literature is based on case reports¹³. The larger casuistry ($n=12$) on the use of topical PRP gel for the treatment of scleroderma-associated ulcers was published in 2012 by Giuggioli et al, who described PRP-mediated improvement in wound size and pain¹⁴.

Several authors proposed alternative types of platelet-containing preparations both in terms of source and processing, including protein rich fibrin (PRF) and heterologous PRP^{15,16}.

Discussion and Conclusions

Chronic skin ulcers are today considered a major problem in the clinical setting, not only for the disease burden, but also for the impairment in patient quality of life and the healthcare costs. Inflammatory ulcers of SS are particularly disabling due either to the young age of patients and the poor response to treatment. Moreover, ulcers tend to occur in aesthetic areas such as fingers, therefore affecting patient professional and private life⁵. In addition, pain is almost constant in patients with SS-related ulcers. Notwithstanding, current guidelines on the classification and treatment of ulcers in the course of SS remain controversial⁶. Calcium antagonists, prostanoids, and endothelin receptor antagonists are routinely used for the treatment of SS-related; however, they results are still not satisfactory, especially for the healing of preexisting wounds. PRP promote and accelerate the wound healing process thanks to the release of cytokines, chemokines and growth factors. Over the last 10 years, PRP has been widely used for regenerative purposes in many dermatologic conditions, including alopecia areata, lichen sclerosus, acne scars, rejuvenation, vitiligo, and cutaneous ulcers^{4,7}.

In particular, the use of PRP has already been described as effective for in the treatment of vascular and diabetic ulcers of the lower limbs, ulcerated lipoid necrobiosis and even SS ulcers^{8,9}.

As suggested by the data retrieved through systematic literature revision, PRP-based strategies seem to be particularly effective in the setting of SS, especially in the treatment of acral sclerosis and/or SS-related ulcers. However, current evidence is mostly limited to case reports and case series and randomized clinical trial are lacking. To date, three comparative studies were conducted on murine models of scleroderma to compare the effectiveness of PRP with other regenerative strategies (see Table 2). Collectively, the authors bring to evidence the effectiveness of PRP, especially when co-administered with adipose sources such as micro-fat¹⁷⁻¹⁹. However, SVF (stromal vascular fraction) seemed to bring better results in terms of vascularization when compared to PRP-based strategies^{18,19}. Several authors already hypothesized that platelet hyperactivation could contribute to the pathogenesis of scleroderma-related vasculopathy²⁰, therefore suggesting possible limitations of autologous PRP treatment in this subset of patients. Similar evidence is also available for other regenerative strategies, since aberrant mesenchymal stromal cells have been described in patients affected by systemic sclerosis¹².

Not only the use of homologous PRP potentially overcomes the intrinsic limitations of autologous regenerative sources in the setting of a systemic disorder, but also seems to have higher platelet and growth factors content, high degree of purity and a high degree of standardization.

Taken together, our results confirm these notions showing that PRP induces a reduction in ulcer size of 78% in an average of 5 weeks and promotes an improvement on pain associated with SS-related ulcers. However, despite the promising results achieved with PRP in the treatment of SS-related ulcers, further studies are needed to confirm our data and validate the use of PRP in the clinical scenario.

References

1. Kowalska-Kępczyńska A. Systemic Scleroderma-Definition, Clinical Picture and Laboratory Diagnostics. *J Clin Med.* 2022;11(9):2299. doi:10.3390/jcm11092299
2. Giuggioli D, Manfredi A, Lumetti F, Colaci M, Ferri C. Scleroderma skin ulcers definition, classification and treatment strategies our experience and review of the literature. *Autoimmun Rev.* 2018;17(2):155-164. doi:10.1016/j.autrev.2017.11.020
3. Kowal-Bielecka O, Fransen J, Avouac J, et al. Update of EULAR recommendations for the treatment of systemic sclerosis. *Ann Rheum Dis.* 2017;76(8):1327-1339. doi:10.1136/annrheumdis-2016-209909

4. Hessler MJ, Shyam N. Platelet-rich plasma and its utility in medical dermatology: A systematic review. *J Am Acad Dermatol.* 2019;81(3):834-846. doi:10.1016/j.jaad.2019.04.037
5. Matucci-Cerinic M, Krieg T, Guillevin L, et al. Elucidating the burden of recurrent and chronic digital ulcers in systemic sclerosis: long-term results from the DUO Registry. *Ann Rheum Dis.* 2016;75(10):1770-1776. doi:10.1136/annrheumdis-2015-208121
6. Costedoat I, Masson M, Barnetche T, et al. Locoregional Treatments for Digital Ulcers in Systemic Sclerosis: A Systematic Review. *Acta Derm Venereol.* 2021;101(6):adv00478. doi:10.2340/00015555-3839
7. Paganelli A, Contu L, Condorelli A, et al. Platelet-Rich Plasma (PRP) and Adipose-Derived Stem Cell (ADSC) Therapy in the Treatment of Genital Lichen Sclerosus: A Comprehensive Review. *Int J Mol Sci.* 2023;24(22):16107. doi:10.3390/ijms242216107
8. Meznerics FA, Fehérvári P, Dembrowszky F, et al. Platelet-Rich Plasma in Chronic Wound Management: A Systematic Review and Meta-Analysis of Randomized Clinical Trials. *J Clin Med.* 2022;11(24):7532. doi:10.3390/jcm11247532
9. Motolese A, Vignati F, Antelmi A, Saturni V. Effectiveness of platelet-rich plasma in healing necrobiosis lipoidica diabetorum ulcers. *Clin Exp Dermatol.* 2015;40(1):39-41. doi:10.1111/ced.12474
10. Abellan Lopez M, Philandrianos C, Daumas A, et al. Assessing the effect of PRP addition to facial micro-lipofilling for patients suffering from Scleroderma: A prospective routine care analysis. *Ann Chir Plast Esthet.* 2023;68(2):152-161. doi:10.1016/j.anplas.2022.07.016
11. Pirrello R, Verro B, Grasso G, et al. Hyaluronic acid and platelet-rich plasma, a new therapeutic alternative for scleroderma patients: a prospective open-label study. *Arthritis Res Ther.* 2019;21(1):286. doi:10.1186/s13075-019-2062-0
12. Virzì F, Bianca P, Giammona A, et al. Combined platelet-rich plasma and lipofilling treatment provides great improvement in facial skin-induced lesion regeneration for scleroderma patients. *Stem Cell Res Ther.* 2017;8(1):236. doi:10.1186/s13287-017-0690-3
13. Kanemaru H, Kajihara I, Yamanaka K, et al. Platelet-rich plasma therapy is effective for the treatment of refractory skin ulcers in patients with systemic sclerosis. *Mod Rheumatol.* 2015;25(4):660-661. doi:10.3109/14397595.2014.924204
14. Giuggioli D, Colaci M, Manfredi A, Mariano M, Ferri C. Platelet gel in the treatment of severe scleroderma skin ulcers. *Rheumatol Int.* 2012;32(9):2929-2932. doi:10.1007/s00296-011-2038-0
15. Shetty S, Shenoj SD. Autologous platelet-rich fibrin in treatment of scleroderma ulcer. *Int Wound J.* 2016;13(5):1065-1066. doi:10.1111/iwj.12480

16. Palumbo VD, Rizzuto S, Damiano G, et al. Use of platelet concentrate gel in second-intention wound healing: a case report. *J Med Case Rep.* 2021;15(1):85. doi:10.1186/s13256-020-02649-6
17. Wang HC, Li Z, Li Z, Wang X, Long X. Platelet-Rich Plasma Combined Fat Transplantation for the Treatment of Bleomycin-Induced Murine Scleroderma. *Ann Plast Surg.* 2023;90(6):626-630. doi:10.1097/SAP.0000000000003579
18. Daumas A, Magalon J, Delaunay F, et al. Fat Grafting for Treatment of Facial Scleroderma. *Clin Plast Surg.* 2020;47(1):155-163. doi:10.1016/j.cps.2019.08.016
19. Serratrice N, Bruzzese L, Magalon J, et al. New fat-derived products for treating skin-induced lesions of scleroderma in nude mice. *Stem Cell Res Ther.* 2014;5(6):138. doi:10.1186/scrt528
20. Macko RF, Gelber AC, Young BA, et al. Increased circulating concentrations of the counteradhesive proteins SPARC and thrombospondin-1 in systemic sclerosis (scleroderma). Relationship to platelet and endothelial cell activation. *J Rheumatol.* 2002;29(12):2565-2570.

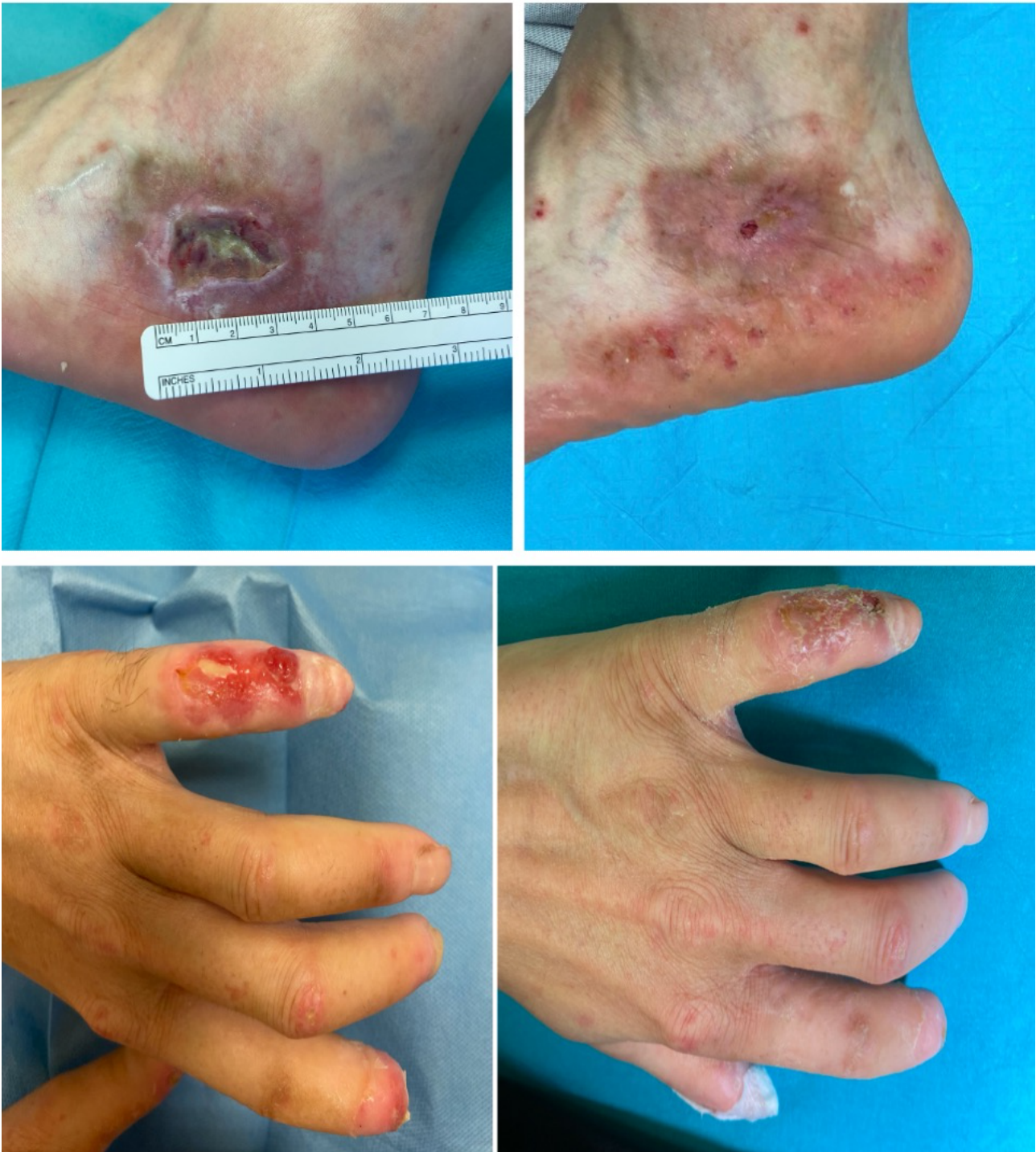

Figure 1. Clinical pictures of scleroderma-associated ulcers before (on the left) and after (right) treatment with PRP. Upper Panels: scleroderma skin ulcer of the V finger of left hand of a 45-year-old Caucasian female patient. Lower panels: Sclerodermic skin ulcer of the left lateral malleolar region of a 47-year-old Caucasian male patient. Left panels: skin ulcer before PRP treatment Right panels: after respectively 3 (top) or 6 (bottom) applications of homologous PRP once a week.

Table 1. Features of the 10 enrolled patients with SS and chronic ulcers.

Sex	
Female (%)	8 (80)
Age (median)	52,5
SS cutaneous subtypes	
Limited (%)	6 (60)
Raynaud's phenomenon, (%)	9 (90)
Teleangiectasias (%)	7 (70)
Organ involvement (%)	2 (20)
Esophagopathy	1
Pulmonary fibrosis	1
Antibodies (%)	
ANA	10 (100)
Anti-Scl-70 antibodies	3 (30)
Anti-ACA antibodies	8 (80)

ANA: antinuclear antibodies; Scl-70: anti-topoisomerase I Antibodies; ACA: anti-centromere antibodies.

Table 2. Characteristics of the main publications focusing on the use of PRP in the setting of scleroderma. N: number; ctrl: control groups.

Author	Year	Human vs. murine	Platelet-based product	Topical vs. injection	Ulcers vs. sclerosis	N patients	anatomical site	ctrl	Results
Wang	2023	murine	20% PRP + fat grafting	injection	sclerosis			fat alone, PBS	fibrosis (type III collagen) reduction, increase in VEGF, HGF, PDGF, CD31, IGF1R, PPAR γ
Abellan Lopez	2023	human	PRP + micro-lipofilling	injection	sclerosis	13	facial	micro-lipofilling	significant decrease in Mouth Handicap In Systemic Sclerosis (MHIS) scale score at 6 months
Daumas	2020	murine	PRP alone AND PRP+microfat	injection	sclerosis			Macrofat (Coleman's procedure), microfat, SVF, microfat +SVF	MF + SVF and MF + PRP significant reduction of the dermal and the epidermal sclerosis; Macrofat, SVF and PRP only corrected dermal sclerosis; only SVF alone or SVF + MF showed a significant increase of the vessel density
Pirrello	2019	human	PRP + hyaluronic acid	injection	sclerosis	10	facial		increase in mouth's opening, freedom of movement of the lips, and skin elasticity at 1-month and 2-y FUP.
Virzi	2017	human	PRP + SVF	injection	sclerosis	6	facial		improvement in buccal's rhyme, skin elasticity and vascularization
Palumbo	2017	human	heterologous PRP gel	topical	ulcers	1	surgical wound (AV fistula)		granulation tissue formation, wound healing

Shetty	2016	human	PRF	topical	ulcers	1	acral (fingertips, toes,elbows)		ulcer healing, pain reduction
Kanemaru	2015	human	PRP gel	topical	ulcers	2	acral (fingertips, amputated knee)		epithelization
Serratrice	2014	murine	PRP alone AND PRP+micro fat	injection	sclerosis			Macro- fat, MF, SVF, MF + SV F, MF + PR P	fibrosis and vascular improvement; MF derived products more stable; SVF demonstrated better pro- angiogenic effects.
Giuggioli	2012	human	PRP gel	topical	ulcers	12	ns		improvement in wound size, pain (VAS), health assessment questionnaire (HAQ)