

Unusual post-blepharoplasty infection: *Gordonia Bronchialis* case study

McKenzie E. Maloney,¹ Brennan Bogdanovich,¹ Christina Lohmann,² Brian Maloney^{3,4}

¹Medical College of Georgia, Augusta University, Georgia; ²Department of Pathology, Northside Hospital, Atlanta, Georgia; ³Associate Clinical Professor, Department of Surgery, UGA/UA Medical Partnership, Athens, Georgia; ⁴The Maloney Center for Plastic Surgery, Atlanta, Georgia, United States

Abstract

Post-procedure infections following in-office blepharoplasty are rare. *Gordonia bronchialis* is a weakly acid-fast, gram-positive, aerobic Actinomycetes that rarely causes infections in humans. A 35-year-old female presented two weeks after an upper blepharoplasty with cyst-like swellings near the incision site. Injection with Kenalog did not resolve the cyst. Histology of the cyst showed benign fibroadipose tissue with noncaseating granu-

lomatous inflammation alongside occasional foreign body giant cells. Anaerobic culture yielded *Gordonia Bronchialis*. Amoxicillin 750 mg QID was prescribed. The infection regressed but reappeared after tapering. A CT scan showed a small retention cyst in the right sphenoid sinus. The patient was then put on amoxicillin and clavulanic acid combination 875 mg BID and Minocycline 100 mg BID for 3-4 weeks. After two months of treatment, the infection was cleared. Most commonly, post-blepharoplasty infections are due to Mycobacterium. We report a case of *G. bronchialis* infection following a cutaneous surgery performed in the office.

Correspondence: Brian Maloney, UGA/UA Medical Partnership, 6111 Peachtree Dunwoody Rd Bldg. E Suite 201, Atlanta, GA 30328, USA
Tel.: +1.770.804-0007 - Fax: +1.770.804.0777.
E-mail: bmaloney@maloneycenter.com

Key words: *Gordonia bronchialis*; blepharoplasty; cutaneous infection; cutaneous surgery; post-surgical infection.

Contributions: the authors contributed equally.

Conflict of interest: the authors declare no potential conflict of interest.

Availability of data and materials: All data underlying the findings are fully available.

Ethics approval and consent to participate: No ethical committee approval was required for this case report by the Department, because this article does not contain any studies with human participants or animals. Informed consent was obtained from the patient included in this study.

Consent for publication: the patient gave her consent for the publication of this case report.

Conference presentation: this case was presented at the Georgia Medical Association Conference in Savannah, GA in October 2023.

Received: 9 October 2023.

Accepted: 12 November 2023.

This work is licensed under a Creative Commons Attribution-NonCommercial 4.0 International License (CC BY-NC 4.0).

©Copyright: the Author(s), 2024
Licensee PAGEPress, Italy
Dermatology Reports 2024; 16:9865
doi:10.4081/dr.2024.9865

Publisher's note: all claims expressed in this article are solely those of the authors and do not necessarily represent those of their affiliated organizations, or those of the publisher, the editors and the reviewers. Any product that may be evaluated in this article or claim that may be made by its manufacturer is not guaranteed or endorsed by the publisher.

Introduction

The *Gordonia* genus is part of the aerobic Actinomycetes family which are gram-positive bacteria. *Gordonia bronchialis* originally was identified in the soil and in sputum cultures from individuals with tuberculosis.¹ *G. bronchialis* infection has also been implicated in sternal wound infections,² infections of implanted surgical material,² and in relation to bacteremia of immunocompromised individuals.⁴ Here, we describe a case of *Gordonia bronchialis* infection in a novel location, in an immunocompetent woman following cutaneous surgery.

Case Report

A 35-year-old healthy female presented to the clinic with slight swelling of the medial aspect of the left upper eyelid, two weeks after an upper blepharoplasty procedure. There was no skin discoloration or warmth. The patient stated that she had been working in the basement of her office building. She also had a dental cleaning shortly after the procedure but no other medical history. The area was injected with 0.1ml of Kenalog 10.

One month later, the patient returned to the clinic because the area had organized into a cyst about 7mm above the eyelid incision, Figure 1. There was no erythema; attempted aspiration revealed no fluid. The area was injected with 0.1ml of Kenalog 20.

The patient returned three weeks later with skin discoloration over the medial eyelid and the formation of a second cyst. She was afebrile but complained of pressure over the eye. CT scan was unremarkable except for the subcutaneous cystic area.

Following injection with 1% lidocaine and 1:100,000 epinephrine, the cystic area was excised, and seropurulent fluid was sent for culture. The wound was cleaned and closed with superficial 5.0 prolene sutures. The patient was placed on a 10 day course amoxicillin and clavulanic acid combination 875mg BID and Bactrim DS BID.

Histology showed benign fibroadipose tissue with noncaseating granulomatous inflammation alongside occasional foreign body giant cells, Figure 2. Gram positive coccoid/bacillary bacteria were identified, Figure 3; GMS and AFB stains, for fungi and acid fast bacilli respectively, were negative. Aerobic culture yield-

ed *Gordonia Bronchialis*, an Actinomycete. No susceptibility data was available.

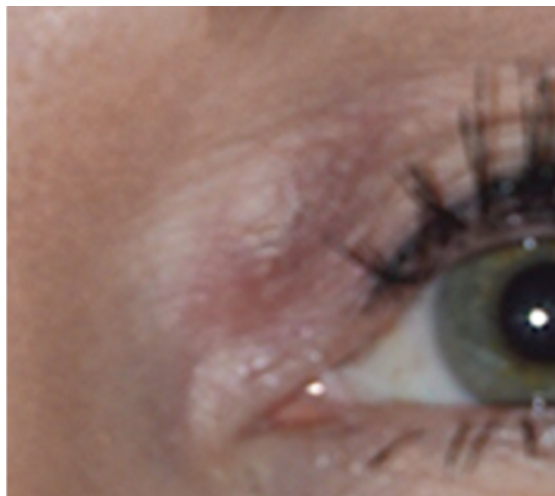

Figure 1. Organized cyst on the medial aspect of the left upper eyelid 9 weeks following upper blepharoplasty.

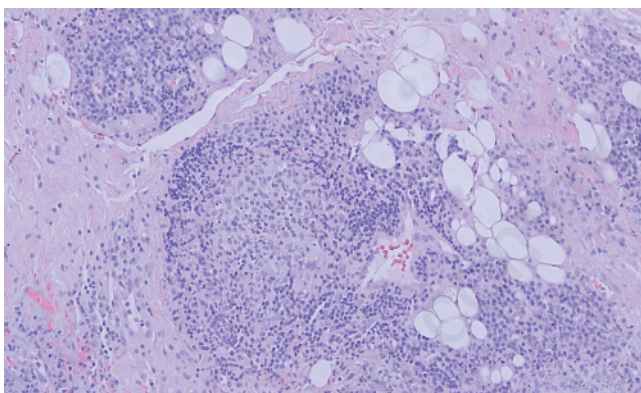


Figure 2. On histology of the excised cyst, non-caseating granulomatous inflammation.

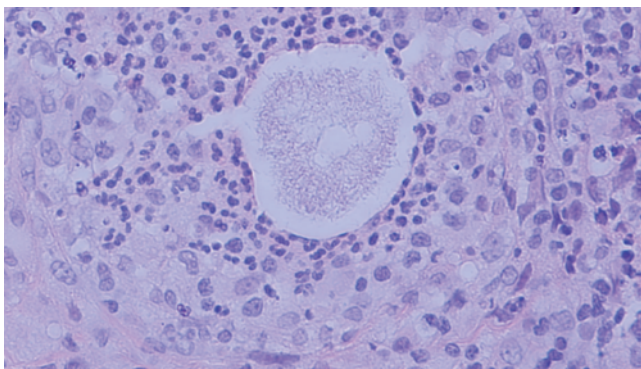


Figure 3. On cyst biopsy, gram-positive coccoid/bacillary bacteria were seen.

The patient was treated with Amoxicillin 750mg four times daily. The swelling resolved over the next month, at which point the antibiotic was decreased to twice daily. The nodule reappeared, and the patient was sent for an infectious disease consult. The patient was placed on amoxicillin and clavulanic acid combination 875 mg every 12 hours and minocycline 100mg twice daily for 4 weeks. The patient experienced improvement, however, required continuation of the antibiotics for another 4 weeks for resolution.

Discussion

Gordonia bronchialis, a gram-positive, weakly acid fast, aerobic Actinomycetes¹, has recently been recognized to cause human infections. It was discovered in 1971 from soil samples and was isolated from sputum in tuberculosis patients¹. Since that time, *G. bronchialis* has caused bacteremia following implantation of objects during bypass surgery² and in immunocompromised patients⁴.

On review of the literature, *G. bronchialis* has rarely reported causing a cutaneous infection once following injection of a natural product⁶ and once following acupuncture of the lower extremity⁵. However, there are no previous reports of *G. bronchialis* causing an infection following a minor procedure in an immunocompetent individual. Further, post-blepharoplasty infections are extremely rare. Review of the literature from 2018-2023 yielded three reports: one case report of Mycobacterium Septicum infection,⁷ one case series with seven patients with atypical mycobacterium infection,⁸ and one prospective study with two cases of post-blepharoplasty infections.⁹

Here we report a novel case of soft tissue infection by *G. bronchialis* of the upper eyelid in an immunocompetent woman. The infection manifested as several cysts in the area and were unresponsive to surgical resection and steroids. Similar to previous reports, *Gordonia* species can be difficult to treat; our patient required several rounds of antibiotics to clear the infection.

Conclusions

Infections following blepharoplasty are very rare and most commonly involve mycobacterium. However, we report a case of *Gordonia bronchialis* infection post-blepharoplasty in a woman with no known risk factors. Therefore, infection with *G. bronchialis* may be considered when cysts form post-operatively.

References

1. Tsukamura M. Proposal of a new genus, Gordonia, for slightly acid-fast organisms occurring in sputa of patients with pulmonary disease and in soil. J. Gen. Microbiol. 1971;68:15-26.
2. Richet H, Craven P, Brown J, et al. A cluster of Rhodococcus bronchialis sternal-wound infections after coronary-artery bypass surgery. N. Engl J. Med. 1991;324:104-109.
3. Siddiqui N, Toumeh A, & Georgescu C. Tibial osteomyelitis caused by Gordonia bronchialis in an immunocompetent patient. J Clin Microbiol. 2012;50:3119-3121.
4. Sng L, Koh T, Toney S, et al. Bacteremia caused by Gordonia bronchialis in a patient with sequestered lung. J. Clin. Microbiol. 2004;42:2870-2871.

5. Choi M, Jung C, Won C, et al. Case report of cutaneous nodule caused by *Gordonia bronchialis* in an immunocompetent patient after receiving acupuncture. *J Dermatol.* 2019;46:343-346.
6. Bartolome-Alvarez J, Saez-Nieto J, Escudero-Jimenez A, et al. Cutaneous abscess due to *Gordonia bronchialis*: case report and literature review. *Rev Esp Quimioter.* 2016;29:170-173.
7. Shin H, Song JK, Hong JG, et al. Surgical Site Infection Caused by *Mycobacterium Septicum* Following Blepharoplasty. *The Journal of craniofacial surgery.* 2020;31:e228–e230.
8. Zhan S, Hoang A, Escaravage GK, et al. Preventing Postoperative Atypical Mycobacterial Infection. *Ophthalmic plastic and reconstructive surgery.* 2019;35:235–237.
9. Wang D, Shinder R. Comparison of Postoperative Infection Rates After Office-based Oculoplastic Procedures Using Sterile and Clean Gloves. *Ophthalmic plastic and reconstructive surgery.* 2023;39:146–149.

Non-commercial use only