

# Unilateral eosinophilic fasciitis (Shulman syndrome) with excellent response to combined treatment with methotrexate therapy and compression brace

Corrado Zengarini,<sup>1,2</sup> Giacomo Clarizio,<sup>1,2</sup> Federico Bardazzi,<sup>1,2</sup> Martina Mussi,<sup>1,2</sup> Carlotta Baraldi,<sup>1,2</sup> Bianca Maria Piraccini,<sup>1,2</sup> Alessandro Pileri<sup>1,2</sup>

<sup>1</sup>Dermatology Unit, IRCCS of Azienda Ospedaliero-Universitaria, Bologna; <sup>2</sup>Department of Medical and Surgical Sciences, University of Bologna, Italy

Dear Editor,

We report the case of a 78-year-old Caucasian male examined in our dermatological unit for swelling of the right arm. He described an increase in right arm size, which had a slow and progressive growth over the last two years and a perception of skin hardening and difficulty in flexing and extending the joint. Moreover, he has been experiencing muscle pain during the previous eight months.

The past medical history accounts for a non-Hodgkin B cell lymphoma marginal type treated ten years before with splenecto-

my and cycles of rituximab, bendamustine, and six-year-old hypertension managed with valsartan 10 mg tablet daily. The rest of the medical history was unremarkable.

During the physical examination, we observed a visible right arm swelling, almost doubling in size the left one (58 cm circumference vs. 30 cm), erythema and palpable skin induration with a typical texture resembling an orange peel. However, no joint pain was triggered during the physical examination (Figure 1).

Due to the typical clinical presentation, we suspected eosinophilic fasciitis in the first instance (Shulman syndrome).<sup>1</sup> We performed a full-thickness biopsy deep down the fascia of the arm, which showed lymphocytic infiltrate, eosinophils and oedema in the dermis. Blood tests demonstrated moderate eosinophilia ( $1.65 \times 10^9/L$ ) and no other abnormalities, and the magnetic resonance image revealed an inflammatory process of the muscle fascia, confirming the diagnosis of unilateral eosinophilic fasciitis.<sup>1</sup> It should be noted that it has not been considered any correlation with the previous lymphoma history, given the elapsed time.

We started glucocorticoid therapy with daily prednisone at the dose of 1 mg per kilogram.<sup>3,4</sup> Still, achieving no results after two months of steroid therapy, we changed to the administration of subcutaneous methotrexate at a dosage of 15 mg per week, followed the day after with 2 mg of folic acid in tablets. At the end of three months of methotrexate therapy, the patient reported no more muscle pain and a return into the normality range for eosinophil count, but arm swelling was unaffected.

After performing an eco-color doppler of the arm vessels to exclude arterial affection at the end of the three months of the systemic therapy, we decided to add to methotrexate an elastic compression brace made by nonwoven-fabric with a pressure range of 18-21 mmHg, which enveloped the limb from fingertips up to the armpit to be used at least during daytime.<sup>1,5</sup>

Two months later, we significantly reduced the circumference (34 cm vs. 30 cm of the left arm) and improved skin texture (Figure 2). In addition, the total mobility of the right arm was recovered.

Eosinophilic fasciitis, also known as Shulman's disease, is a rare condition that initially can be misdiagnosed as lymphedema or scleroderma manifested by a rapid onset of erythema, oedema, and induration of skin and soft tissues symmetrically, preferably on the limbs, and occasionally on the trunk, associated with peripheral eosinophilia.<sup>1,3</sup>

Muscle biopsy can be crucial during the diagnostic procedure, showing eosinophils located at the muscle-fascia interface with variable involvement of the underlying muscle, often associated with typical peri-fascicular atrophy and inflammatory infiltrates in the epimysial region. Sometimes, when a skin sample is included, eosinophils are also seen in the dermis in variable numbers.<sup>6</sup> Moreover, it is known that the management of this disease must be timely; achieving an almost complete remission is possi-

Correspondence: Giacomo Clarizio, Dermatology Unit, IRCCS of Azienda Ospedaliero-Universitaria di Bologna, via Massarenti 9, 40138, Bologna, Italy.  
Tel.: +39.0512144848.  
E-mail: giacomo.clarizio@studio.unibo.it

Key words: Shulman; fasciitis; eosinophilia; oedema; brace.

Contributions: AP, conceptualization, CZ, data curation, formal analysis, software; BMP, funding acquisition; FB, AP, investigation; GC, MM, AP, methodology; FB, CB, BMP, AP, supervision, validation, writing – original draft; CZ, GC, writing - review & editing. All the authors approved the final version to be published.

Conflict of interest: the authors declare no potential conflict of interest.

Data availability statement: data available on request from the authors.

Consent for publication: the patients in this manuscript have given written informed consent to the publication of their case details.

Received: 20 July 2023.

Accepted: 23 July 2023.

This work is licensed under a Creative Commons Attribution-NonCommercial 4.0 International License (CC BY-NC 4.0).

©Copyright: the Author(s), 2023

Licensee PAGEPress, Italy

Dermatology Reports 2024; 16:9807

doi:10.4081/dr.2023.9807

*Publisher's note: all claims expressed in this article are solely those of the authors and do not necessarily represent those of their affiliated organizations, or those of the publisher, the editors and the reviewers. Any product that may be evaluated in this article or claim that may be made by its manufacturer is not guaranteed or endorsed by the publisher.*

ble while the oedematous phase is still ongoing. In contrast, once the fibrotic second phase is reached, it is harder to treat this condition since tissue modification tends to be irreversible.<sup>1</sup>

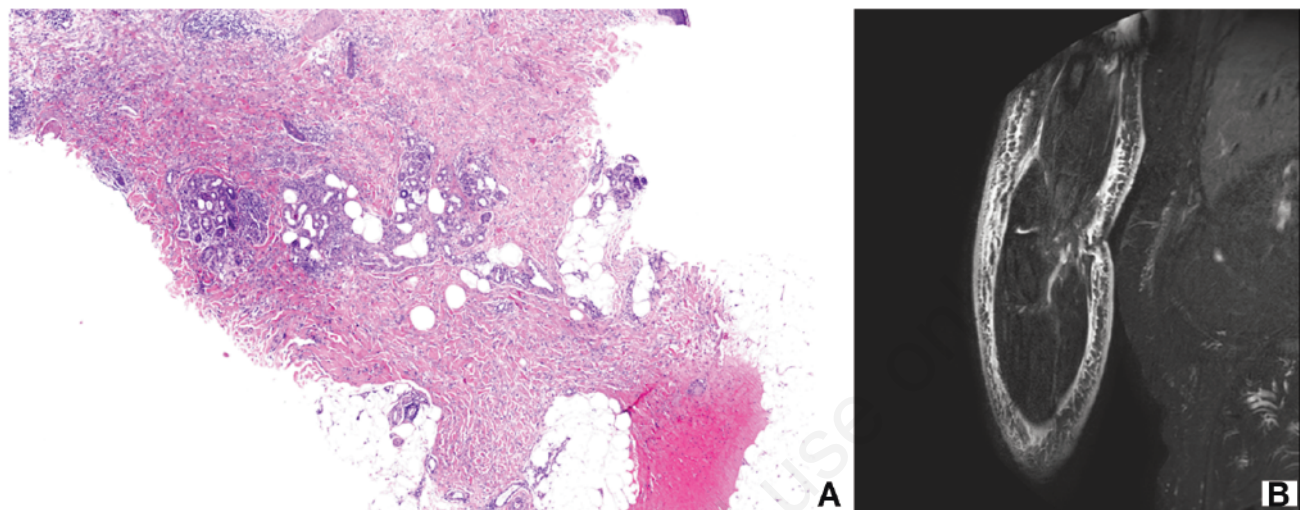
Although methotrexate has already been reported to be effective in treating eosinophilic fasciitis, even when started late,<sup>7</sup> this did not happen in our case.

Since it is known that plasma exudate can lead to the increase of cytokines that can aggravate or maintain the inflammatory response,<sup>8-10</sup> we assumed that that compression, known to favor

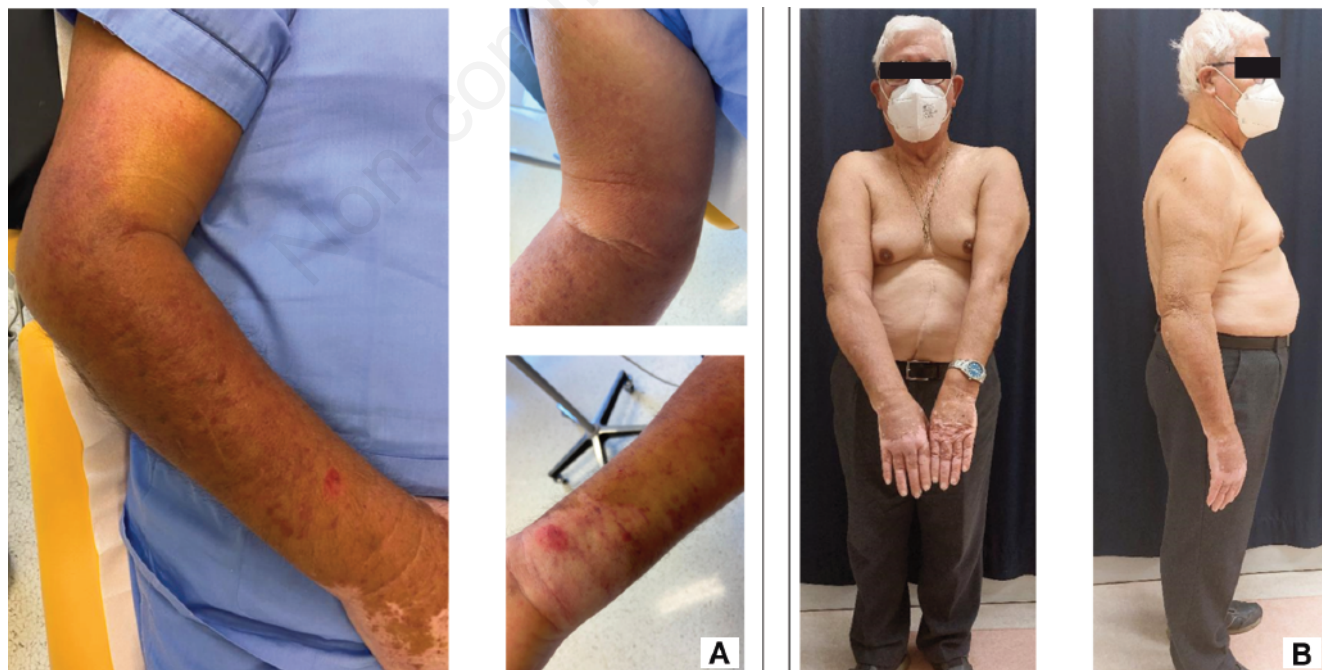the reabsorption of liquids from the third space, could bring a synergic benefit and accelerate the clinical improvement in the actual oedematous phase.

After one year and a half, the patient maintains excellent clinical results and no haematological alterations with this treatment.

Finally, we can state that using a compressive aid when the edematous phase is still present can be an additional therapy, added to the systemic one, which has almost no side effects but seems very effective in swelling control.



**Figure 1.** A) Deep skin biopsy of the arm reaching the muscular tissue showing eosinophilic infiltrate and edema in the dermis and hypodermic tissue reaching the fascia E&H 5× stain 5×; B) magnetic resonance image axial projection showing oedema with inflammation and thickening of the muscular fasciae and hypodermic tissue.



**Figure 2.** A) Patient's right arm. Note the arm size, which was more than twice the contralateral, causing the patient difficulties in flexing the arm and swelling, with the appearance of orange peel skin; B) patient after six months of treatment with methotrexate and the use of the elastic compression device. Note the significant reduction in the volume of the affected arm and the skin appearance, now much more similar than the unaffected one.

## References

1. Lebeaux D, Sène D. Eosinophilic fasciitis (Shulman disease). *Best Pract Res Clin Rheumatol* 2012;26:449-58.
2. Long H, Zhang G, Wang L, Lu Q. Eosinophilic skin diseases: a comprehensive review. *Clin Rev Allergy Immunol* 2016;50:189-213.
3. Urzal J, Cimbron M, Mendonça T, Farinha F. Eosinophilic fasciitis (Shulman's disease): review and comparative evaluation of seven patients. *Reumatologia* 2019;57:85-90.
4. Primitivo A, Madeira N, Lopez D, Afonso D. Eosinophilic fasciitis (Shulman disease) with clinical, imaging and pathological correlation. *BMJ Case Rep* 2021;14:e246151.
5. Lakhnpal S, Ginsburg WW, Michet CJ, et al. Eosinophilic fasciitis: clinical spectrum and therapeutic response in 52 cases. *Semin Arthritis Rheum* 1988;17:221-31.
6. Pehl D, Preuße C, Allenbach Y, et al. Eosinophilic fasciitis (Shulman syndrome)-recognition of the histological spectrum allows for new insights into possible pathomechanisms. *Rheumatology (Oxford)* 2023;62:2005-14.
7. Shinozaki A, Hayashi S, Hongo T, et al. Efficacy of methotrexate for steroid-resistant eosinophilic fasciitis with delayed start of treatment: a case report. *Int J Dermatol* 2023;62:e67-8.
8. Mikhal'chik EV, Piterskaya JA, Budkevich LY, et al. Comparative study of cytokine content in the plasma and wound exudate from children with severe burns. *Bull Exp Biol Med* 2009;148:771-5.
9. Saito M, Shima C, Takagi M, et al. Enhanced exudation of fibrinogen into the perivascular space in acute inflammation triggered by neutrophil migration. *Inflamm Res* 2002;51:324-31.
10. Baum SJ, MacVittie TJ, Brandenburg RT, Levin SG. Stimulatory effects of products from inflammatory exudates upon stem cell production. *Exp Hematol* 1978;6:405-9.

Non-commercial use only