

# Combination of intravenous immunoglobulin, oral prednisone, and methotrexate for managing scleromyxedema: case report and literature discussion

Gaia Fasano,<sup>1</sup> Giancarlo Valenti,<sup>2</sup> Domenico D'Amico,<sup>2</sup> Mario Valenti<sup>3,4</sup>

<sup>1</sup>Department of Health Sciences, Magna Graecia University, Catanzaro; <sup>2</sup>Dermatology Unit, Azienda Ospedaliera Pugliese-Ciaccio, Catanzaro; <sup>3</sup>Department of Biomedical Sciences, Humanitas University, Pieve Emanuele (MI); <sup>4</sup>Dermatology Unit, IRCCS Humanitas Research Hospital, Rozzano (MI), Italy

## Abstract

The generalized and sclerodermic form of lichen myxedematosus, known as scleromyxedema (SMX), is a chronic mucinosis that manifests cutaneously and has multiple systemic comorbidities. There are few available treatment options and no established therapeutic guidelines. We describe a 48-year-old man who had intravenous immunoglobulins (IVIg), oral corticosteroids, and methotrexate (MTX) for the treatment of SMX, monoclonal gammopathy, and arthritis. Because of its effectiveness and high level of tolerance, IVIg is the most often used first-line therapy for SMX and has been used for an increasing range of skin conditions. In our instance, better control of skin disease and extracutaneous manifestations was made possible by combining IVIg with oral prednisone and MTX. To the best of our knowledge, this is the first instance of SMX treatment that has combined therapeutic approaches with a favorable safety profile.

## Introduction

Lichen myxedematosus (LM), also called papular mucinosis, is a chronic cutaneous mucinosis characterized by lichenoid papules, nodules, and/or plaques. Mucin deposition and a variable degree of fibrosis are usually localized in the dermis.<sup>1</sup>

LM includes two clinicopathologic subsets: a generalized papular and sclerodermoid form, termed scleromyxedema (SMX) with cutaneous and systemic manifestations, and a localized papular form. It is important to distinguish between localized and generalized forms due to the different management and prognosis.<sup>1</sup>

There are limited data regarding the optimal therapy because of the low number of cases, the lack of randomized trials, and the absence of an understood etiopathogenesis.

We report a case of SMX with monoclonal gammopathy and a prevalent joint involvement that has been successfully treated with intravenous immunoglobulin (IVIg) in combination with oral corticosteroids and MTX.

## Case Report

A 48-year-old man with a background history of hypertension and hepatitis A infection was referred to his primary care physician for smooth papules on his trunk and extremities that have been present for two years.

Physical exams revealed widespread eruption of 2 to 3 mm skin-colored, firm, opalescent, and closed-spaced papules, with surrounding erythematous and indurate skin, on bilateral upper and lower extremities, trunk, peri-umbilical area, ears, dorsal hands, extensor wrists, and dorsal feet with symmetrical pattern (Figure 1). The patient also complained of bilateral joint arthralgia, generalized weakness, and numbness of the hands. Range-of-motion assessment was made difficult by longstanding and generalized peripheral arthritis. No neurological symptoms were found.

Histopathology from a representative lesion on the hands showed atrophic skin with circumscribed mucin deposition in the reticular dermis (demonstrated by alcian blue stain), irregular fibroblast proliferation, and fibrosis, in the absence of inflammatory infiltrate (Figure 2).

Serum protein electrophoresis showed a monoclonal IgG gammopathy with a predominance of kappa light chains. Abnormal investigations included an increment of erythrocyte sedimentation rate (VES) and C-reactive protein (PCR). The abdominal ultrasound was normal. Clinical, laboratory, and pathologic parameters were consistent with a diagnosis of SMX. Topical clobetasol propionate 0.05% cream was initially prescribed daily without benefit. Systemic therapy was carried out with IVIg at the standard dose (2 g per kg per cycle administrated throughout four days). IVIg administration was carried on at a 4-week interval for 6 months with a favorable tolerability profile and a noticeable

Correspondence: Mario Valenti, Department of Biomedical Sciences, Humanitas University, Pieve Emanuele (MI), Italy.  
E-mail: mario.valenti@hunimed.eu

Contributions: the authors contributed equally.

Conflict of interest: the authors declare no potential conflict of interest.

Funding: none.

Consent for publication: the patient gave his written consent for the publication of this case report and any accompanying images.

Received: 16 July 2023.

Accepted: 23 July 2023.

This work is licensed under a Creative Commons Attribution-NonCommercial 4.0 International License (CC BY-NC 4.0).

©Copyright: the Author(s), 2023

Licensee PAGEPress, Italy

Dermatology Reports 2024; 16:9803

doi:10.4081/dr.2023.9803

*Publisher's note: all claims expressed in this article are solely those of the authors and do not necessarily represent those of their affiliated organizations, or those of the publisher, the editors and the reviewers. Any product that may be evaluated in this article or claim that may be made by its manufacturer is not guaranteed or endorsed by the publisher.*

improvement of the skin manifestations (Figure 3). Persistence of arthralgia and articular symptoms continued to be reported, therefore, systemic glucocorticoids (prednisone 0.5-1 mg/kg/day) and methotrexate (15 mg subcutaneous injection once a week) with folic acid (one 5 mg tab the day after methotrexate administration) were used together with IVIg to enhance response.

Skin and joint symptoms had a progressive improvement during the 6 months of therapy. Indices of serum inflammation (VES, PCR) went back within normal limits and the monoclonal gammopathy gradually improved.

No drug reactions or other side effects were reported during the treatment period. Long-term IVIg treatment probably will be necessary due to frequent relapses after cessation reported in the literature.<sup>2</sup>

## Discussion

Mucinosis is a heterogeneous group of diseases characterized by mucin deposition in organs or tissues.<sup>3</sup>

Mucin is a glycoprotein composed of acid glycosaminoglycans produced by fibroblasts. It is usually found in the papillary dermis, around the vessels, and appendages. Excessive deposition of mucin in the dermis gives the skin a loss of elasticity and a fibrotic appearance. Over the years, skin stiffening can progress and may reduce joint motility.<sup>4</sup>

The exact etiology of mucin accumulation has yet to be elucidated but the main hypothesis is that circulating cytokines such as interleukin (IL)-1, tumor necrosis factor (TNF)- $\alpha$  and transforming growth factor (TGF)- $\beta$  stimulate glycosaminoglycan synthesis and fibroblast proliferation. Bone marrow may be a source of circulating cytokines.<sup>5</sup>

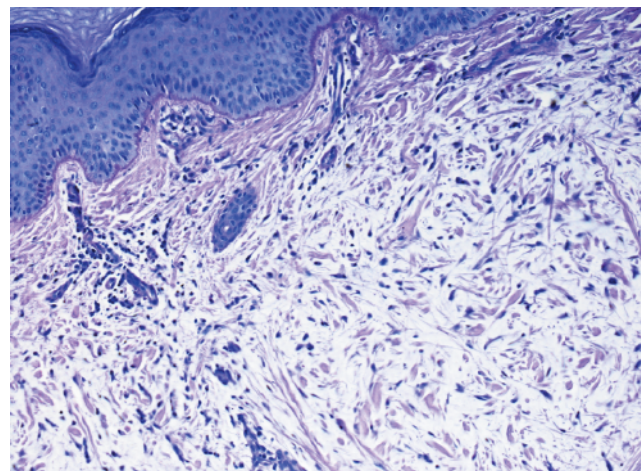
SMX can affect numerous internal organs in addition to the skin with a variable degree of fibrosis.<sup>5</sup> The most frequent association is with monoclonal gammopathy, but paraprotein levels do not correlate with the disease stage, progression, or response to treatment. Additional extracutaneous manifestations include neurological involvement with Alzheimer's symptoms or peripheral neuropathy, joint involvement with arthralgias/arthritis, cardiac symptoms (ischemia, cardiomyopathy), muscle involvement such as myositis and fibromyalgia, respiratory symptoms such as lung fibrosis, gastrointestinal implications with reduced esophageal motility, ocular involvement with macular edema and others such as Raynaud's phenomenon or Sjogren's syndrome.<sup>6-9</sup> SMX has been also associated with an increased risk of developing hematological malignancies.<sup>6</sup>

The diagnosis of SMX is based upon the recognition of the following clinicopathological criteria:<sup>10,11</sup> i) microscopic triad (mucin deposition, fibrosis, irregular fibroblast proliferation); ii) monoclonal gammopathy; iii) absence of thyroid disorder.

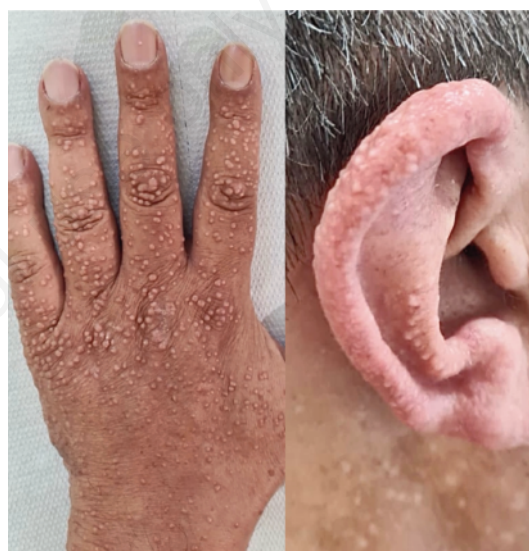There is no specific and definitive treatment due to the limited number of cases, the lack of randomized trials, and the absence of a precise etiopathogenetic hypothesis.

A variety of therapies have been reported, most of which are associated with serious potential side effects and relapses such as thalidomide, melphalan, bortezomib, and autologous stem cell transplantation.<sup>11</sup> Systemic therapy with intravenous immunoglobulin (IVIg) is the most used SMX therapy.<sup>11</sup> Several case reports outline the safety profile and improvement of cutaneous and extracutaneous manifestations of SMX during therapy.<sup>12-14</sup>

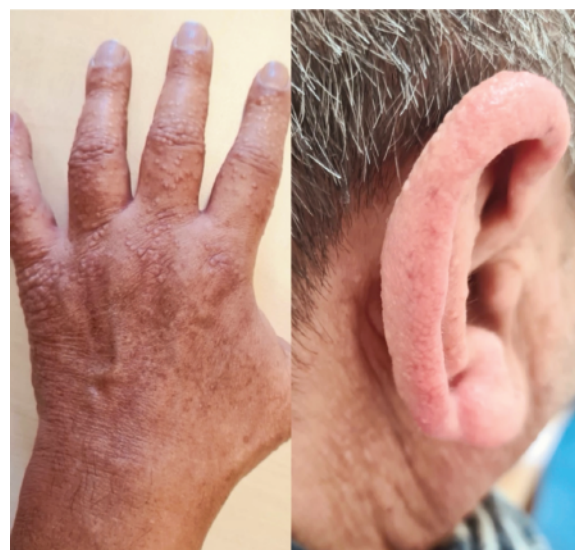The mechanism of action of IVIg is still unknown. An immunomodulatory action including neutralization of circulating autoantibodies by anti-idiotypic antibodies, clearance of circulating immune complexes, regulation of cellular immune responses,



**Figure 1.** Histological picture of skin biopsy that shows mucin deposition in the red circled area (Periodic acid-Schiff 10x).



**Figure 2.** Smooth papules of left dorsal hand prior to the therapy.



**Figure 3.** Clinical improvement after 6 months of therapy.



and modulation of the production of cytokines such as IL-1, TNF, and TGF- $\beta$ , which stimulate glycosaminoglycan synthesis and fibroblast proliferation, have been suggested.<sup>15</sup> Paraproteins themselves could act as stimulators for fibroblasts to proliferate and mucin production, although paraprotein levels did not correlate with disease severity and progression.<sup>16</sup>

The recommended standard dose of IVIg is 2 g per kg of body weight per cycle divided over four/five days. The elimination half-life of IVIg is 21 days, therefore the cycles should be repeated with a minimum of 4 weeks of intervals. The most common side effects (10% of patients) include nausea, headache, fatigue, and infusion reactions. To optimize tolerance and reduce these mild side effects, patients should improve hydration, the infusion speed should be adjusted and co-therapy with antihistamines and corticosteroids should be introduced, prior to treatment. Rare side effects include thrombosis, embolism, pulmonary edema, cardiac toxicity, renal failure, anaphylactic reactions, and meningitis.<sup>17</sup> Oral systemic glucocorticoids such as prednisone (0.5-1 mg/kg/day), prednisolone (0.3-0.5 mg/kg/day), and oral high-dose dexamethasone (40 mg once daily for 4 days per week during 3 consecutive weeks each month) are used for SMX as monotherapy or in combination with other agents. They are supposed to reduce paraprotein production and have an immunosuppressive and anti-fibroblastic effect.<sup>18</sup> The combination of oral prednisone and IVIg has also been successfully used by Majeski *et al.*,<sup>12</sup> but this case was complicated by insulin-dependent diabetes and a fatal cerebrovascular accident, probably related to her disease. Mehta *et al.*<sup>19</sup> reported a successful response of SMX to treatment with steroid mini pulse and methotrexate. The combination of betamethasone dipropionate (5 mg intramuscular per month) and methotrexate (7.5 mg/week) for SMX treatment was successfully used by Xu *et al.* in a patient with SMX without paraproteinaemia.<sup>18</sup> Next-line options, when IVIg therapy is contraindicated or yields insufficient response, are thalidomide, lenalidomide, melphalan, bortezomib.<sup>20</sup> When therapy is successful, long-term maintenance therapy is often required to reduce relapses that can commonly occur after discontinuation.<sup>14</sup>

## Conclusions

SMX is an unpredictable disease with different and severe systemic manifestations, even after several years, which can lead to death. Therefore, close surveillance is mandatory because spontaneous resolution does not occur.<sup>6</sup> There are no definitive therapeutic guidelines. IVIg is an effective and safe treatment for the cutaneous and extra-cutaneous manifestation of SMX with temporary efficacy. Even when therapy is successful, relapse commonly occurs upon the discontinuation of treatment, and long-term maintenance infusions every 6-8 weeks are generally required.<sup>14</sup> Joint symptoms may sometimes be resistant to IVIg therapy, therefore, as our case report shows, other therapies such as oral corticosteroid and methotrexate with folic acid can be combined to manage skin disease and extra-cutaneous symptoms. Moreover, no side effects were reported in our experience. Long-term, double-blind, controlled clinical trials and a better understanding of the complex mechanism of IVIGs immunomodulation are needed to ultimately optimize the dosage, frequency, duration, and mode of administration.

## References

- Rongioletti F. Lichen myxedematosus (papular mucinosis): new concepts and perspectives for an old disease. *Semin Cutan Med Surg* 2006;25:100-4.
- Caudill L, Howell E. Scleromyxedema: a case clinically and histologically responsive to intravenous immunoglobulin. *J Clin Aesthet Dermatol* 2014;7:45-7.
- Edward M, Fitzgerald L, Thind C, et al. Cutaneous mucinosis associated with dermatomyositis and nephrogenic fibrosing dermopathy: fibroblast hyaluronan synthesis and the effect of patient serum. *Br J Dermatol* 2007;156:473-9.
- Cárdenas-Gonzalez RE, Ruelas MEH, Candiani JO. Lichen myxedematosus: a rare group of cutaneous mucinosis. *An Bras Dermatol* 2019;94:462-9.
- Kreuter A, Stücker M, Kolios AG, et al. Skleromyxödem. Eine chronisch progressive Systemerkrankung [Scleromyxedema. A chronic progressive systemic disease]. *Z Rheumatol* 2012;71:504-14.
- Rongioletti F, Merlo G, Cinotti E, et al. Scleromyxedema: a multicenter study of characteristics, comorbidities, course, and therapy in 30 patients. *J Am Acad Dermatol* 2013;69:66-72.
- Sáez-Rodríguez M, García-Bustinduy M, López-Alba A, et al. Localized lichen myxoedematosus (papular mucinosis) associated with morbid obesity: report of two cases. *Br J Dermatol* 2003;148:165-8.
- Rongioletti F, Parodi A, Rebora A. Papular and nodular mucinosis as a sign of lupus erythematosus. *Dermatologica* 1990;180:221-3.
- Wong RX, Chia JC, Haber RM. Review of primary cutaneous mucinosis in nonlupus connective tissue diseases. *J Cutan Med Surg* 2018;22:65-70.
- Rongioletti F, Rebora A. Cutaneous mucinosis: microscopic criteria for diagnosis. *Am J Dermatopathol* 2001;23:257-67.
- Knobler R, Moizadeh P, Hunzelmann N, et al. European dermatology forum S1-guideline on the diagnosis and treatment of sclerosing diseases of the skin, Part 2: Scleromyxedema, scleroderma and nephrogenic systemic fibrosis. *J Eur Acad Dermatol Venereol* 2017;31:1581-94.
- Majeski C, Taher M, Grewal P, et al. Combination oral prednisone and intravenous immunoglobulin in the treatment of scleromyxedema. *J Cutan Med Surg* 2005;9:99-104.
- Kim S, Park TH, Lee SM, et al. Scleromyxedema with multiple systemic involvement: Successful treatment with intravenous immunoglobulin. *Dermatol Ther* 2020;33:e13378.
- Bidier M, Zschoche C, Gholam P, et al. Scleromyxoedema: clinical follow-up after successful treatment with high-dose immunoglobulins reveals different long-term outcomes. *Acta Derm Venereol* 2012;92:408-9.
- Samuelsson A, Towers TL, Ravetch JV. Anti-inflammatory activity of IVIG mediated through the inhibitory Fc receptor. *Science* 2001;291:484-6.
- Cokonis Georgakis CD, Falasca G, et al. Scleromyxedema. *Clin Dermatol* 2006;24:493-7.
- Biniha MP, Nandakumar G, Thomas D. Suspected cardiac toxicity to intravenous immunoglobulin used for treatment of scleromyxedema. *Indian J Dermatol Venereol Leprol* 2008;74:248-50.
- Xu XL, Wu Q, Zeng XS, Sun JF. Combination of betamethasone and methotrexate for the treatment of scleromyxoedema without paraproteinaemia. *Eur J Dermatol* 2016;26:391-3.
- Mehta V, Balachandran C, Rao R. Arndt Gottron scleromyxedema: successful response to treatment with steroid minipulse and methotrexate. *Indian J Dermatol* 2009;54:193-5.
- Efthimiou P, Blanco M. Intravenous gammaglobulin and thalidomide may be an effective therapeutic combination in refractory scleromyxedema: case report and discussion of the literature. *Semin Arthritis Rheum* 2008;38:188-94.