

Deep mycosis mimicking cutaneous squamous cell carcinoma

Fortunato Cassalia,¹ Francesco Gratteri,¹ Leonardo Azzi,¹ Anna L. Tosi,² Mauro Giordani³

¹UOC Dermatology, Department of Medicine, University of Padua; ²UOC Pathological Anatomy, Department of Diagnosis and Treatment, Rovigo Hospital; ³UOSD Dermatology, Department of Medicine, Rovigo Hospital, Italy

Abstract

Deep cutaneous mycoses (DCMs) and skin fungal infections can cause significant morbidity until diagnosed and treated. In immunocompromised people, *Candida* spp., *Aspergillus* spp., and *Fusarium* spp. fungi can cause these infections, but dermatophytes, especially *Trichophyton rubrum* and *T. mentagrophytes*, are the most common. Superficial erythematous lesions become firm subcutaneous nodules, ulcers, abscesses, or sinus tracts. In advanced cases, DCMs can cause osteomyelitis and bone loss. DCM included mycetoma, a chronic infectious disease of the skin, subcutaneous tissues, and bones. In some areas, it is endemic and can mimic cutaneous tuberculosis or cancerous lesions, making diagnosis difficult. Clinical presentation, radiological findings, and microbiological culture are used to diagnose with molecular methods helping in culture-negative cases. An immunocompetent

farmer with a wrist lesion initially suspected as cutaneous squamous cell carcinoma was histologically diagnosed as eumycetoma, emphasizing the importance of considering deep mycoses in high-risk individuals and their heterogeneous clinical presentation.

Introduction

Deep cutaneous mycoses (DCMs) are fungal infections that affect the skin and its deeper layers, including subcutaneous tissue, muscles, and bones. While relatively rare, they can cause significant morbidity if not promptly diagnosed and treated. The most common cause of DCMs is dermatophytes, with *Trichophyton rubrum* and *Trichophyton mentagrophytes* being the most common causative agents. Other fungi, including *Candida* spp., *Aspergillus* spp., and *Fusarium* spp., can also cause DCMs, particularly in immunocompromised patients. The clinical presentation of DCMs can vary widely depending on the depth and extent of the infection. Superficial infections typically present as erythematous, scaly lesions that may be pruritic. In contrast, DCMs can cause firm, subcutaneous nodules, ulcers, abscesses, or sinus tracts. The skin overlying the infected area may be warm, tender, and erythematous.¹

In advanced cases, the infection can spread to the bones and cause osteomyelitis, which can lead to bone destruction and deformity. Deep skin mycoses include the so-called “mycetoma”, a rare chronic infectious disease of the skin and subcutis caused by fungi (eu-mycetoma) or bacteria (actin-mycetoma).

Mycetoma is a chronic and disabling infectious disease that affects the skin, subcutaneous tissues, and bones and it is endemic in regions of the “mycetal belt”, including Africa, South America, and South Asia, while it is rare in the United States and in our latitudes.² Mycetoma presents clinically as a painful, often suppurated swelling that usually affects the distal extremities of the lower limbs and rarely may affect the upper limbs and face. Infection can often develop following penetrating trauma caused, for example, by plant thorns, wood splinters, animal bites, or contaminated organic material.³ The complex nature of the disease and the lack of diagnostic tools often make it difficult to distinguish mycetoma from other diseases that may present similar symptoms and the differential diagnosis of mycetoma includes cutaneous tuberculosis or cutaneous sarcoidosis; sometimes it may mimic cancerous lesions such as basal cell carcinoma, squamous cell carcinoma, amelanotic melanoma, or cutaneous metastases.⁴ Mycetoma is typically diagnosed based on clinical presentation, radiological findings, and microbiological culture. Definitive diagnosis requires the help of granulometric examination, microscopy, imaging (radiography, ultrasound, magnetic resonance imaging) and culture and, in some cases, new molecular methods such as polymerase chain reaction and molecular sequencing. Molecular sequencing for fungi and bacteria is important for rapid and correct diagnosis, especially in culture-negative cases. Treatment of mycetoma is challenging and requires prolonged and aggressive therapy, which may involve surgical debridement, antifungal

Correspondence: Fortunato Cassalia, UOC Dermatology, Department of Medicine, University of Padua, via Vincenzo Gallucci 4, 35121, Padua, Italy.
Tel.: +39.3474833875.
E-mail: fortunato1287@gmail.com

Key words: deep mycosis; cutaneous mycosis; mycetoma.

Contributions: the authors contributed equally.

Conflict of interest: the authors declare no potential conflict of interest.

Funding: none.

Availability of data and materials: data and materials are available from the corresponding author upon request.

Consent for publication: the patient gave informed consent for the publication of their case details.

Received: 25 June 2023.

Accepted: 1 July 2023.

This work is licensed under a Creative Commons Attribution-NonCommercial 4.0 International License (CC BY-NC 4.0).

©Copyright: the Author(s), 2023

Licensee PAGEPress, Italy

Dermatology Reports 2024; 16:9782

doi:10.4081/dr.2023.9782

Publisher's note: all claims expressed in this article are solely those of the authors and do not necessarily represent those of their affiliated organizations, or those of the publisher, the editors and the reviewers. Any product that may be evaluated in this article or claim that may be made by its manufacturer is not guaranteed or endorsed by the publisher.

and/or antibiotic therapy, and sometimes, amputation, and rehabilitation.⁵ However, the success of treatment depends on various factors, including the duration of the disease, the extent of tissue involvement, and the causative agent. Prevention of mycetoma involves improving hygiene and living conditions, as well as raising awareness among communities about the disease and its risk factors. In addition, early diagnosis is crucial in preventing disease progression and reducing the risk of complications and it is important to take preventive measures such as wearing protective clothing and shoes especially during risky activities.⁶

Case Report

A 77-year-old immunocompetent man, a farmer and rancher in close contact with livestock, came to our hospital complaining of a left wrist injury of about 4×5 cm that arose several months ago. Clinical examination revealed a painful, erythematous, crusted plaque with central ulcerated areas on the dorsal side of the distal third of the left forearm (Figure 1). Dermoscopy revealed irregular linear vessels, hairpin vessels, and developed glomerular vessels on a whitish background with an ulcerated central area.

On history, hypertension was reported, and no previous dermatologic diseases were reported. The clinical and dermatoscopic picture and personal history of significant sun exposure placed the diagnosis suspect of cutaneous squamous cell carcinoma.⁷ The size of the skin lesion would have required demolition surgery; therefore, it was decided to perform an incisional biopsy to ascertain the malignant nature of the lesion. Surprisingly, the outcome of the skin biopsy showed a picture of hyperkeratosis, dyselastosis, and pseudoepitheliomatous hyperplasia with focally ascending chronic and acute inflammation at the dermis level in the presence of fungal spores. Therefore, the diagnosis of eumycetoma was placed. Topical antifungal therapy was imposed with eosin to be applied twice daily and oral therapy with itraconazole 100 mg tablets to be taken twice daily for two weeks.⁸ The patient returned for follow-up after one month with substantial improvement in the skin picture.

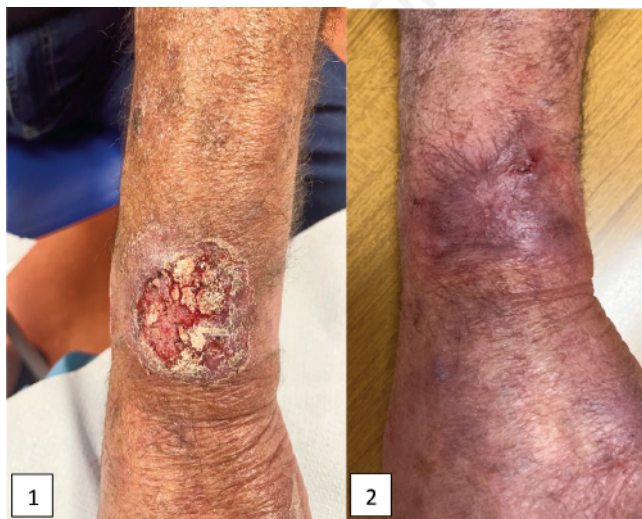


Figure 1. Erythematous, crusted plaque with central ulcerated areas before (1) and after (2) treatment.

Discussion and Conclusions

The clinical and dermatoscopic appearance depicted the diagnosis of cutaneous squamous cell carcinoma; however, histologic examination revealed that the skin disease was characterized by thickening of the outer layer of the skin (hyperkeratosis), damage to the elastic fibers of the skin (dyselastosis), and abnormal growth of skin cancer-like tissue (pseudoepitheliomatous hyperplasia) with atypical cells that are probably due to chronic and acute inflammation with abscess formation in the deeper layer of the skin (dermis) (Figure 2). However, the presence of fungal spores in the deeper layer of the skin allowed us to make the correct diagnosis of mycetoma and direct the course of treatment in the correct way (Figure 3).

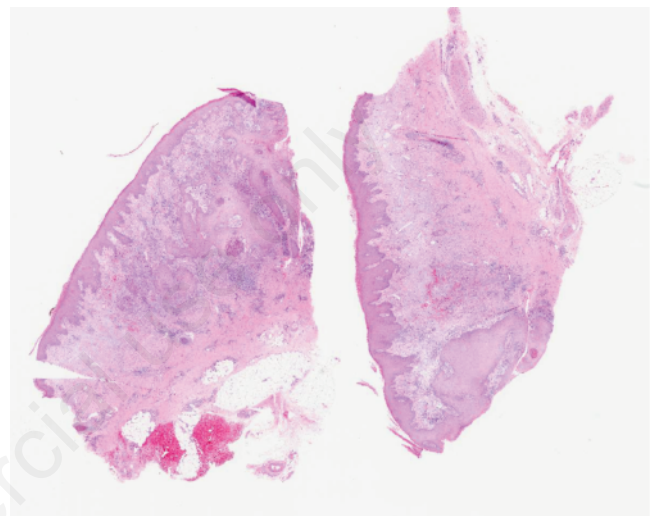


Figure 2. The skin condition is characterized by thickening of the outer layer of the skin (hyperkeratosis), damage to the elastic fibers of the skin (dyselastosis), and abnormal growth of tissue resembling skin cancer (pseudoepitheliomatous hyperplasia) with atypical cells that are likely due to chronic and acute inflammation resulting in abscess formation in the deeper layer of the skin (dermis) where fungal spores are present. This is likely a reactive response to the fungal infection.

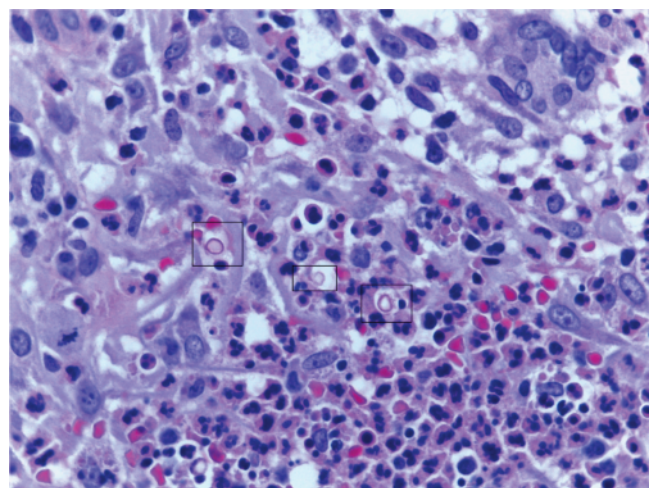


Figure 3. Periodic acid-Schiff staining 60× magnification: three deep spores are evident (circled).

The described clinical case highlights the heterogeneous clinical presentation of deep mycoses, the importance of correct collection of the patient's medical history, and the need to consider deep mycoses among the possible differential diagnoses in immunocompetent patients performing risky jobs or activities.

References

1. Guégan S, Lanternier F, Rouzaud C, et al. Fungal skin and soft tissue infections. *Curr Opin Infect Dis* 2016;29:124-30.
2. Carrasco-Zuber JE, Navarrete-Dechent C, Bonifaz A, et al. Cutaneous involvement in the deep mycoses: a literature review. Part i-subcutaneous mycoses. *Actas Dermosifiliogr* 2016;107:806-15.
3. Fahal AH, Suliman SH, Hay R. Mycetoma: the spectrum of clinical presentation. *Trop Med Infect Dis* 2018;3:97.
4. Emmanuel P, Dumre SP, John S, et al. Mycetoma: a clinical dilemma in resource limited settings. *Ann Clin Microbiol Antimicrob* 2018;17:35.
5. Relhan V, Mahajan K, Agarwal P, Garg VK. Mycetoma: an update. *Indian J Dermatol* 2017;62:332-40.
6. Verma P, Jha A. Mycetoma: reviewing a neglected disease. *Clin Exp Dermatol* 2019;44:123-9.
7. Weber P, Tschandl P, Sinz C, Kittler H. Dermatoscopy of neoplastic skin lesions: recent advances, updates, and revisions. *Curr Treat Options Oncol* 2018;19:56.
8. Develoux M. Les mycétomes et leur traitement [Mycetoma and their treatment]. *J Mycol Med* 2016;26:77-85.

Non-commercial use only