

Hydroxychloroquine-induced generalized myopathy in a patient with lupus tumidus: a case report

Alice Verdelli,¹ Daniela Massi,² Vincenza Maio,² Gabriele Cavazza,³ Alberto Corrà,¹ Elena Biancamaria Mariotti,³ Lavinia Quintarelli,¹ Valentina Ruffo di Calabria,³ Cristina Aimo,³ Emiliano Antiga,³ Marzia Caproni^{1,3}

¹Rare Dermatological Diseases Unit, Department of Health Sciences, Toscana Centro Local Health Unit, Florence; European Reference Network Skin Member; ²Section of Pathology and ³Section of Dermatology, Department of Health Sciences, University of Florence, Italy

Abstract

A subtype of cutaneous lupus erythematosus known as lupus erythematosus tumidus (LET) is characterized by sun-exposed areas that typically display urticaria-like papules and plaques. For LET, systemic therapy with antimalarials – particularly hydroxychloroquine (HCQ) – is the first line of treatment. Even

though the safety profile of these medications appears to be high, there have been very few reports of side effects in the literature, including hemolytic anemia, retinal toxicity, maculopapular rash, gastrointestinal disturbance, and blue-gray discoloration of the skin or mucous membranes. Here, we report a unique instance of a 46-year-old LET smoker who, following HCQ treatment, developed a generalized myopathy.

Correspondence: Alice Verdelli, Rare Dermatological Diseases Unit, Department of Health Sciences, Azienda USL Toscana Centro, Florence, Italy.
E-mail: alice.verdelli@hotmail.it

Key words: cutaneous lupus erythematosus; lupus tumidus; hydroxychloroquine-induced myopathy; drug reaction; tacrolimus ointment.

Contributions: all the authors contributed equally.

Conflict of interest: the authors declare no potential conflict of interest.

Funding: none.

Ethical approval and consent to participate: the authors confirm that they have read the Journal's guidelines regarding ethical publication and affirm that this report is consistent with those.

Availability of data and materials: data and materials are available by the authors.

Consent for publication: the patient gave her written consent to use his personal data for the publication of this case report and any accompanying images.

Received: 15 June 2023.

Accepted: 23 July 2023.

This work is licensed under a Creative Commons Attribution-NonCommercial 4.0 International License (CC BY-NC 4.0).

©Copyright: the Author(s), 2023
Licensee PAGEPress, Italy
Dermatology Reports 2024; 16:9771
doi:10.4081/dr.2023.9771

Publisher's note: all claims expressed in this article are solely those of the authors and do not necessarily represent those of their affiliated organizations, or those of the publisher, the editors and the reviewers. Any product that may be evaluated in this article or claim that may be made by its manufacturer is not guaranteed or endorsed by the publisher.

Introduction

Lupus erythematosus tumidus (LET), or intermittent lupus, is an uncommon and photosensitive inflammatory skin disorder characterized by erythematous urticarial plaques mainly located on sun-exposed areas.¹ LET is included in the classification of cutaneous lupus erythematosus (CLE) even if it can be well differentiated, both clinically and histologically, from the most common forms of CLE.²

Singular lesions, that quickly respond to topical therapies, may not need any further treatment. However, skin lesions may show an intermittent course with relapsing lesions after disease-free periods and can also display long-term remission, thus systemic treatments are frequently used.³

Antimalarials, especially hydroxychloroquine (HCQ), are the first-line systemic therapy for LET⁴ according to the guideline for treatment of cutaneous lupus erythematosus - guided by the European Dermatology Forum in cooperation with the European Academy of Dermatology and Venereology [J Eur Acad Dermatol Venereol. 2017;31:389-404].

Their safe profile makes the decision for a systemic therapy easier, especially in frequently relapsing or refractory form. Rare side effects include retinal toxicity, maculopapular rash, gastrointestinal symptoms, hemolytic anemia and blue-gray discoloration of the skin or the mucous membranes.⁵ Herein, we report a case of LET who developed an adverse reaction, represented by a generalized myopathy, after HCQ treatment. The topical use of calcineurin inhibitors as well as the cessation of smoking cleared skin lesions.

Case Report

A 46-year-old strong smoking woman presented with erythematous infiltrated annular plaques with pasty consistency, involving the face, the neck and the upper part of the trunk (Figure 1A-C). Lesions had appeared after sun exposure four months before. The patient was otherwise healthy and did not take any drugs. A biopsy specimen showed perivascular and periannexial lymphohistiocytic infiltrates in the superficial and deep dermis with mucin deposits in the dermis at Alcian blue staining (Figure 2). No epidermal changes were found. Blood examinations revealed anti-

nuclear antibodies (ANA) positivity (1:320) and anti-Ro/SSA antibody positivity (+++). All the other values were within the normal limits.

According to skin morphology and histopathology, a diagnosis of LET was made. A systemic involvement was excluded according to the new classification criteria for systemic lupus erythematosus (SLICC). After the ophthalmologist evaluation, the patient started HCQ 5 mg/kg daily in association with sun protection and topical treatment with corticosteroids (mometasone furoate cream). We strictly recommended to stop smoking. After two months of treatment, the patient developed generalized weakness. Blood examinations revealed increased levels of creatine kinase (CK) (3350 U/L) and lactate dehydrogenase (LDH) (597 U/L). Electromyography showed a widespread increase in polyphasic motor unit potentials, consistent with myopathy. HCQ was discontinued, monitoring the patient with blood examinations every three weeks. CK and LDH promptly decreased, reaching normal values after six weeks. Since cutaneous lesions were still present, a short course of systemic corticosteroids was added, without improvement. Accordingly, methotrexate 7.5 mg/weekly was introduced. After a few weeks of treatment, it was discontinued due to increased levels of transaminases (aspartate transaminase 100 U/L and alanine transaminase 148 U/L). We decided to continue

only topical treatment with calcineurin inhibitors (0.1% tacrolimus ointment) twice a day. At the same time, the patient had stopped smoking. Lesions completely cleared after six months of treatment, without any reactivation in a six-month follow-up period (Figure 1D).

Discussion

LET is a subtype of CLE characterized by erythematous, succulent, urticarial-like, non-scarring plaques in sun-exposed areas. In a few cases, there is a tendency for the skin lesions to coalesce in the periphery and to produce a gyrate or annular configuration, imitating the annular type of subacute CLE (SCLE).¹ Most patients with LET show complete resolution of skin lesions without residual hypopigmentation. Histopathologically, in contrast to SCLE, epidermal changes such as follicular hyperkeratosis, epidermal atrophy, vacuolar degeneration or basal membrane thickening are absent.¹ Association of LET with positive ANA has been demonstrated in 4-40% of cases while anti-Ro positivity in 5% of patients.¹

The case reported is unusual for several reasons. Firstly, even if LET usually has an intermittent course with relapsing lesions after disease-free periods, our patient showed a long-term course,

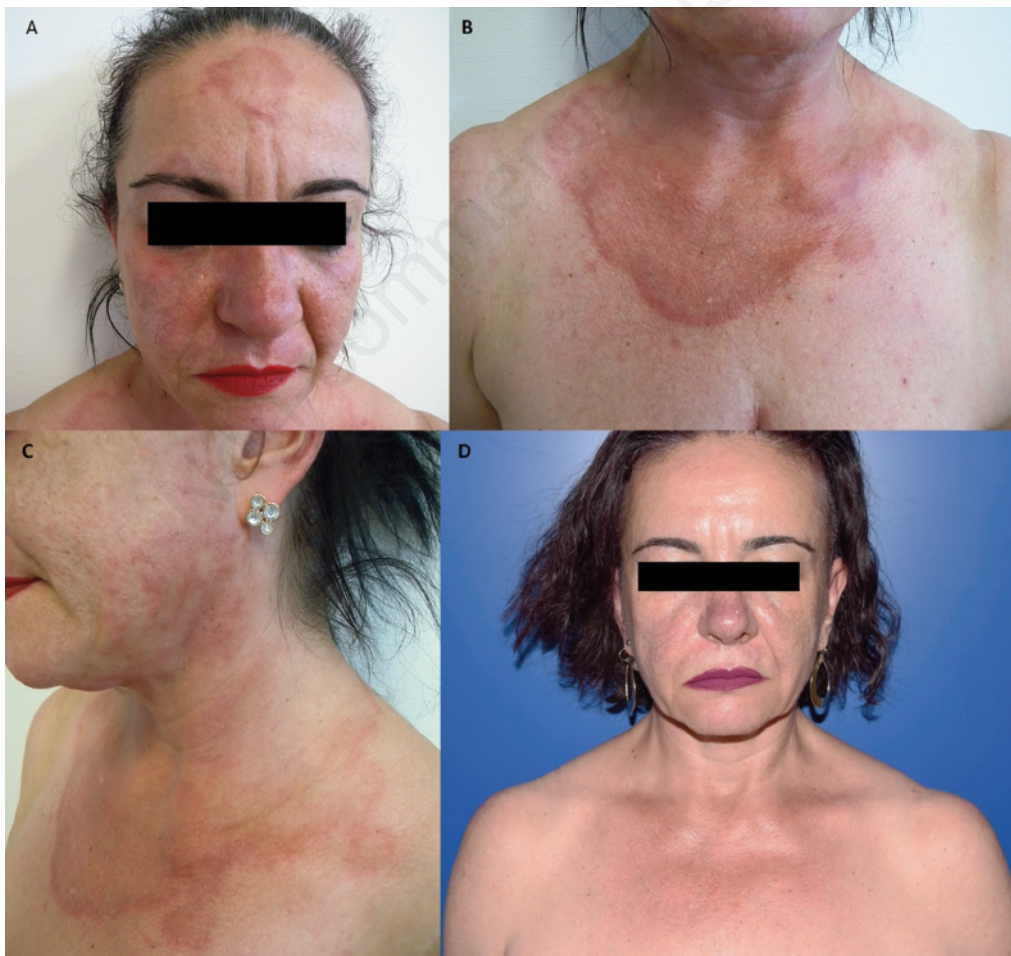

Figure 1. A-C) Erythematous infiltrated annular plaques with pasty consistency, involving the face, neck, and upper part of the trunk; D) resolution of skin lesions after calcineurin inhibitors (0.1% tacrolimus ointment) topical treatment.

with stable lesions for several months. Smoking may have been an aggravating factor in this case.

Secondly, most of the LET resolves with antimalarial treatment without adverse reactions. By contrast, our patient developed several drug reactions, including myalgias after HCQ treatment and hypertransaminasemia after methotrexate treatment.

The toxicity from HCQ use, especially retinotoxicity, has been recognized and described in literature,⁵ while HCQ-induced myopathy has been rarely described.⁶⁻⁸

Antimalarials-induced myopathy has a reported incidence of 2 to 10 cases in 1000 patients/year and a prevalence of less than 2%. Little is known about its pathogenesis. Risk factors for myotoxicity are poorly understood but may include Caucasian race, renal failure, and concomitant use of other myotoxic drugs.⁹

HCQ myopathy usually presents with nonspecific mild to moderate proximal muscle weakness with CK levels that are normal or mildly elevated. Thus, the diagnosis may be difficult, especially in patients with other medical conditions that predispose to myopathy, such as connective tissue diseases.⁸ An electromyogram suggests a toxic myopathy when myotonic discharges are present diffusely in addition to short-duration motor unit potentials, but this finding is not specific. Histopathologic evaluation of a muscle biopsy specimen is the definitive diagnostic

tool in patients with suspected HCQ myopathy.⁹ In our case, the patient refused the procedure. The findings of a vacuolar myopathy with autophagosome-like features of variable severity associated with fiber degeneration/necrosis are typical for HCQ myopathy.⁶

According to these findings, HCQ-induced toxicity should be considered if the patient has a history of HCQ use with underlying rheumatologic disease with evidence of unexplained myopathy such as elevated muscle enzymes, chest pain, generalized or proximal muscle weakness.⁹ Authors also suggested a muscle biopsy to confirm the diagnosis.

As recently reported by Fiehn *et al.*,⁵ determination of CK and LDH in blood is appropriate to screen for cardiomyopathy and myopathy before starting HCQ treatment and should be checked every three months during HCQ treatment.

An alternative diagnosis could have been the evolution from CLE to systemic LE (SLE). However, no other systemic signs of SLE could be found and muscle enzymes decreased after HCQ discontinuation, confirming a drug-induced reaction. Moreover, LET has rarely been associated with systemic involvement and many authors consider LET as a skin-limited variant of CLE. In our experience, none of LET patients had a SLE.¹⁰

LET has a multifactorial origin with a possible involvement of ultraviolet, genetics, and environmental conditions all playing a

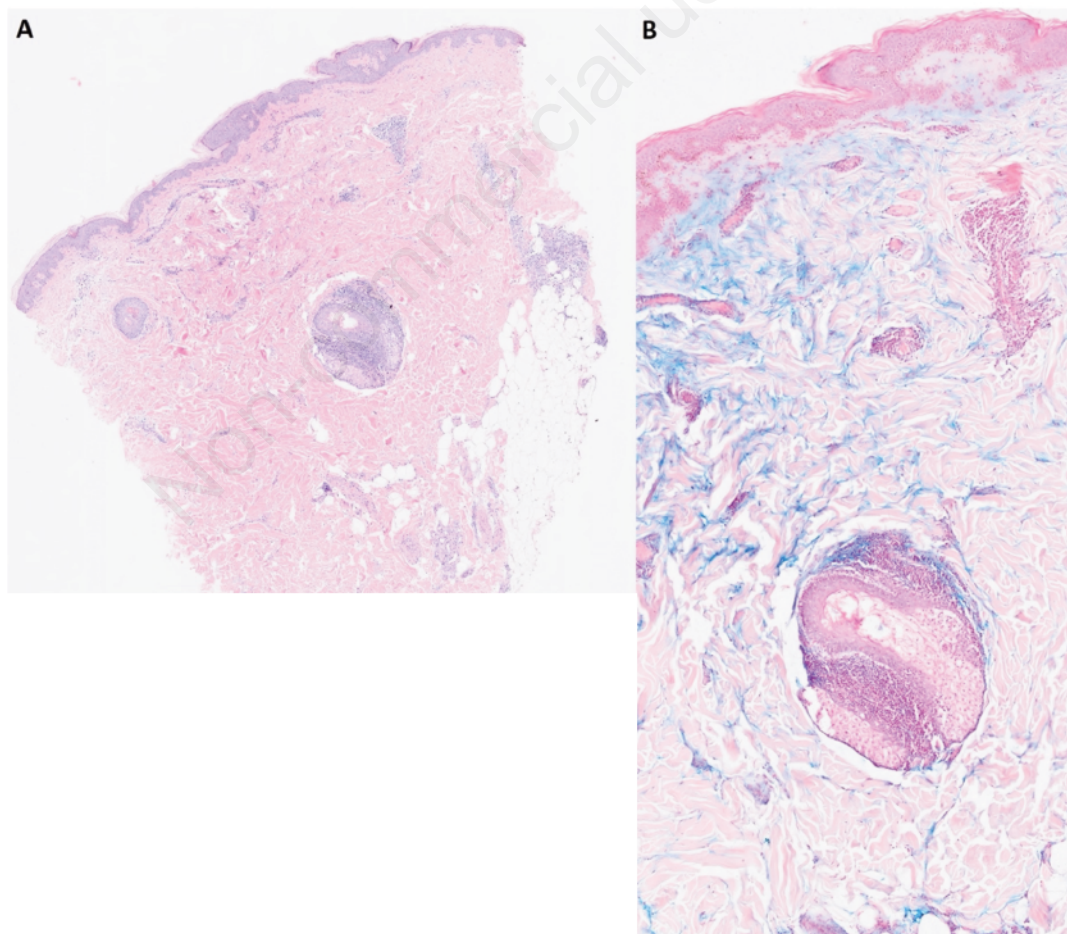


Figure 2. A,B) Trunk lesion showed vacuolar degeneration of the basal layer of keratinocytes, and perivascular and periannexial lymphohistiocytic infiltrate in the superficial and deep dermis. **A)** Hematoxylin-eosin; original magnification, 5x; **B)** mucin deposits in the dermis (Alcian blue staining, 20x).

role in disease pathogenesis. Although smoking seems to have a controversial role in patients with lupus,¹¹ the majority of LET patients are smokers, as our patient was. The cessation of smoking, which we encouraged, may have favored the clearing up of the cutaneous lesions.

Interestingly, our patient's lesions were solved after topical treatment with calcineurin inhibitors only. In CLE guidelines, calcineurin inhibitors (0.1% tacrolimus ointment) are recommended as an alternative first-line or as a second-line topical treatment option in active, oedematous CLE lesions.³ We suggest considering this treatment in LET patients when HCQ is contraindicated since calcineurin inhibitors are safe with no side effects and can be used in association with sun protection for long periods.

Conclusions

To conclude, we report the case of a cutaneous form of lupus, the LET, in which the first line of treatment, *i.e.*, HCQ, 5 mg/kg daily, induced myopathy as an adverse reaction; the second-line systemic treatment, *i.e.*, methotrexate 7.5 mg/weekly, induced a liver reaction but the cessation of smoking together with the topical use of calcineurin inhibitors cleared up the lesions.

References

1. Patsinakidis N, Kautz O, Gibbs BF, Raap U. Lupus erythematosus tumidus: clinical perspectives. *Clin Cosmet Investig Dermatol* 2019;12:707-19.
2. Filotico R, Mastrandrea V. Cutaneous lupus erythematosus:

clinico-pathologic correlation. *G Ital Dermatol Venereol* 2018;153:216-29.

3. Kuhn A, Aberer E, Bata-Csörgő Z, et al. S2k guideline for treatment of cutaneous lupus erythematosus- guided by the European Dermatology Forum (EDF) in cooperation with the European Academy of Dermatology and Venereology (EADV). *J Eur Acad Dermatol Venereol* 2017;31:389-404.
4. Verdelli A, Corrà A, Mariotti EB, et al. An update on the management of refractory cutaneous lupus erythematosus. *Front Med (Lausanne)* 2022;9:941003.
5. Fiehn C, Ness T, Weseloh C, et al. Safety management of the treatment with antimalarial drugs in rheumatology. Interdisciplinary recommendations based on a systematic literature search. *Z Rheumatol* 2020;79:186-94.
6. Khosa S, Khanlou N, Khosa GS, Mishra SK. Hydroxychloroquine-induced autophagic vacuolar myopathy with mitochondrial abnormalities. *Neuropathology* 2018;38:646-52.
7. Doughty CT, Amato AA. Toxic myopathies. *Continuum (Minneapolis)* 2019;25:1712-31
8. Kwon JB, Kleiner A, Ishida K, et al. Hydroxychloroquine-induced myopathy. *J Clin Rheumatol* 2010;16:28-31.
9. Kalajian AH, Callen JP. Myopathy Induced by antimalarial agents: the relevance of screening muscle enzyme levels. *Arch Dermatol* 2009;145:597-600.
10. Verdelli A, Coi A, Marzano AV, et al. Autoantibody profile and clinical patterns in 619 Italian patients with cutaneous lupus erythematosus. *J Eur Acad Dermatol Venereol* 2019;33:742-52.
11. Böckle BC, Sepp NT. Smoking is highly associated with discoid lupus erythematosus and lupus erythematosus tumidus: analysis of 405 patients. *Lupus* 2015;24:669-74.