

# Neutrophilic urticarial dermatosis without systemic disease: case report

Sukaina Al Haddad,<sup>1</sup> Abdulrahman Alfawzan,<sup>2</sup> Maisa Alfalah,<sup>3,4</sup> Manea Alharbi<sup>5</sup>

<sup>1</sup>Division of Dermatology, Security Forces Hospital, Riyadh; <sup>2</sup>Division of Dermatology, Ministry of National Guard Health Affairs, Riyadh; <sup>3</sup>College of Medicine, King Saud Bin Abdulaziz University for Health Sciences; <sup>4</sup>Department of Dermatology, King Abdulaziz Medical City, Riyadh; <sup>5</sup>Dermatology Department Imam Muhammed Bin Saud University, Riyadh, Saudi Arabia

## Abstract

Neutrophilic urticarial dermatosis (NUD) is an uncommon and not well understood disease. We report a 24-year-old female with persistent present with pruritic and painful urticarial plaques unresponsive to conventional treatment. Histopathologically, it

demonstrates a perivascular and interstitial neutrophilic infiltrate with leukocytoclasia without evidence of vasculitis or dermal edema consistent with neutrophilic urticarial dermatosis. Further investigations to rule out underlying autoimmune, autoinflammatory and genetic systemic disease were negative. Furthermore, the cutaneous eruption was resistant to multiple therapeutic interventions including colchicine and dapsone treatment, and show significant response to treatment with anakinra, interleukin-1 receptor antagonist. Based on literature review, the case reported here is the second case with clinical and pathologic features of NUD without systemic disease and the first case of NUD that showed resistant to colchicine and dapsone treatment, with adequate response to anakinra.

Correspondence: Sukaina Al Haddad, Division of Dermatology, Security Forces Hospital, Riyadh, AlHofuf 36364-3809, Kingdom of Saudi Arabia.

Tel.: +966.581753335.

E-mail: Sukaina.Haddad@outlook.sa

Key words: neutrophilic; urticaria; anakinra; neutrophilic urticarial dermatosis.

Contributions: SAH, supervision, and tasks distribution, SAH, AA, Review of literature, authorship of the case report introduction and discussion; MAIf, MAIh, direct patient care, data collection and treatment interventions, authorship of case report including medical history, physical examining, investigation, treatment, and therapeutic outcomes. All the authors approved the final version to be published.

Conflict of interest: the authors declare no potential conflict of interest.

Ethical approval and consent to participate: written consent was obtained from the patient to publish photos and details of the case.

Consent for publication: the authors certify that they have obtained all appropriate patient consent forms. In the form the patient has given her consent for her images and other clinical information to be reported in the journal. The patients understand that their names and initials will not be published, and due efforts will be made to conceal their identity, but anonymity cannot be guaranteed.

Received: 25 May 2023.

Accepted: 12 November 2023.

This work is licensed under a Creative Commons Attribution-NonCommercial 4.0 International License (CC BY-NC 4.0).

©Copyright: the Author(s), 2024

Licensee PAGEPress, Italy

Dermatology Reports 2024; 16:9756

doi:10.4081/dr.2024.9756

*Publisher's note: all claims expressed in this article are solely those of the authors and do not necessarily represent those of their affiliated organizations, or those of the publisher, the editors and the reviewers. Any product that may be evaluated in this article or claim that may be made by its manufacturer is not guaranteed or endorsed by the publisher.*

## Introduction

Neutrophilic urticarial dermatosis (NUD) is an uncommon and poorly understood disease. NUD was first reported in 2009 by Kieffer et al.,<sup>1</sup> who described patients with atypical urticarial eruptions, typically with pruritus and recalcitrance to antihistamine therapy. Histopathologically, it demonstrates a perivascular and interstitial neutrophilic infiltrate with leukocytoclasia, without evidence of vasculitis or dermal edema.<sup>1,2</sup> Earlier reports of NUD were mostly reported in patients with associated systemic conditions, which are predominantly autoimmune or autoinflammatory in nature.<sup>3</sup> Although uncommon, NUD can appear without a specific underlying disease; however, systemic inflammatory markers are usually elevated.<sup>3</sup> Medications that target neutrophils, including colchicine, dapsone, and interleukin-1 receptor antagonists such as anakinra, are suggested therapeutic modalities for affected patients.<sup>4</sup> Based on the literature review, the case reported here is the second with the clinical and pathologic features of NUD without a causal systemic disease.<sup>5</sup>

## Case Report

### History

A 24-year-old female presented with a three-week history of new onset cutaneous eruption localized to the back. The lesions were associated with mild pruritus and a burning sensation. Similar lesions were first noticed five years ago, diagnosed as urticarial vasculitis based on biopsy at another institution, and were resistant to treatment with topical triamcinolone acetonide 0.1% ointment and daily sedating and nonsedating oral antihistamines, including hydroxyzine hydrochloride, loratadine, and doxepin hydrochloride, all of which provided no control of the patient's cutaneous eruption and prurities.

## Physical examination

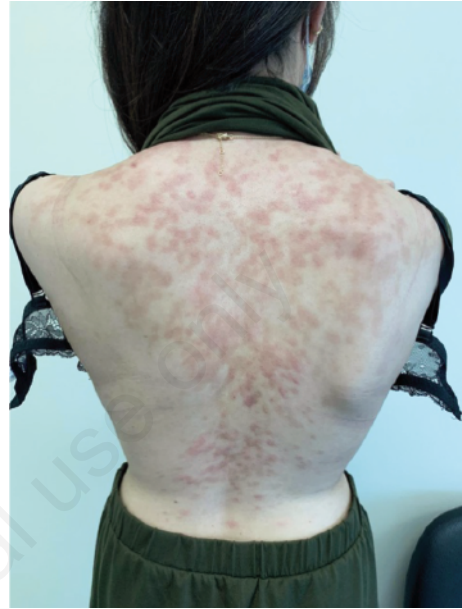
Erythematous plaque with a pale center that coalesces into larger arciform plaques and resolves with hyperpigmented patches in a Christmas tree distribution (Figure 1). The cutaneous eruption was not associated with any other systemic symptoms or signs. Histological examination of the skin punch biopsy revealed that the dermal infiltrate consisted of perivascular, peri adnexal, and interstitial neutrophils with focal leukocytoclasia, without evidence of vasculitis or dermal edema (Figure 2). The results of investigations, including complete blood count, metabolic panel, liver transaminase, ferritin-level antinuclear antibody, erythrocyte sedimentation rate, and C-reactive protein, were all within normal limits. Serum protein electrophoresis and immunofixation electrophoresis were also normal. The result of genetic testing for the mutation of the NLRP3 gene was negative in NUD with cryopyrin-associated periodic syndrome.

## Diagnosis

### *Neutrophilic urticarial dermatosis treatment*

Due to evidence of neutrophilic inflammation, colchicine 1.2 mg daily was prescribed for 4 months, with minimal control of cutaneous eruption. Dapsone 50mg daily was consecutively added to colchicine for 3 mo, but it was stopped due to the appearance of new lesions and the worsening of itchiness. Following this exacerbation, all previous medications were stopped and 100mg of anakinra, an IL-1 receptor antagonist, was administered subcutaneously daily. Within several days, the patient reported a dramatic improvement of her urticarial eruption, with a complete resolution of symptoms within 2 months and no active lesions reported 6 months later.

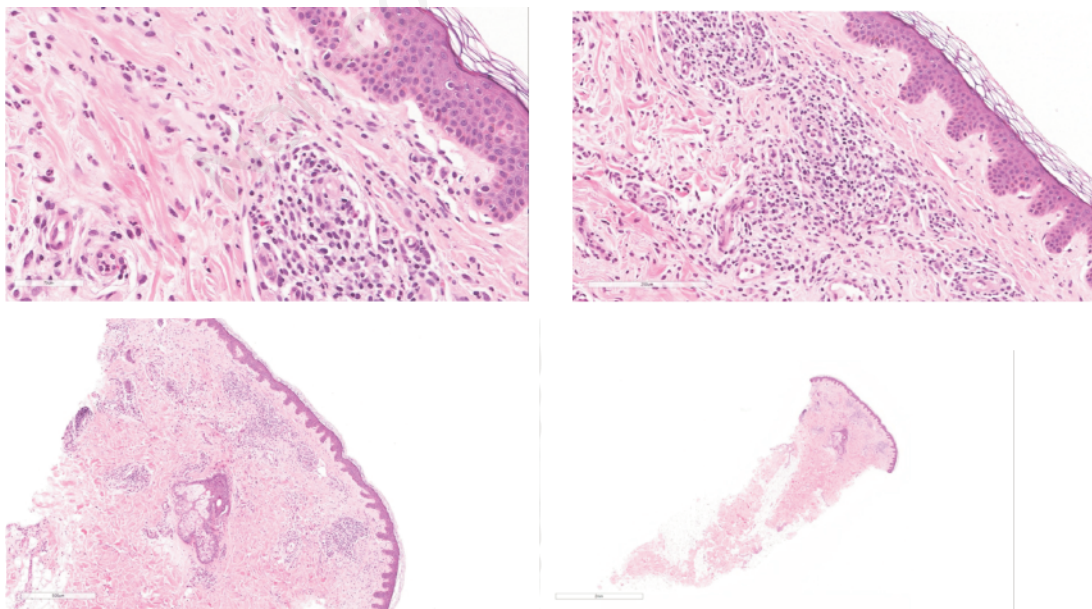
ial lesions was in Dermatopathology textbook published by Montgomery et al. in 1967 and later by Jones et al. in 1983.<sup>2</sup> Neutrophilic urticaria was later defined in 1985 by the presence of neutrophilic infiltrates without vasculitis in 241 biopsies. Thereafter, it was found that NU is likely to be associated with an elevated sedimentation rate and leukocytosis. In 2009, Kieffer et al. defined a designation termed NUD based on a subtype of neutrophilic urticaria characterized by interstitial infiltrates of neutrophils distributed either individually or arranged linearly, with



**Figure 1.** Erythematous plaque with a pale center that coalesces into larger archiform plaques and resolves with hyperpigmented patches in Christmas tree configuration.

## Discussion

The foremost description of neutrophils in biopsies of urticar-



**Figure 2.** Histological examination of skin punch biopsy revealed that dermal infiltrate consists of perivascular, peri adnexal, and interstitial neutrophils with focal leukocytoclasia, without evidence of vasculitis or dermal edema.

no vascular damage or dermal edema.<sup>2,5,6</sup> Several important histologic findings allow for the distinction of NUD from conventional urticaria and urticarial vasculitis. Neutrophilic epitheliotropism, neutrophils within the epidermis or adnexa, is a sensitive and specific histologic hint that allows the differentiation of NUD from neutrophilic urticaria. In our patient, the presence of dermal infiltrate consists of perivascular, peri adnexal, and interstitial neutrophils with focal leukocytoclasia, without evidence of vasculitis or dermal edema, that is not responsive to conventional urticaria treatment, support the diagnosis of NUD. In comparison to conventional urticaria, NUD inflammatory infiltrate lacks eosinophils and papillary dermal edema, as well as apparent vessel wall necrosis, as noticed in vasculitis.<sup>5</sup> Kieffer and Broekaert defined NUD clinically as a recurrent urticarial eruption that lasting less than 48 hours and associated with systemic disease or symptoms. Clinically, our patient presented with persistent eruption lasting more than 24 hours then fades with hyperpigmentation.<sup>5,6</sup> To date, NUD patients have been described as having associated systemic symptoms or associated systemic diseases, including adult-onset Still disease, systemic lupus erythematosus, Schnitzler syndrome, primary biliary cirrhosis, Sjögren's syndrome, inflammatory bowel disease, cryopyrin-associated periodic syndromes, and systemic juvenile idiopathic arthritis.<sup>5,6</sup> However, this is the second case with isolated clinical and pathologic features of NUD without associated systemic symptoms and signs of underlying systemic disease. The latest case was reported in 2020 by Gillihan et al. about NUD occurring in the absence of underlying systemic findings that showed an excellent response to low-dose dapsone.<sup>7</sup>

The pathogenesis of NUD is likely to be mediated by mast cell interleukin-1, neutrophil interleukin-17, and epidermal antimicrobial proteins. Individuals with NUD linked with either adult-onset Still disease or an unknown connective tissue disorder have responded to anakinra, an interleukin-1 receptor antagonist. Hence, interleukin-1 may be an important mediator of NUD. Dapsone and colchicine have been reported to be effective treatment options for systemic lupus erythematosus-associated NUD. Coupled with the clinical response observed in patients after IL-1 blockade, the inflammatory cascade in NUD seems to be upregulated by neutrophils influenced by the inflammasome pathway.<sup>7</sup>

---

## Conclusions

The cases reported here represent neutrophilic urticarial dermatitis based on clinicopathologic features but without associated systemic inflammatory symptoms and signs of an underlying systemic disease. Neutrophil-targeting agents, such as dapsone and colchicine, as well as interleukin-1 receptor antagonists, are likely to be effective as primary or adjuvant treatment modalities.

---

## References

1. Llamas-Velasco M, Fraga J, Requena L, et al. Neutrophilic urticaria or urticaria with predominantly neutrophilic inflammatory infiltrate: study of its clinical and histopathologic characteristics and its possible association with rheumatic disease. *Actas Dermosifiliogr (English edition)* 2012;103:511–9.
2. Velasco L, García-Diez A, Ovejero E, et al. Neutrophilic urticaria: descriptive study of 32 patients. *J Am Acad Dermatol* 2011;64.
3. Belani H, Gensler L, Bajpai U, et al. Neutrophilic urticaria with systemic inflammation: a case series. *JAMA Dermatol* 2013;149:453.
4. Lee WJ, Kang HJ, Shin HJ, et al. Neutrophilic urticarial dermatosis and sweet-like neutrophilic dermatosis: under-recognized neutrophilic dermatoses in lupus erythematosus. *Lupus* 2017;27:628–36.
5. Kieffer C, Cribier B, Lipsker D. Neutrophilic urticarial dermatosis: a variant of neutrophilic urticaria strongly associated with systemic disease. Report of 9 new cases and review of the literature. *Medicine* 2009;88:23–31.
6. Broekaert SMC, Böer-Auer A, Kerl K, et al. Neutrophilic epitheliotropism is a histopathological clue to neutrophilic urticarial dermatosis. *J Am Acad Dermatol* 2016;38:39–49.
7. Hou Z, Hinds BR, Cohen PR. Crohn disease-associated neutrophilic urticarial dermatosis: report and literature review of neutrophilic urticarial dermatosis. *Dermatol Online J* 2017;23.