

A case of *perifolliculitis capitis abscedens et suffodiens* and *acne conglobata* effectively treated with a tumor necrosis factor α inhibitor

Shinpei Miura, Kanako Tsunoda, Hiroo Amano

Department of Dermatology, School of Medicine, Iwate Medical University, Shiwa-gun, Iwate, Japan

To the Editor:

In Europe and the United States, *perifolliculitis capitis abscedens et suffodiens* (PCAS) and *acne conglobata* (AC) are often treated with isotretinoin and tumor necrosis factor α (TNF- α) inhibitors.¹ Treatment with these drugs is uncommon in Asia, and alternative treatment options are limited. In this paper, we report the case of a Japanese patient who presented with PCAS and AC and was treated successfully with adalimumab.

A healthy 20-year-old Japanese man presented with a 3-year history of inflammatory papules and subcutaneous scalp abscesses. Severe acne was also present on his face (Figure 1A). Approximately six months prior, alopecia with subcutaneous abscesses appeared on his scalp and spread gradually (Figure 1B). Despite treatment with oral and topical antibiotics, the patient's condition did not improve. A facial skin biopsy demonstrated neu-

trophil infiltration in the dermis, particularly around the hair follicles. Abscesses were observed in the deep dermis (Figure 1C). Thus, the patient was diagnosed with PCAS and AC. Adalimumab was initially administered at a dose of 160 mg, tapered to 80 mg two weeks later, and then to 40 mg weekly thereafter. One month after initiating treatment, the inflammatory papules and subcutaneous abscesses on the scalp and acne on the face gradually improved, and after three months, the eruptions significantly improved (Figure 1D). The growth of vellus hair in the alopecic patches was also noted. Six months after treatment initiation, the alopecic patches were covered with hair (Figure 1E). Currently, adalimumab is still being administered to the patient and continues to be effective.

PCAS, hidradenitis suppurativa (HS), and AC constitute the so-called follicular occlusion triad and are considered to have the same underlying pathogenesis. The nature of the pathogenesis remains unknown, but several mechanisms have been proposed. These include mechanical disruption and immunological dysfunction of the affected hair follicles due to either bacterial stimulation or activation of the innate immune response.¹ In normal skin, regulatory T-cells (Tregs) are localized in the perifollicular areas, helping to maintain hair follicle stem cell homeostasis, differentiation, and proliferation. In HS, T-helper 17 (Th17) cell expression is increased, while that of Tregs is decreased. This Th17/Tregs imbalance leads to the loss of hair follicle homeostasis.² In PCAS, Treg expression may also decrease, hair follicle homeostasis may be disrupted, and symptoms such as hair loss may occur. TNF- α inhibitors normalize the Th17/Tregs ratio.³

TNF- α inhibitors reduce inflammation but are not sufficiently effective for the treatment of cicatricial alopecia caused by PCAS.⁴ This is due to the hair follicles having already lost their structural integrity. In the reported case, the administration of adalimumab was initiated relatively early after the onset of hair loss. Therefore, the use of TNF- α inhibitors in the preliminary stages of the disease may prevent or reduce cicatricial alopecia before permanent destruction occurs.

In the reported case, adalimumab was markedly beneficial for the amelioration of PCAS and AC, suggesting that it could be an effective alternative treatment for medical conditions leading to follicular occlusion. The development of HS treatment in Asia lags behind that in Europe and the United States,⁵ and the same can be said for PCAS and AC treatments. However, in the future, we expect that treatment with TNF- α inhibitors for follicular occlusion disease will increase not only in Europe and the United States but also in a wider range of regions, including parts of Asia.

Correspondence: Shinpei Miura, Department of Dermatology, Iwate Medical University, 2-1-1 Idaidori, Yahaba-cho, Shiwa-gun, Iwate 028-3695, Japan.

Tel.: +81-19-613-7111 - Fax: +81-19-907-6647.

E-mail: shimiura@iwate-med.ac.jp

Key words: follicular occlusion tetrad, *perifolliculitis capitis abscedens et suffodiens*, *acne conglobata*, adalimumab, alopecia.

Contributions: SM, KT, HA, drafting the manuscript; SM, KT, acquisition and analysis of data.

Conflict of interest: the authors declare no potential conflict of interest.

Patient consent for publication: informed consent was obtained.

Availability of data and materials: data and materials are available from the corresponding author upon request.

Received: 24 February 2023.

Accepted: 24 February 2023.

Early view: 5 June 2023.

This work is licensed under a Creative Commons Attribution-NonCommercial 4.0 International License (CC BY-NC 4.0).

©Copyright: the Author(s), 2023

Licensee PAGEPress, Italy

Dermatology Reports 2023; 15:9699

doi:10.4081/dr.2023.9699

Publisher's note: all claims expressed in this article are solely those of the authors and do not necessarily represent those of their affiliated organizations, or those of the publisher, the editors and the reviewers. Any product that may be evaluated in this article or claim that may be made by its manufacturer is not guaranteed or endorsed by the publisher.

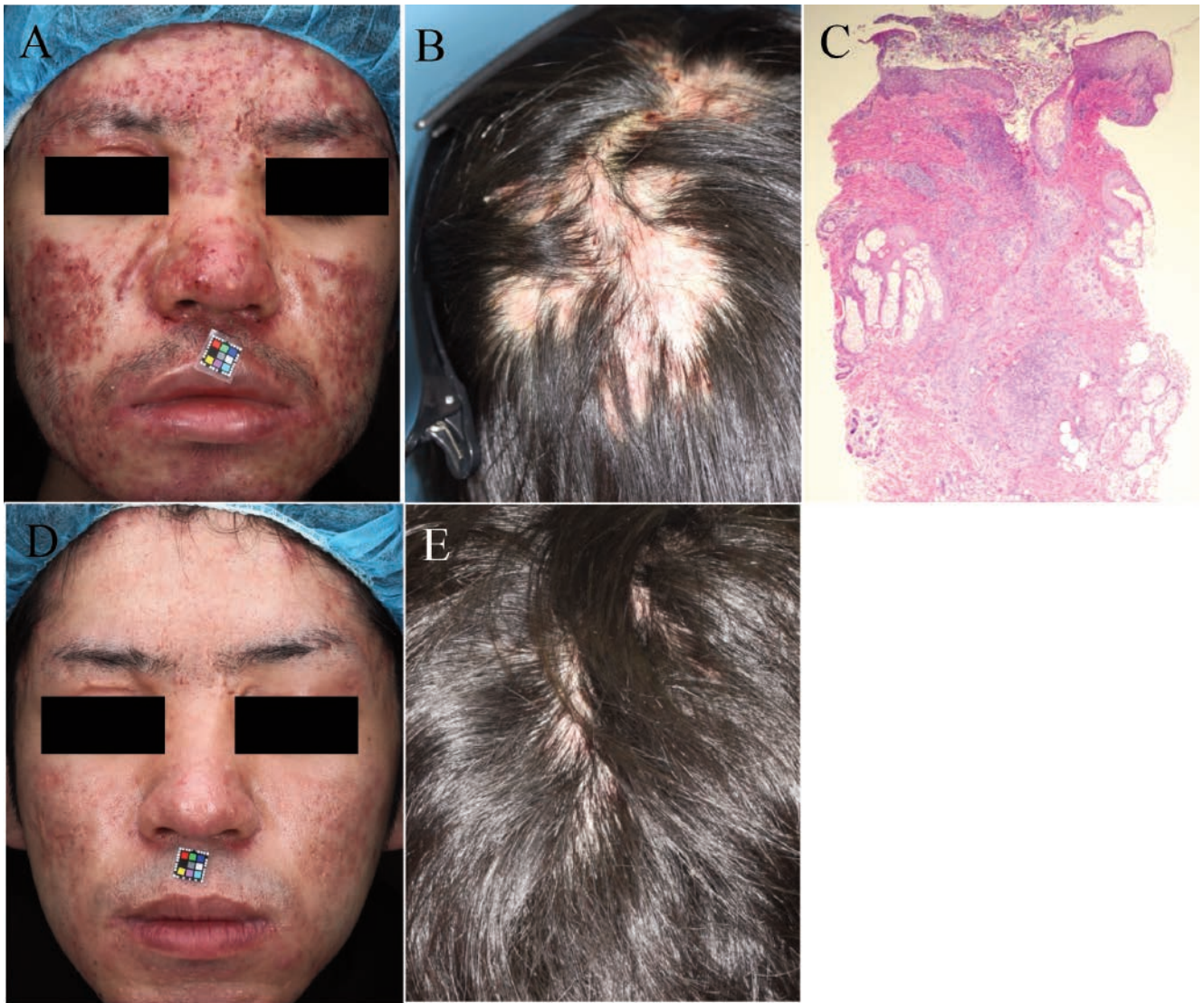


Figure 1. A) Before administration of adalimumab, severe acne is evident on the face; B) alopecic patches with subcutaneous abscesses are present on the scalp; C) skin biopsy shows neutrophil infiltration in the dermis: the infiltration is prominent around the hair follicles (hematoxylin and eosin, $\times 40$); D) significant improvement of the facial acne after treatment; E) coverage of the alopecic patches with hair.

References

1. Zouboulis CC, Desai N, Emtestam L, et al. European S1 guideline for the treatment of hidradenitis suppurativa/acne inversa. *J Eur Acad Dermatol Venereol* 2015;29:619-44.
2. Wu KK, Dao H Jr. Off-label dermatologic uses of IL-17 inhibitors. *J Dermatol Treat* 2022;33:41-7.
3. Melnik BC, John SM, Chen W, Plewig G. T helper 17 cell/regulatory T-cell imbalance in hidradenitis suppurativa/acne inversa: the link to hair follicle dissection, obesity, smoking and autoimmune comorbidities. *Br J Dermatol* 2018;179:260-72.
4. Mansouri Y, Martin-Clavijo A, Newsome P, Kaur MR. Dissecting cellulitis of the scalp treated with tumour necrosis factor- α inhibitors: experience with two agents. *Br J Dermatol* 2016;174:916-8.
5. Kamil MAA, Chandran NS, Sulistyaningrum SK, et al. The Asia Pacific hidradenitis suppurativa (APHIS) foundation: promoting hidradenitis suppurativa research in the Asia Pacific. *Int J Dermatol* 2020;59:e289-90.