

Which one is the most accurate naming convention: cutaneous lipofibroma or pedunculated lipofibroma?

Mohammed Al-Haddab

Department of Dermatology, College of Medicine, King Saud University, Riyadh, Saudi Arabia

Abstract

This is a case of a large pedunculated lipofibroma on the left axilla in a 36-year-old woman. The lesion was excised completely with no recurrence after one year of follow-up. A new name for this rare entity is proposed to be more inclusive of all lesions of pedunculated lipofibroma and to differentiate it from another entity called fibrolipoma.

Case Report

A 36-year-old healthy woman with a body mass index of 26 presented to the clinic with a large skin lesion on her axilla, which started 5 years prior as a small nodule that got bigger over 3 years and then stabilized (Figure 1).

Correspondence: Mohammed Al-Haddab, Department of Dermatology, College of Medicine, King Saud University, P.O. Box 2925 Riyadh 11461, Saudi Arabia.
Tel.: +966550760606.
E-mail: malhaddab@gmail.com

Key words: case report, lipofibroma, cutaneous, pedunculated, fibrolipoma.

Conflict of interest: the author declares no conflict of interest.

Patient consent for publication: informed consent was obtained from the patient.

Availability of data and materials: data and materials are available from the corresponding author upon request.

Received: 18 January 2023.

Accepted: 8 February 2023.

Early view: 23 May 2023.

This work is licensed under a Creative Commons Attribution-NonCommercial 4.0 International License (CC BY-NC 4.0).

©Copyright: the Author(s), 2023

Licensee PAGEPress, Italy

Dermatology Reports 2023; 15:9675

doi:10.4081/dr.2023.9675

Publisher's note: all claims expressed in this article are solely those of the authors and do not necessarily represent those of their affiliated organizations, or those of the publisher, the editors and the reviewers. Any product that may be evaluated in this article or claim that may be made by its manufacturer is not guaranteed or endorsed by the publisher.

On examination, there was a 3.8×3.6×2.6 cm skin-colored soft pedunculated tumor on the left axilla. Differential diagnoses were giant skin tag, pedunculated lipoma, and neurofibroma. After taking the appropriate consent forms to excise the lesion and to publish the case and the images, the lesion was excised completely with no recurrence after 1 year of follow-up.

Histopathology revealed mature fat cells arranged in compartments, separated by thin fibrous septa containing thick wall blood vessels and surrounded by thin fibrous capsules. There was no evidence of increased vascularity. The overlying skin was unremarkable and negative for malignancy (Figures 2 and 3).

Discussion and Conclusions

Nevus lipomatosus cutaneous superficialis (NLCS) was first described by Hoffmann and Zurhelle.¹ Two clinical types were recognized: i) multiple forms usually present as clustered groups of soft, fleshy nodules at birth or early decades of life, mostly on the pelvis or thighs;² ii) a solitary form first described by Weitzner and Wilson-Jones *et al.* that can present in older adults and with no site predilection.^{3,4}

Mehregan *et al.* were the first to designate pedunculated lipofibroma as the solitary type.⁵ In agreement with that designation and nomenclature, Nogita *et al.* published 32 cases of pedunculated lipofibroma.⁶ Since then, all solitary pedunculated tumors in the older age group have been diagnosed as pedunculated lipofibroma and not solitary NLCS.^{2,7}

The pathogenesis of pedunculated lipofibroma is unknown. Several hypotheses have been proposed, but none have been confirmed.⁶ It is considered a benign connective tissue proliferation with ectopic adipose tissue in the dermis.⁸

The association of lipofibroma with obesity and diabetes is not yet established. Though Adotama *et al.* reported three cases in obese adults,⁷ and Nogita *et al.* found that 21% of the cases were associated with diabetes mellitus.⁶ Huntley reported on a case of eruptive lipofibromas in a woman with diabetes and Cushing's syndrome.⁹ Our case was not associated with obesity or diabetes, nor was the case reported by Oztürkcan *et al.*²

Another entity with similar histopathology but a different clinical presentation is non-encapsulated subcutaneous fibrolipomas found in the subcutaneous area, digital nerve, oral cavity, pulmonary tract, gastroenterological area, and other locations.¹⁰

Fibrolipoma is considered a subtype of lipoma, and in one study, it represented 9% of all cases of subcutaneous lipomas.¹¹ Malignant transformation has not been reported with fibrolipoma.¹²

There are multiple names for similar histopathology but different clinical presentations. We propose to divide these lesions into two categories: i) cutaneous lipofibroma instead of pedunculated lipofibroma since not all lesions are pedunculated (Adotama *et al.* suggested naming them pedunculated lipofibroma for pedunculated and broad-based fatty lesions);⁷ ii) subcutaneous lipofibro-

ma instead of fibrolipoma (hence the bulk of the lesion is fatty tissue, not fibrous).

Cutaneous lipofibroma is a solitary lesion in older adults with no site predilection or recurrence after surgical excision. Subcutaneous lipofibroma refers to solitary lesions deep in the subcutaneous tissue, nerves, oral cavity, pulmonary tract, and other areas that are benign but might prove difficult to remove and have a high risk of recurrence and complications.

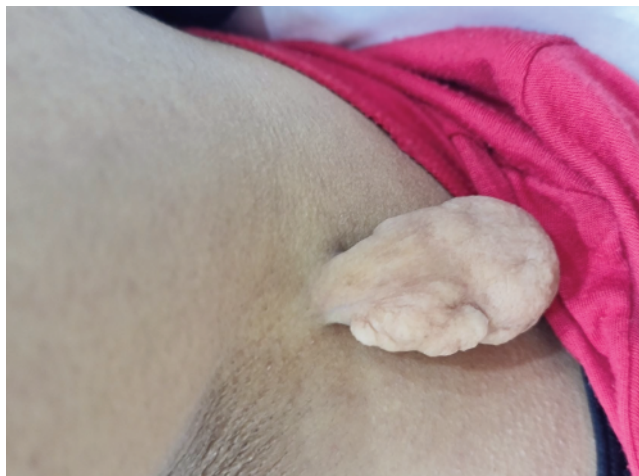

Figure 1. Large pedunculated lipofibroma on the left axilla.

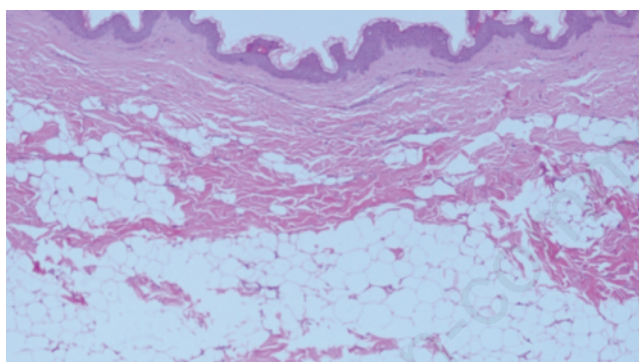


Figure 2. Histopathology of the lesion.

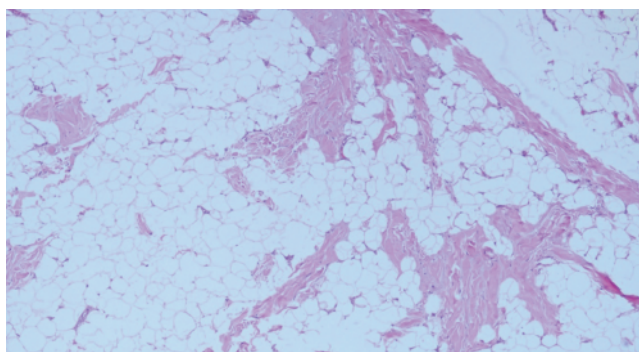


Figure 3. Histopathology of the lesion at 100× magnification.

References

- Hoffmann E, Zurhelle E. Uber einen naevus lipomatosus cutaneus superficialis der linken Glutealgegend. *Arch Derm Syphilol* 1921;130:327-33.
- Oztürkcan S, Terzioğlu A, Akyol M, et al. Pedunculated lipofibroma. *J Dermatol* 2000;27:288-90.
- Weitzner S. Solitary nevus lipomatosus cutaneus superficialis of scalp. *Arch Dermatol* 1968;97:540-2.
- Wilson-Jones E, Marks R, Pongsehirun D. Nevus superficialis lipomatosus: a clinicopathological report of twenty cases. *Br J Dermatol* 1975;93:121-33.
- Mehregan AH, Tavafolghi V, Ghandchi A. Nevus lipomatosus cutaneus superficialis (Hoffmann-Zurhelle). *J Cutan Pathol* 1975;2:307-13.
- Nogita T, Wong TY, Hidano A, et al. Pedunculated lipofibroma. A clinicopathologic study of thirty-two cases supporting a simplified nomenclature. *J Am Acad Dermatol* 1994;31:235-40.
- Adotama P, Hutson SD, Rieder EA, et al. Revisiting solitary pedunculated lipofibromas. *Am J Clin Pathol* 2021;156:954-7.
- Kwon KS, Seo KH, Jang HS, Chung TA. A case of apple-shaped pedunculated lipofibroma. *J Dermatol* 1997;24:258-61.
- Huntley AC. Eruptive lipofibromata. *Arch Dermatol* 1983;119:612-4.
- Lee YJ, Cho JW, Jung GM, et al. A case of fibrolipoma of the colon. *Korean J Gastrointest Endosc* 2008;37:142-5.
- Jun SS. Subcutaneous fibrolipoma on the back. *J Craniofac Surg* 2013;24:1051-3.
- Kim YT, Kim WS, Park YL, et al. A case of fibrolipoma. *Korean J Dermatol* 2003;41:939Y941.