

Erosive pustular dermatosis of the scalp: a pathogenetic mystery and therapeutic challenge

Georgi Tchernev,^{1,2} Simona Kordeva,¹ Iliia Batashki,³ Atanas Batashki,³ Heily Kirilova,² Konstantin Stavrov⁴
¹Onkoderma-Clinic for Dermatology, Venereology and Dermatologic Surgery, Sofia; ²Department of Dermatology and Venereology, Medical Institute of Ministry of Interior, Sofia; ³Medical Institute of Ministry of Interior, Sofia; ⁴Private clinic for dermatology, Venereology and Aesthetic medicine, Manastirski livadi WEST, Sofia, Bulgaria

Abstract

Erosive pustular dermatosis of the scalp (EPD) is a rare condition that affects predominantly the adult population and occurs on a previously photo-damaged bald scalp. The physical examination is presented with large erythematous, erosive and crusted patches with granulation on an atrophic skin. The problem in patients with erosive pustular dermatosis of the scalp arises from the non-specific clinical and histopathological findings, which can be misleading. Biopsy followed by careful histopathological verification is mandatory, although the finding is nonspecific. The histopathology findings are characterized by superficial erosions with mild neutrophil infiltrate, mainly intravascular and focally with neutrophil exocytosis; focal parakeratosis, smoothed rete ridges without pronounced interface changes; pronounced lymphoplasmacytic infiltrate with focal distribution in the dermis and giant cell reaction with the formation of a “foreign body” granuloma. We report a 58-year-old male patient with a 1-year-old lesion, suspected for skin cancer, later diagnosed with EPDS, which was successfully treated with topical clobetasol propionate after 3-5 weeks.

Introduction

Erosive pustular dermatosis of the scalp is a disease of unclear entity that predominantly affects the non-hairy area of the scalp in adults.¹ The pathogenetic mechanisms underlying this rare dermatosis remain unclear.²

The histopathological findings of the disease could be of mixed type and is often confusing,² but could include: i) epidermal ulceration, epidermal atrophy, ii) sterile pustules with variable localization, iii) reduced to completely absent hair follicles, as well as iv) nonspecific mixed inflammatory infiltrate.^{3,4}

According to other authors, the histopathological findings could be even more extensive or non-specific, such as: i) perifollicular granulomas, including remnants of hair follicles and giant multinucleated cells, ii) intrafollicular spongiform pustules, iii) neutrophilic microabscesses in the epidermis, iv) granulation tissue, v) aggregates of macrophages and foreign body type giant cells, vi) diffuse dermal fibrosis, vii) dermal inflammatory infiltrate of lymphocytes and neutrophils.¹

The problems in the treatment of this dermatosis arise, secondly, from the non-specific clinical picture, which makes clinicians quickly think in the direction of actinic keratoses and decide to start a radically different therapy. Thus, the histology itself subsequently becomes even more difficult to interpret.

Case Report

A 58-year-old man presented a 1-year-old lesion on a previously photo-damaged bald scalp suspected for skin cancer. The physical examination showed large erythematous, erosive and crusted patches with granulation on an atrophic skin (Figure 1A,B). The biopsy results showed changes in the epidermis according to the vesicular-bullous model with basal/suprabasal epidermolysis without the presence of acantholysis, superficial erosions with mild neutrophil infiltrate, mainly intravascular and focally with neutrophil exocytosis. Focal parakeratosis, smoothed rete ridges without pronounced interface changes. Pronounced lymphoplasmacytic infiltrate with focal distribution in the dermis, giant cell reaction with the formation of a “foreign body” granuloma.

Immunohistochemistry: cytokeratin – negative, CD 138 – positive for plasma cell composition, CD 68 – marked the heterogeneous macrophage cell composition, CD 20 marked small lymphocytes.

The diagnosis of erosive pustular dermatosis of the scalp was made.

The patient started topical treatment with clobetasol propionate 0.5 mg/g cream twice daily with favorable response after 4 weeks (Figure 2A,B).

Correspondence: Simona Kordeva, Onkoderma-Clinic for Dermatology, Venereology and Dermatologic Surgery, Sofia, Bulgaria.
 Tel.: +359.884959176.
 E-mail: simonakordeva97@gmail.com

Key words: erosive pustular dermatosis; topical treatment; neutrophil exocytosis; foreign body granuloma; clobetasol propionate

Contributions: the authors contributed equally.

Conflict of interest: the authors declare no potential conflict of interest.

Funding: none.

Ethical approval and consent to participate: written informed consent was obtained from the patient.

Availability of data and material: data and materials are available by the authors.

Informed consent: the manuscript does not contain any individual person's data in any form.

Received for publication: 6 July 2022.
 Accepted for publication: 10 July 2022.

This work is licensed under a Creative Commons Attribution-NonCommercial 4.0 International License (CC BY-NC 4.0).

©Copyright: the Author(s), 2023
 Licensee PAGEPress, Italy
 Dermatology Reports 2023; 15:9556
 doi:10.4081/dr.2022.9556

Publisher's note: all claims expressed in this article are solely those of the authors and do not necessarily represent those of their affiliated organizations, or those of the publisher, the editors and the reviewers. Any product that may be evaluated in this article or claim that may be made by its manufacturer is not guaranteed or endorsed by the publisher.

Discussion and Conclusions

The provoking or triggering factors for erosive pustular dermatosis are different, often confusing for the clinician and include in turn: certain drug triggers, namely – after or within panitumumab therapy,⁵ after local oxygen therapy,⁶ after photodynamic aminolevulinic acid therapy,⁷ treatment with gefitinib,⁸ nivolumab,⁹ sirolimus,¹⁰ topical imiquimod,¹¹ ingenol mebutate,¹² and latanoprost.¹³

The triggering factors could also be of a mechanical or infectious nature such as tri-

chotillomania *e.g.*,¹⁴ past herpes zoster infection,¹⁵ post-traumatic,¹⁶ after CO-2 laser resurfacing, after surgical interventions, or after hair transplantation.¹⁷ Determining the importance of the above-mentioned factors in relation to the pathogenesis of the disease remains controversial as it cannot always be clearly/definitely demarcated whether it is a sporadic association between two diseases or a pathogenetic relationship.

The problem with the patients with erosive pustular dermatosis of the scalp is coming from the fact that the clinical manifestation of the disease mainly affects the non-hairy areas of the scalp and could hardly be differentiated clinically from a hypertrophic form of actinic keratosis or non-melanocytic skin tumors.² Besides the possible parallel manifestation of the two mentioned diseases, the transition of erosive pustular dermatosis to non-melanocytic skin tumors such as basal cell and squamous cell carcinomas has also been described.^{18,19}

In practice, erosive pustular dermatosis (EPD) of the scalp could also be perceived as a precancerous condition. Repeat biopsies in this category of patients (with erosive pustular dermatosis of the scalp) are of significant prognostic importance.² Other important differential diagnoses that should not be neglected are: pemphigus type of bullous membrane pemphigoid, bacterial or fungal infection.²⁰

Scalp EPD therapy also remains a product of the individual approach of the clinician and has undergone some evolution in recent years.

The therapeutic options described in the world literature are variable and include i) topical zinc oxide,²¹ ii) the systemic application of sulfasalazine in combination with 308 nm monochromatic excimer light,²² iii) oral application of retinoid and a bi-layered skin substitute,²³ local application of novel silicone gel,²⁴ local treatment with 0.1% mometasone furoate cream,²⁵ systemic therapy with oral prednisone and topical tacrolimus,²⁶ local monotherapy with tacrolimus,²⁷ systemic dapsone therapy,²⁸ systemic therapy with acitretin,²⁹ photodynamic therapy,³⁰ isotretinoin systemically,³¹ local therapy with calcipotriol cream,³² and oral zinc sulphate.³³

First-line therapy remains the local application of potent corticosteroids and topical calcineurin inhibitors.² Systemic administration of corticosteroids and topical calcipotriol are considered as second-line therapy.² A third line is reserved for systemic retinoids and topical dapsone in the form of a 5% gel, for example.²

The opinion regarding the application

of photodynamic therapy with aminolevulinic acid, as well as the surgical approach, should be considered with particular attention as possible therapeutic

options, since there are conflicting clinical observations in the literature that describe these two options as more of a triggering/inducing factor.^{8,34-38}

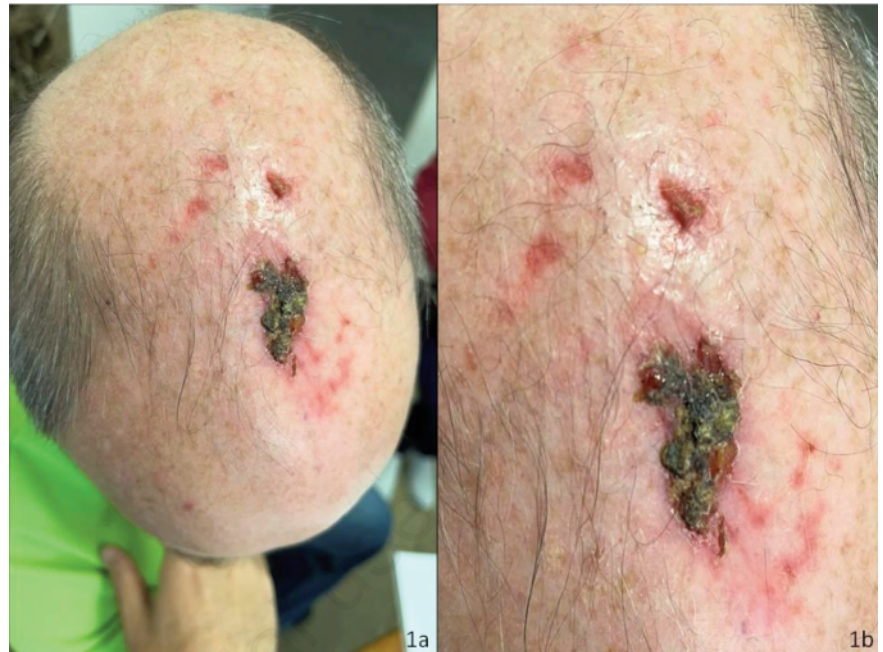

Figure 1. A,B) Clinical picture of a histopathologically proven form of erosive pustular dermatosis of the scalp with large erythematous, erosive and crusted patches with granulation on an atrophic skin with androgenetic alopecia.

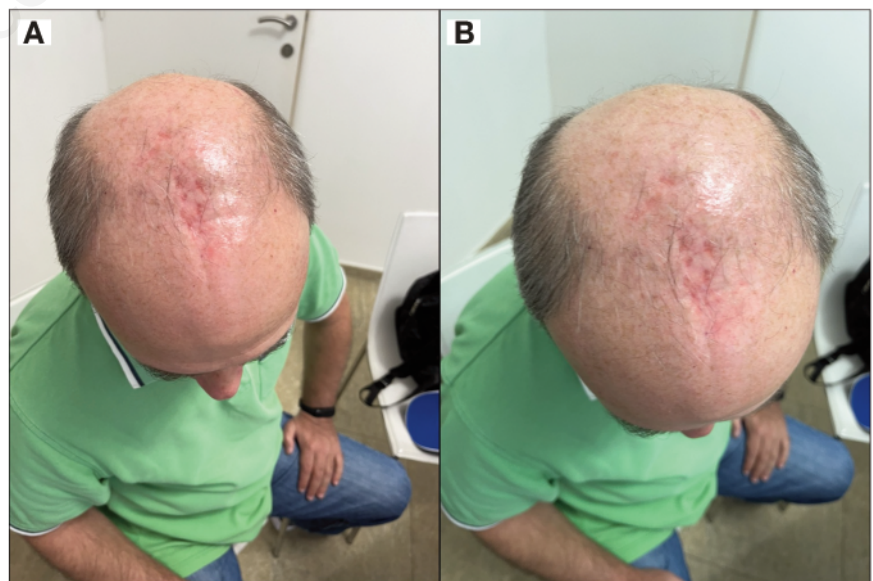


Figure 2. A,B) Improvement of the patient after starting therapy with topical clobetasol propionate 0.5 mg/g after 3-5 weeks. Residual erythema, with slight scarring can be seen.

References

1. Michelerio A, Vassallo C, Fiandrino G, Tomasini CF. Erosive pustular dermatosis of the scalp: a clinicopathologic study of fifty cases. *Dermatopathology* 2021;8:450-62.
2. Semkova K, Tchernev G, Wollina U. Erosive pustular dermatosis (chronic atrophic dermatosis of the scalp and extremities). *Clin Cosmet Investig Dermatol* 2013;6:177-82.
3. Pye RJ, Peachey RD, Burton JL. Erosive pustular dermatosis of the scalp. *Br J Dermatol* 1979;100:559-66.
4. Starace M, Loi C, Bruni F, et al. Erosive pustular dermatosis of the scalp: clinical, trichoscopic, and histopathologic features of 20 cases. *J Am Acad Dermatol* 2017;76:1109-14.e2.
5. Okuno S, Hashimoto T, Matsuo S, Satoh T. Erosive pustular dermatosis of the scalp-like eruption from panitumumab. *Australas J Dermatol* 2022;63:271-2.
6. Vaccaro M, Di Bartolomeo L, Campitiello A, Borgia F. Erosive pustular dermatosis of the scalp following topical oxygen therapy. *J Cosmet Dermatol* 2022;21:403-4.
7. Madray VM, Kent SM, Davis LS. Aminolevulinic acid photodynamic therapy-induced erosive pustular dermatosis of the scalp. *Dermatol Surg* 2021;47:1140-42.
8. Nazzaro G, Giacalone S, Bortoluzzi P, et al. Erosive pustular dermatosis of the scalp induced by gefitinib: case and review of the literature. *Dermatol Online J* 2021;27:13030.
9. Maglie R, Antiga E. Nivolumab-induced erosive pustular dermatosis of the scalp. *Int J Dermatol* 2020;59:e399-e400.
10. Khanna U, Semsarzadeh N, Glaser K, Fernandez AP. Erosive pustular dermatosis of the scalp associated with Sirolimus. *J Eur Acad Dermatol Venereol* 2020;34:e15-e16.
11. Giuffrida R, Borgia F, Cannavò SP. Two cases of erosive pustular dermatosis of the scalp occurring after topical 3.75% imiquimod for actinic keratoses. *Dermatol Ther* 2019;32:e12770.
12. Brambilla L, Turlaki A, Nazzaro G. Erosive pustular dermatosis of the scalp induced by ingenol mebutate. *G Ital Dermatol Venereol* 2018;153:743-745.
13. Vaccaro M, Barbuzza O, Borgia F, Cannavò SP. Erosive pustular dermatosis of the scalp following topical latanoprost for androgenetic alopecia. *Dermatol Ther* 2015;28:65-7.
14. Vaccaro M, Di Bartolomeo L, Guarneri F, Borgia F. Erosive pustular dermatosis of the scalp as local complication of trichotillomania. *J Cosmet Dermatol* 2022;21:4082-4083.
15. Güder H, Güder S, Yıldırım Ş. Erosive pustular dermatosis after herpes zoster. *Health Sci Rep* 2021;4:e277.
16. Wolff H, Flaig MJ. Posttraumatische erosive pustulöse Dermatoze am Kapillitium bei einer jungen Frau [Posttraumatic erosive pustular dermatosis on the scalp of a young woman]. *Hautarzt* 2020 Jul;71(Suppl 1):27-29. [In German]
17. Williams NM, Abrouk M, Kerdel FA, Kirsner RS. Erosive pustular dermatosis after CO2 laser resurfacing in mother and daughter. *Dermatol Ther* 2020;33:e14306.
18. Shahmoradi Z, Abtahi-Naeini B, Pourazizi M. Erosive pustular dermatosis of the scalp following hair transplantation. *Adv Biomed Res* 2014;3:176.
19. Negbenebor NA, Shayegan LH, Cohen LM, Kroumpouzou G. Nonmelanoma skin cancer in the setting of erosive pustular dermatosis of the scalp: a case series and comment on management implications. *Dermatol Ther* 2022;35:e15584.
20. Barilla S, Malviya N, Wang H, Sharon VR. Squamous cell carcinoma arising in chronic erosive pustular dermatosis. *Dermatol Surg* 2022;48:250-51.
21. Sladden C, Afford R. Erosive pustular dermatosis. *CMAJ* 2019;191:E667.
22. Di Altobrando A, Tabanelli M. Topical zinc oxide: breaking the vicious cycle of erosive pustular dermatosis of the scalp. *Int J Dermatol*. 2022;61:e216-e217.
23. Seckin D, Tekin B, Güneş P, Demirçay Z. Erosive pustular dermatosis of the leg in a young girl successfully treated with sulfasalazine and 308 nm monochromatic excimer light. *Photodermatol Photoimmunol Photomed* 2020;36:496-98.
24. Jaller JA, Borda LJ, Kirsner RS. Erosive pustular dermatosis of the leg successfully treated with an oral retinoid and a bi-layered skin substitute. *J Drugs Dermatol* 2019;18:301-302.
25. Uva L, Aphale AN, Kehdy J, Benedetto AV. Erosive pustular dermatosis successfully treated with a novel silicone gel. *Int J Dermatol* 2016;55:89-91.
26. Jankowski M, Skrzeczeko-Kwela E, Czajkowski R. Erosive pustular dermatosis of the scalp treated with 0.1% mometasone furoate cream. *Acta Dermatovenerol Croat* 2014;22:67-9.
27. Zahdi MR, Seidel GB, Soares VC, et al. Erosive pustular dermatosis of the scalp successfully treated with oral prednisone and topical tacrolimus. *An Bras Dermatol* 2013;88:796-8.
28. Tardio NB, Daly TJ. Erosive pustular dermatosis and associated alopecia successfully treated with topical tacrolimus. *J Am Acad Dermatol* 2011;65:e93-e94.
29. Feramisco JD, Goerge T, Schulz SE, et al. Disseminated erosive pustular dermatosis also involving the mucosa: successful treatment with oral dapsone. *Acta Derm Venereol* 2012;92:91-2.
30. Darwich E, Muñoz-Santos C, Mascaró JM Jr. Erosive pustular dermatosis of the scalp responding to acitretin. *Arch Dermatol* 2011;147:252-3.
31. Meyer T, López-Navarro N, Herrera-Acosta E, et al. Erosive pustular dermatosis of the scalp: a successful treatment with photodynamic therapy. *Photodermatol Photoimmunol Photomed* 2010;26:44-5.
32. Petersen BO, Bygum A. Erosive pustular dermatosis of the scalp: a case treated successfully with isotretinoin. *Acta Derm Venereol* 2008;88:300-1.
33. Boffa MJ. Erosive pustular dermatosis of the scalp successfully treated with calcipotriol cream. *Br J Dermatol* 2003;148:593-5.
34. Ikeda M, Arata J, Isaka H. Erosive pustular dermatosis of the scalp successfully treated with oral zinc sulphate. *Br J Dermatol* 1982;106:742-3.
35. Saridakis S, Giesey RL, Ezaldein HH, Scott JF. Erosive pustular dermatosis of the scalp following surgical procedures: a systematic review. *Dermatol Online J* 2020;26:13030.
36. Eusen M, Fleuret C, Kupfer I, Fouchard F, Staroz F, Grangier Y, Plantin P. Pustulose érosive des jambes récidivant sur une greffe de peau mince [Recurrence of pustular erosive dermatosis of the leg after a skin graft]. *Ann Dermatol Venereol* 2012;139:224-5.
37. Mehmi M, Abdullah A. Erosive pustular dermatosis of the scalp occurring after partial thickness skin graft for squamous cell carcinoma. *Br J Plast Surg* 2004;57:806-7.
38. Ena P, Lissia M, Doneddu GM, Campus GV. Erosive pustular dermatosis of the scalp in skin grafts: report of three cases. *Dermatology* 1997;194:80-4.