

Evans' syndrome following vaccination with ChAdOx1 nCoV-19 in a patient with new-onset localized scleroderma

Thilo Gambichler, Pia Nordmann, Christina Scheel, Laura Susok

Skin Cancer Center, Department of Dermatology, Ruhr-University Bochum, Germany

Abstract

Growing evidence suggests that COVID-19 vaccines can induce hematological conditions. Here, we report a case of Evans' syndrome, a combination of immune thrombocytopenic purpura and autoimmune hemolytic anemia following administration of the ChAdOx1 nCoV-19 vaccine. The present case further supports the notion that COVID-19 vaccines can trigger in rare cases severe persistent autoimmune-mediated hematological conditions which may predominantly occur in patients with underlying autoimmune conditions.

Introduction

Growing evidence suggests that not only the novel coronavirus disease (COVID-19), but also anti-SARS-CoV-2 vaccines can cause numerous cutaneous and other adverse events (AEs). The majority of these AEs are of immunological and autoimmunological nature. Autoimmune-mediated conditions following COVID-19 vaccination include leukocytoclastic vasculitis, lupus erythematosus, and bullous pemphigoid.¹ Importantly, molecular mimicry exists between the viral spike protein, whose sequence is used to design mRNA- and vector-based vaccines, and human proteins, such as ankyrins. Such molecular mimicry may explain both certain COVID-19-related AEs as well as those due to COVID-19 vaccination.² Harmless purpuric skin lesions following COVID-19 vaccinations have recently been reported, however, as illustrated by the present case, such lesions may also rarely represent cutaneous signs of serious vaccine-induced hematological conditions.^{1,3} One of the most severe, but fortunately very rare thrombotic conditions which has almost exclusively been observed after administration of viral vector-based COVID-19 vaccines, is vaccine-induced prothrombotic

immune thrombocytopenia (VIPIT), which is characterized by cerebral venous sinus thrombosis and/or splanchnic venous thrombosis.³ Another rare hematological COVID-19 vaccine-induced complication is immune thrombocytopenic purpura (ITP).⁴ Recently, autoimmune hemolytic anemia (AIHA) has also been observed in association with the COVID-19 vaccinations.⁵ In October 2021, Hidaka *et al.*⁶ reported, for the first time, a case of Evans syndrome, which can be described as a combination of ITP and AIHA occurring shortly after mRNA COVID vaccination. Here, we here report a severe case of ChAdOx1 nCoV-19-induced Evans' syndrome which was preceded by new-onset autoimmune skin disease.

Case Report

About two weeks after receiving her first ChAdOx1 nCoV-19 vaccination, a 56-year-old female noticed an increased frequency of bruises following minor trauma. Moreover, she noticed brownish discoloration of her urine during this period. Eventually, she presented at our department with a three-day history of spontaneous oral, nasal, genital, and intestinal bleedings. Apart from this, she reported no other symptoms and denied any history of easily bruising or abnormal bleeding prior to receiving the vaccine. Previous laboratory investigations did not show evidence for hematological conditions. She also denied any new medications or changes in her ethinyloestradiol levels and had no family history of autoimmune disorders. However, the patient had noticed a hardening of the skin on her right leg about four weeks prior to the vaccination. On clinical examination, she presented with numerous macular petechiae across her extremities and hemorrhagic bullae of the tongue, oral and genital mucosa (Figure 1). In addition, discrete yellowish discoloration of her sclera and a large bruise on her right foot were observed. Moreover, the mid-upper right leg and complete lower right leg were covered by hypopigmented indurated plaques (Figure 1). Histopathology of a biopsy taken from a purpuric lesion (forearm) revealed an abundance of erythrocyte extravasates without signs of vasculitis, consistent with a diagnosis of purpura. By contrast, a biopsy from an indurated plaque (right lower leg) unequivocally showed sclerosing dermatitis with inflammatory infiltrates consistent with a diagnosis of early stage of localized scleroderma (LS). Since severe thrombocytopenia was suspected, we promptly admitted the

Correspondence: Thilo Gambichler, Skin Cancer Center, Department of Dermatology, Ruhr-University Bochum, Gudrunstraße 56, 44791, Bochum, Germany.
E-mail: gambichler@me.com

Key words: COVID-19 vaccination; SARS-CoV-2 vaccine; immune thrombocytopenic purpura; autoimmune hemolytic anemia; Evans' syndrome; scleroderma; morphea.

Contributions: Conceptualization, TG, LS; data interpretation, TG, investigation, PN, LS, CHS, TG; writing original draft preparation, TG; visualization, TG, PN, LS. All authors have read and agreed to the published version of the manuscript.

Conflict of interest: The authors declare no conflicts of interest.

Funding: None.

Informed consent statement: Informed consent was obtained from the patient presented.

Data availability statement: Not applicable.

This work is licensed under a Creative Commons Attribution-NonCommercial 4.0 International License (CC BY-NC 4.0).

Received for publication: 7 January 2022.
Accepted for publication: 20 January 2022.

©Copyright: the Author(s), 2022
Licensee PAGEPress, Italy
Dermatology Reports 2022; 14:9470
doi:10.4081/dr.2022.9470

Publisher's note: All claims expressed in this article are solely those of the authors and do not necessarily represent those of their affiliated organizations, or those of the publisher, the editors and the reviewers. Any product that may be evaluated in this article or claim that may be made by its manufacturer is not guaranteed or endorsed by the publisher.

patient to the internal medicine department. Laboratory findings revealed a platelet count of 1000/ μ l, which fell to 0/ μ l within 24 hours of admittance. The immature platelet fraction was 0.0% (1.1-6.1). Platelet factor 4 (PF4) antibodies were not detected. As shown in Table 1, further blood tests revealed decreased erythrocyte count, hemoglobin and hematocrit, and increased reticulocyte parameters, lactate dehydrogenase, mean corpuscular volume, and mean corpuscular hemoglobin. Haptoglobin was not elevated. Cryoglobulines and cold agglutinins were negative. Direct Coombs test was positive for warm anti-IgG antisera with panreactive specificity (Table 1). Prothrombin time, activated partial-thromboplastin time, and d-dimers, were unre-

markable. Peripheral blood smear revealed mild anisocytosis, polychromasia, absence of thrombocytes and no evidence for malignancies such as lymphoproliferative diseases. Flow cytometry of peripheral blood also excluded lymphoproliferative disorders. Viral serology, including testing for hepatitis (A, B, C), EBV, HIV, Parvovirus, CMV, influenza-A/B, and SARS-CoV-2, was negative. Tests for renal and liver function were also unremarkable. Taken together, the patient suffered from severe thrombocytopenia and hemolytic anemia with panreactive antisera detected by direct Coombs testing. Further substantiating autoimmunity, circulating immune complexes were slightly elevated with 4.57 $\mu\text{gEq/ml}$ (0-4.4). Antinuclear autoantibody (ANA) titer was 1:160 (1:80) and anti-Ro-52 antibodies were positive. Based on these clinical and laboratory findings, we diagnosed the patient with COVID-19 vaccine-induced Evans' syndrome preceded by a new onset of LS. Consequently, the patient was treated with a tapered regimen of high-dose prednisolone followed by dexamethasone and administration of intravenous immunoglobulins which resulted in a gradual improvement of platelet counts and the cessation of spontaneous bleeding. After four weeks, the patient was discharged into hematological and dermatological outpatient care with stable platelet and erythrocyte counts. However, a six-month follow-up revealed that she still suffered from minor hematomas, thrombocytopenia and macrocytic anemia with elevated LDH requiring treatment with eltrombopag 75 mg per day as well as intermittent oral prednisolone. Under this treatment combined with topical calcipotriene once daily, her LS slightly improved.

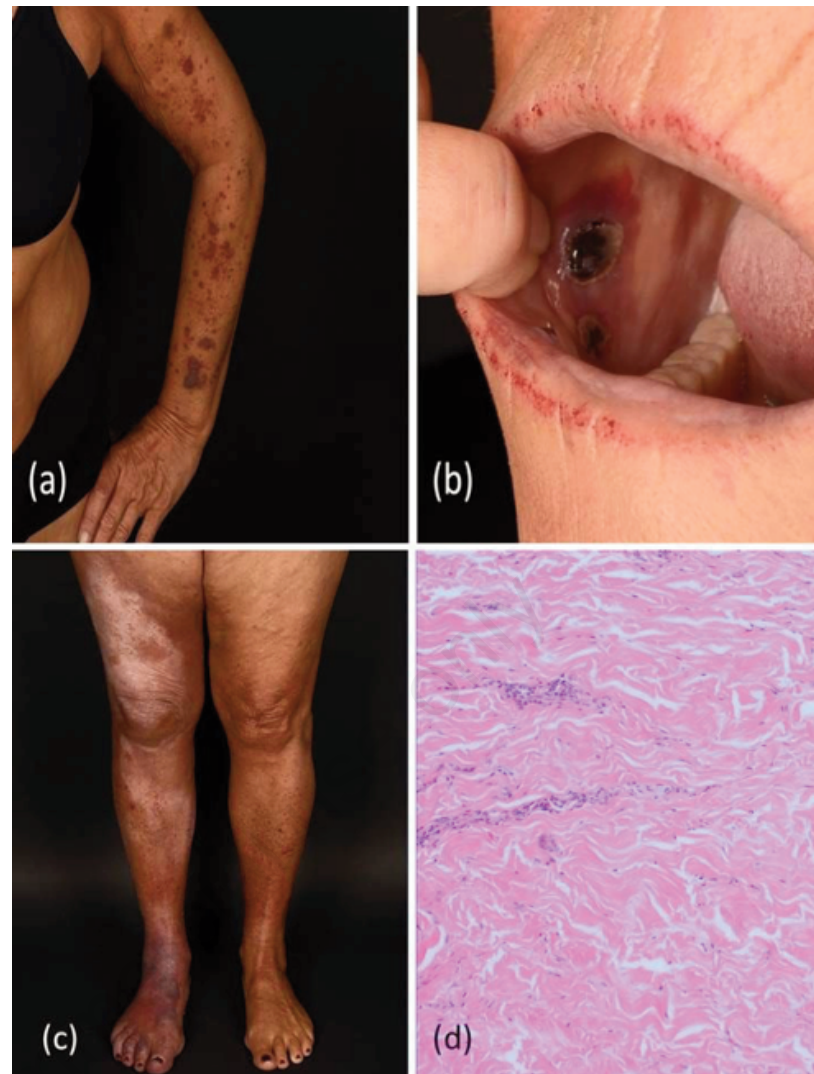


Figure 1. Showing widespread purpuric macules on the left arm (a) and succulent hemorrhagic lesions on the oral mucosa (b) in a patient with severe immune thrombocytopenic purpura following COVID-19 vaccination. Right leg covered by hypopigmented indurated plaques (c). Histopathology of an indurated plaque (right lower leg) revealed sclerosing dermatitis with rarefaction of adnexal structures and strongly thickened collagen fibers as well as inflammatory infiltrates in the deep dermis, consistent with a diagnosis of localized scleroderma (d).

Table 1. Laboratory results of patient with COVID-19 vaccine-induced Evans' syndrome accompanied by underlying autoimmune skin condition.

Parameter/reference range	On admission	On 3-month follow-up	On 6-month follow-up
Erythrocytes (4.2-5.4/ μl)	2.8↓	2.9	3.5
Hemoglobin (12-16 g/dl)	9.9↓	10.9	12
Hematocrit (36-46%)	28.3↓	31.5	34.5
Mean corpuscular volume (85-95 fl)	100.5↑	111	99
Mean corpuscular hemoglobin (27-33 pg)	35.1↑	38	35
Reticulocytes (5-15 o/oo)	25↑	26	25
Total bilirubin (<1.5 mg/dl)	0.5	0.2	0.3
Lactate dehydrogenase (135-214 U/l)	248↑	301	221
Indirect Coombs test (negative)	Positive	-	Negative
Direct Coombs-test (negative) autoantibodies, pan-reactive IgG antibodies	Positive for warm	-	Questionable monospecific IgG antibodies
Thrombocytes (150.000-400.000/ μl)	1000↓↓	27.000	45.000

Discussion

In contrast to VIPIT, purpura and bleeding events accompanied by very low platelet counts are much more common in patients with ITP.^{3,5} The latter was previously observed following measles/mumps/rubella, hepatitis A/B, or varicella vaccinations. Importantly, multiple ITP cases, including fatal ones due to central nervous hemorrhages, have been reported after COVID-19 vaccination.^{1,5} One of the suggested mechanisms by which COVID-19 infection as well as COVID-19 vaccination may induce autoimmune responses against platelets is the presence of molecular mimicry between the viral spike protein and human proteins such as ankyrins (Figure 2). The temporal context and the fact that the patients reported in the literature were otherwise healthy are highly suggestive of vaccine-induced hematological complications. Moreover, vaccine-induced ITP is considered biologically plausible, since COVID-19 infection is also frequently associated with hematological AEs.

Evans' syndrome is an autoimmune condition that presents with two or more cytopenia, which usually include ITP and warm (about 37°C) AIHA which is mainly characterized by extravascular hemolysis in the spleen.^{6,7} Warm AIHA is diagnosed in the presence of anemia, usually macrocytic and of variable intensity, reticulocytosis, and a positive direct Coombs test positive for warm anti-IgG antisera with panreactive specificity or anti-IgG plus C3 at low titer.⁷ Depending on disease severity and time of evaluation, increased serum LDH and indirect bilirubin, and decreased haptoglobin are frequent findings in patients with AIHA. In the present case, normal coagulation parameters and the absence of schistocytes excluded a diagnosis of disseminated intravascular coagulation and other microangiopathies. Unlike primary Evans' syndrome, secondary Evans' cases are associated with a variety of conditions, including infections, primary immunodeficiencies, systemic autoimmune diseases (e.g., systemic lupus erythematosus, rheumatoid arthritis), lymphoproliferative syndromes, and hematopoietic stem cell transplantation.⁷ Fattizzo *et al.*⁷ recently described the largest case series of adult Evans' syndrome (n=116) and showed that the disease may be very severe, often relapsing and marked by frequent fatal outcome. Fattizzo *et al.*⁷ also showed that hematologic parameters at disease onset were highly variable depending on the prevailing autoimmune cytopenia. Accordingly, over 40% of patients present-

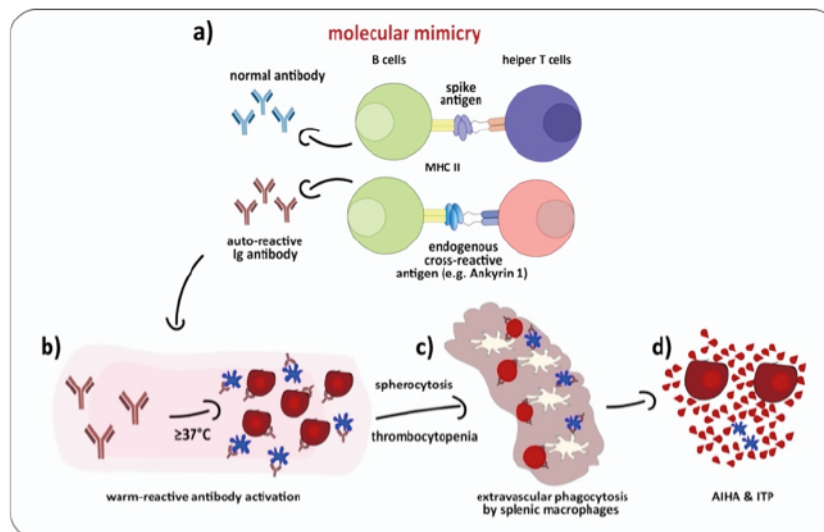


Figure 2. Sketch of the proposed molecular mechanism of AIHA and ITP in a patient suffering from vaccine-induced Evan's Syndrome. (a) Molecular mimicry during B cell activation by CD4 T helper cells triggers auto-reactive Ig antibody production (MHC, major histocompatibility complex). (b) Increase in temperature to $\geq 37^{\circ}$ induces activation of warm-reactive antibodies to RBCs and thrombocytes. (c) Extravascular phagocytosis of thrombocytes and spherocytes by splenic macrophages. (d) Macrocytic anemia and immune thrombocytopenia as demonstrated in a patient suffering from vaccine-induced Evan's syndrome.

ed with severe anemia (Hb<8 g/dl), almost 50% with increased LDH, and almost 60% with severe thrombocytopenia (<30.000/ μl). Regarding autoimmunity testing, almost 90% of tested subjects had a positive direct Coombs test and non-organ specific autoantibodies were detected in over 50% of cases (e.g., ANA, ENA, lupus anticoagulant).⁷

LS, also referred to as morphea, is an uncommon inflammatory and fibrotic disease of the skin and subcutis. LS encompasses a wide spectrum of clinical variants ranging from solitary skin lesions with minimal discomfort to severe subtypes such as generalized or linear morphea. The exact etiology of LS is still unknown, but genetic factors, autoimmune alterations, and environmental factors may play roles in the pathogenesis. Notably, patients with more generalized LS forms relatively frequently test positive for autoimmune antibodies such as ANA.³ In the present case, mild serological autoimmune phenomena and LS, which had developed about 4 weeks prior to the vaccination, may indicate an increased susceptibility to autoimmune-mediated vaccine-induced reactions. Even though very rare cases of LS associated with ITP have been reported, the COVID-19 vaccine was most likely the crucial trigger in the present case. Interestingly, Malayala *et al.*⁸ recently reported a female patient with known history of rheumatoid arthritis as well as mixed connective tissue

disease including scleroderma and hypertension, who developed ITP following booster vaccination with a mRNA-based vaccine. Indeed, Okada *et al.*⁹ recently reported common features observed in COVID-19 vaccine-induced ITP in an Asian population, including old age and rheumatoid arthritis. Moreover, Hidaka *et al.*⁶ observed COVID-19 vaccine-induced Evans' syndrome and systemic lupus erythematosus in a patient with preexisting Hashimoto and Voigt-Koyanagi-Harada disease, representing two well-recognized autoimmune conditions.

Recently, De Felice *et al.*¹⁰ reported another case of Evans' syndrome as an atypical complication of SARS-CoV-2 vaccination. Notably, AIHA has also been frequently observed in patients infected with SARS-CoV-2. Indeed, COVID-19 vaccine-induced hematological conditions not only include VIPIT and ITP, but also AIHA as well as acquired hemophilia (AHA), the latter also being recognized as an autoimmune mediated condition. In fact, Radwi and Farsi¹⁰ reported a patient who developed bruises on his arms and legs shortly after COVID-19 mRNA vaccination. Laboratory tests revealed severely prolonged activated partial thromboplastin time, elevated Willebrand antigen/function, FVIII level at 1%, and FVIII inhibitor titer at 80 Bethesda units, which were consistent with the diagnosis of AHA.¹¹

Conclusions

COVID-19 vaccines can trigger severe persistent autoimmune-mediated hematological conditions such as Evans' syndrome which may predominantly occur in patients with underlying autoimmune conditions. Moreover, the present case underscores that dermatologists in particular need to be aware of such rare, but severe side effects when patients present to them with cutaneous symptoms such as COVID-19 vaccine-induced purpura.

References

- Gambichler T, Boms S, Susok L, et al. Cutaneous findings following COVID-19 vaccination: review of world literature and own experience. *J Eur Acad Dermatol Venereol* 2022;36:172-80.
- Akinosoglou K, Tzivaki I, Marangos M. Covid-19 vaccine and autoimmunity: Awakening the sleeping dragon. *Clin Immunol* 2021;226:108721.
- McGonagle D, De Marco G, Bridgewood C. Mechanisms of Immunothrombosis in Vaccine-Induced Thrombotic Thrombocytopenia (VITT) Compared to Natural SARS-CoV-2 Infection. *J Autoimmun* 2021;121:102662.
- Welsh KJ, Baumblatt J, Chege W, et al. Thrombocytopenia including immune thrombocytopenia after receipt of mRNA COVID-19 vaccines reported to the Vaccine Adverse Event Reporting System (VAERS). *Vaccine* 2021;39:3329-32.
- Krajewski PK, Szepietowski JC. Immune thrombocytopenic purpura associated with COVID-19 Pfizer-BioNTech BNT16B2b2 mRNA vaccine. *J Eur Acad Dermatol Venereol* 2021;35: e626-e7.
- Hidaka D, Ogasawara R, Sugimura S, et al. New-onset Evans syndrome associated with systemic lupus erythematosus after BNT162b2 mRNA COVID-19 vaccination. *Int J Hematol* 2021:1–4.
- Fattizzo B, Michel M, Giannotta JA, et al. Evans syndrome in adults: an observational multicentre study. *Blood Adv* 2021:bloodadvances.2021005610.
- Malayala SV, Papudesi BN, Sharma R, et al. A Case of Idiopathic Thrombocytopenic Purpura After Booster Dose of BNT162b2 (Pfizer-Biontech) COVID-19 Vaccine. *Cureus* 2021;13:e18985.
- Okada Y, Sakai R, Sato-Fitoussi M, et al. Potential Triggers for Thrombocytopenia and/or Hemorrhage by the BNT162b2 Vaccine, Pfizer-BioNTech. *Front Med (Lausanne)* 2021;8:751598.
- De Felice M, Farina G, Bianco R, et al. Evans Syndrome Presenting as an Atypical Complication of SARS-CoV-2 Vaccination. *Cureus* 2022;14:e26602.
- Radwi M, Farsi S. A case report of acquired hemophilia following COVID-19 vaccine. *J Thromb Haemost* 2021;19:1515-8.