

Improvement of atopic dermatitis and alopecia universalis with dupilumab

Lama Alotaibi,¹ Abdulrahman Alfawzan,² Raghad Alharthi,² Afaf Al sheikh³

¹Division of Dermatology, Department of Medicine, Prince Sultan Military Medical City, Riyadh; ²College of Medicine, King Saud University for Health Sciences, Riyadh; ³Division of Dermatology, Department of Medicine, King Abdulaziz Medical City, Riyadh, Saudi Arabia

Abstract

Dupilumab is an interleukin-4 receptor alpha antagonist that showed significant improvement of atopic dermatitis (AD). Many reports have shown significant resolution of alopecia areata, alopecia universalis and alopecia totalis after dupilumab treatment for AD. We present one of reported cases that showed improvement of underlying alopecia universalis treated with dupilumab.

Introduction

Dupilumab is an interleukin (IL)-4 receptor alpha antagonist that subsequently blocks IL-4 and IL-13 signaling, that showed significant improvement of AD. Alopecia areata has been associated with AD. Many reports have shown significant resolution of alopecia areata (AA), alopecia

totalis (AT), and alopecia universalis (AU) after dupilumab treatment for AD. This case report shows a case of significant dual improvement of AD and AU treated with dupilumab.

Case Report

A 21-years-old female is known to have AD since childhood and AU for 9 years. Patient used topical treatments and narrow-band ultraviolet B phototherapy with limited improvement. Since the patient had limited improvement and multiple relapses of AU, tofacitinib 5 mg twice daily was considered. After starting tofacitinib patient had hair growth over the eyebrows, eyelashes, armpit, pubic, and most of the scalp sparing occipital and left lateral temporal areas of the scalp and lower limbs. After 7 months of tofacitinib use, patient experienced upper limb numbness and headache. Tofacitinib was discontinued and patient refused any previous treatment. Since then, she experienced full hair loss as shown in (Figure 1). Three months later, without medical advice patient used tofacitinib for only 2 months. Tofacitinib was discontinued again, and patient was started on dupilumab 300 mg subcutaneous injection biweekly for 9 months which showed an excellent improvement for both diseases after 2 months. On examination, patient had hair regrowth all over the scalp as shown in (Figure 2) and eyebrows, a few well-demarcated rounds to oval non-scarring alopecia patches over the scalp with partial loss of eyelashes hair. After four months follow up, the patient continued to have an improvement (Figure 3 A-C), with only one alopecic patch in the vertex (Figure 4).



Figure 1. Full hair loss after discontinuation of Tofacitinib.

Correspondence: Abdulrahman Alfawzan, College of Medicine, King Saud bin Abdulaziz University for Health Sciences, Riyadh, Saudi Arabia.
Tel.: +966.53.2735302.
E-mail: alfawzan.job@gmail.com

Key words: Alopecia Areata, Alopecia Universalis, Atopic Dermatitis, Dupilumab.

Contributions: LA contribute effectively in writing the clinical part of the case and obtaining full history of the patient; AA contributes effectively in writing and literature review; RA contributes effectively in writing and literature review; AAS was the treating physician of the patient and contributes effectively in writing and extensively reviewed the manuscript.

Conflict of interest: The authors declare no potential conflict of interest.

Funding: None.

Ethical approval and consent to participate: Received.

Availability of data and material: Data and materials are available by the authors.

Please cite this article as: Alotaibi L, Alfawzan A, Alharthi R, Al sheikh A. Improvement of atopic dermatitis and alopecia universalis with dupilumab. *Dermatol Rep* 2022;14:9359.

Received for publication: 23 August 2021.
Accepted for publication: 24 August 2021.

This work is licensed under a Creative Commons Attribution-NonCommercial 4.0 International License (CC BY-NC 4.0).

©Copyright: the Author(s), 2022
Licensee PAGEPress, Italy
Dermatology Reports 2022; 14:9359
doi:10.4081/dr.2022.9359

Publisher's note: All claims expressed in this article are solely those of the authors and do not necessarily represent those of their affiliated organizations, or those of the publisher, the editors and the reviewers. Any product that may be evaluated in this article or claim that may be made by its manufacturer is not guaranteed or endorsed by the publisher.

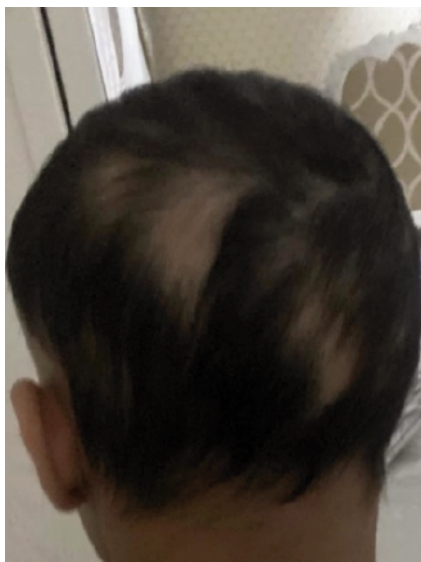

Figure 2. Patchy hair regrowth after the use of dupilumab.

Discussion and conclusions

IL-3/IL14 cause AD by promoting Th2 cells differentiation, disrupting skin barrier functions, and switching to IgE production. IL-4/IL-13 reduce skin barrier functions by down-regulating expression of filaggrin gene in keratinocyte which results in increased susceptibility to infections.¹ Also, higher activity of Th2 cells were associated with decreased activity of Th1 cells cytokines that are crucial for fighting infections.^{2,3} Dupilumab efficacy in the management of AD was associated with interfering with all previous pathophysiologies.⁴ On the other hand, AA is an auto immune disease which is mediated by Th1 cells pathway activity and demonstrating an increased Th1 cells cytokines (IFN-gamma and IL-12) in the circulation. However, recently AA has been linked to atopy (Th2 cells mediated diseases). IL-13, the main mediator of Th2 cells, was significantly up regulated in both AA and AD skin lesions.⁵ Along with epidemiological and molecular links of AA and AD, studies found strong genetic association between IL-4/IL-13 and AA.⁶ This shared pathophysiology of the diseases can explain the significant improvement of both diseases after treatment with IL-4/IL-13 inhibitor (dupilumab). However, the paradoxical response of AA could be attributed by the mixed Th1 and Th2 mediated pathophysiology of AA.⁵

Since dupilumab approval for AD, many case reports showed improvement, and others showed worsening of AA, AU,

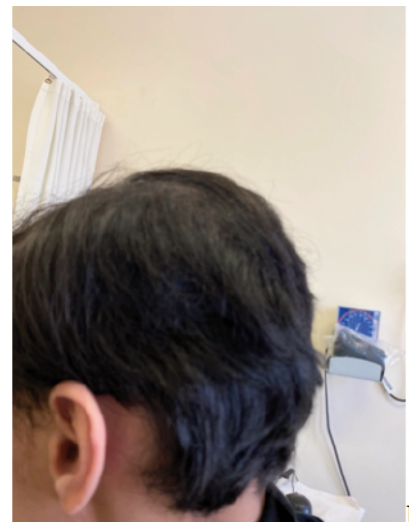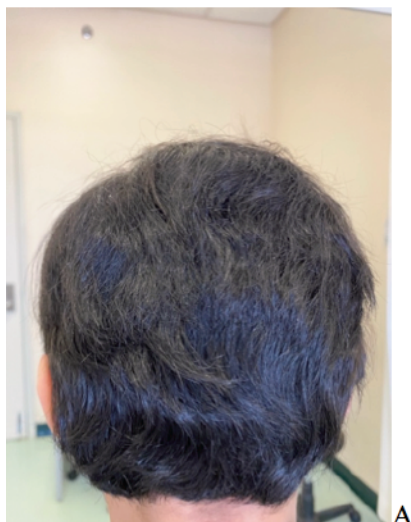


Figure 3. A), B) and C) showed significant hair regrowth after 4 months follow-up.

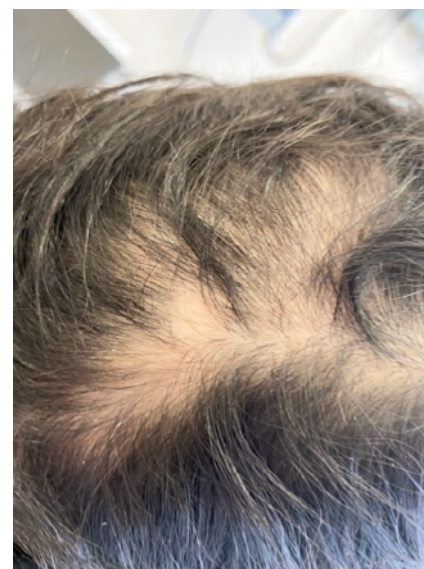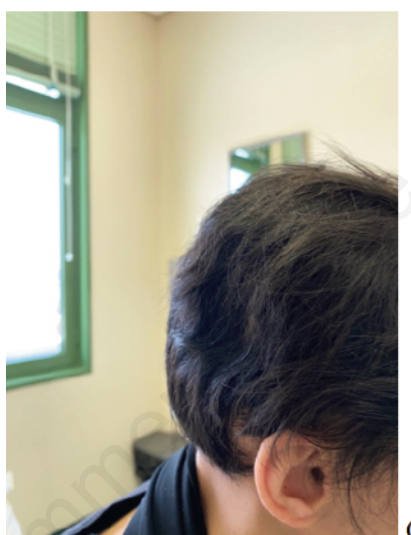


Figure 4. A solitary non scarring well defined alopecic patch expanding over the vertex of the scalp with few well detached fine scales.

and AT.⁷⁻¹⁰ The improvement was noted after the few first doses in some reports, however most cases showed a significant improvement after few months of treatment. Hair regrowth was most noted in the scalp.

We present a case of improvement of both AU and AD in a patient treated with dupilumab. Since dupilumab has been recently approved for the treatment of AD, little is known about the effect of underlying AA. Therefore, more investigations on the paradoxical effects of dupilumab on AA are needed in the current clinical trials.

References

1. Howell MD, Kim BE, Gao P, et al. Cytokine modulation of atopic dermatitis filaggrin skin expression. *J Allergy Clin Immunol* 2009;124:R7-12.
2. Wollenberg A, Wetzel S, Burgdorf
3. Kaminishi K, Soma Y, Kawa Y, Mizoguchi M. Flow cytometric analysis of IL-4, IL-13 and IFN-gamma expression in peripheral blood mononuclear cells and detection of circulating IL-13

WHC, Haas J. Viral infections in atopic dermatitis: Pathogenic aspects and clinical management. *J Allergy Clin Immunol* 2003;112:667-74.

- in patients with atopic dermatitis provide evidence for the involvement of type 2 cytokines in the disease. *J Dermatol Sci* 2002;29:19-25.
4. Seegräber M, Srouf J, Walter A, et al. Dupilumab for treatment of atopic dermatitis. *Expert Rev Clin Pharmacol* 2018;11:467-74.
 5. Suárez-Fariñas M, Ungar B, Noda S, et al. Alopecia areata profiling shows TH1, TH2, and IL-23 cytokine activation without parallel TH17/TH2 skewing. *J Allergy Clin Immunol* 2015;136:1277-87.
 6. Betz RC, Petukhova L, Ripke S, et al. Genome-wide meta-analysis in alopecia areata resolves HLA associations and reveals two new susceptibility loci. *Nature Commun* 2015;6:5966.
 7. Call JE, Sahni S, Zug KA. Effectiveness of dupilumab in the treatment of both atopic dermatitis and alopecia universalis. *Clini Case Rep* 2020;8:1337-9.
 8. Seegräber M, Srouf J, Walter A, et al. Dupilumab for treatment of atopic dermatitis. *Expert Rev Clin Pharmacol* 2018;11:467-74.
 9. Ständer S, Trense Y, Thaçi D, Ludwig RJ. Alopecia areata development in atopic dermatitis patients treated with dupilumab. *J Eur Acad Dermatol Venereol* 2020;34:e612-3.
 10. Gruenstein D, Malik K, Levitt J. Full scalp hair regrowth in a 4-year-old girl with alopecia areata and atopic dermatitis treated with dupilumab. *JAAD Case Rep* 2020;6:1286-7.

Non-commercial use only