

## Co-expression of CD34 and h-caldesmon in a benign meningioma-like dermal neoplasm, a case report

**Haitham Kussaibi**

**Pathology Department, Imam Abdulrahman bin Faisal University, Dammam, Saudi Arabia**

### Abstract

Meningioma-like dermal tumor with diffuse coexpression of CD34 and h-caldesmon is rarely reported. Herein, we report a case of a 58-years-old woman who complained of a solitary dome-shaped papule on the left hand. An ellipse of skin measuring 1 x 0.5 x 0.5 cm was excised and sent for histopathological evaluation. Upon sectioning, the specimen showed a whitish firm dermal nodule measuring 3 mm in its greatest dimension. Microscopic examination revealed a well-circumscribed barely encapsulated dermal lesion showing compact round whorled sheets formed of round to ovoid uniform cells with abundant pink cytoplasm. Occasional intranuclear vacuoles were seen. A minor capillary-sized vascular component was seen in the background. Immunohistochemical (IHC) study revealed a diffuse positivity of tumor cells to CD34 and h-caldesmon along with faint reaction to Smooth Muscle Actin (SMA) and ER. However, Desmin, S100, HMB45, EMA, Pan Cytokeratin, and Chromogranin were all negative. Ki67 was very low (1%). The main differential diagnoses of the current lesion are meningioma and glomus family tumors. While the current lesion is morphologically reminiscent of cutaneous meningioma; neither the location nor the IHC stains support that diagnosis. The glomus family is highly suggestive. However, the location, the compact nature of the proliferation, and the positivity of CD34, all are unusual in such entities.

### Introduction

Coexpression of CD34 and h-caldesmon is rarely reported in dermal tumors, especially with meningioma-like morphological appearance. An entity called meningioma-like tumor of skin (MLTS) was firstly described by Barr *et al.* in 1993 in a series of 3 cases as a whorled spindle cell superficial dermal proliferation, focally perivascular, which was positive for

Vimentin by Immunohistochemistry (IHC). It has been given its name due-to the whorled pattern of growth mimicking meningioma.<sup>1</sup> However, some authors considered MLTS an immature fibro-histiocytic tumor or a hemangiopericytoma. In 2019, Monteagudo *et al.* reported 2 more cases of MLTS, with a thorough review of the previously mentioned 3 cases. One of the cases showed large decudoid cells. Another case showed a chordoma-like appearance. All cases except one (tissue unavailable) showed diffuse positivity for CD34 by IHC study. However, S100, EMA, CD68, and smooth muscle markers were all negative.<sup>2</sup> On the other hand, Coexpression of CD34 and muscular markers was reported in the glomus tumors family, however, the CD34 expression is typically focal.<sup>4</sup> Glomus tumors are a family of usually benign tumors predominantly cutaneous, commonly seen in the subungual region. It is composed of glomus cells surrounding capillary-sized vessels with smooth muscle cells in different proportions. Based on these components, it is called glomus tumor, glomangioma, or glomangiomyoma.<sup>3</sup>

Endometrial stromal tumors, myofibroblastoma in the breast<sup>5</sup> and vagina, and hemangiopericytoma among other rare lesions are also coexpressing CD34 and muscular markers. Herein, we report a case of a meningioma-like benign dermal tumor with diffuse coexpression of CD34 and h-caldesmon along with a focal expression of ER.

### Case Report

A 58-years-old woman who complained of a solitary dome-shaped papule on the left hand. An ellipse of skin measuring 1 x 0.5 x 0.5 cm was excised and sent for histopathological examination. Upon sectioning, an underlying whitish firm dermal nodule measuring 3 mm in its greatest dimension was seen.

Microscopic examination revealed a well-circumscribed barely encapsulated dermal lesion forming compact proliferation of round to ovoid cells arranged in round solid sheets surrounded, peripherally, by some nerves and vessels. Tumor cells were almost uniform with abundant pink cytoplasm. Occasional intracytoplasmic vacuoles were seen. Nucleoli were inconspicuous. No mitotic figures were seen (Figure 1).

IHC stains were performed on formalin-fixed paraffin-embedded tissue with proper internal and external tissue controls. Tumor cells were diffusely positive for Vimentin,

Correspondence: Haitham Kussaibi, Pathology Department, Imam Abdulrahman bin Faisal University, Dammam, Saudi Arabia  
Tel.: +966554310433  
E-mail: hkussaibi@iau.edu.sa

**Key words:** glomangioma; myopericytoma; meningioma-like tumor of skin; cellular neurothekeoma; cutaneous hemangiopericytoma.

**Acknowledgments:** The author is grateful to Prof. Dr. Ritesh Menezes for reviewing this case.

**Conflict of interest:** The author declares no potential conflict of interest.

Received for publication: 23 October 2020.  
Accepted for publication: 19 November 2020.

This work is licensed under a Creative Commons Attribution-NonCommercial 4.0 International License (CC BY-NC 4.0).

©Copyright: the Author(s), 2020  
Licensee PAGEPress, Italy  
Dermatology Reports 2020; 12:8994  
doi:10.4081/dr.2020.8994

CD34, and h-caldesmon with a faint reaction to SMA and ER. However, Desmin, S100, HMB45, Pan CK, EMA, and Chromogranin were all negative. Ki67 was very low (1%). CD31 and Factor VIII highlighted the vascular background (Figure 2).

### Discussion

The lesion described here represents a meningioma-like dermal tumor with a co-expression of CD34 and h-caldesmon. The main differential diagnoses are cutaneous meningioma and glomus tumors family.

While the current lesion is morphologically reminiscent of *cutaneous meningioma*; neither the location nor the IHC stains support that diagnosis. Cutaneous meningioma is usually seen in the scalp and is believed to originate from a rudimentary meningocele.<sup>6</sup> Furthermore, CD34 expression along with the absence of EMA and PR expression make that diagnosis less likely in the current case.

Although, tumors of the glomus family are highly suggestive here, the location, the compact nature of the proliferation, and the diffuse positivity of CD34 are all unusual in such entities.<sup>7</sup> However, CD34 focal expression was reported in Glomus tumors throughout the body.<sup>8,9</sup> Keeping in mind the minor vascular component formed of capillary-sized vessels; *solid glomus* tumor has a close growth pattern to the current case.

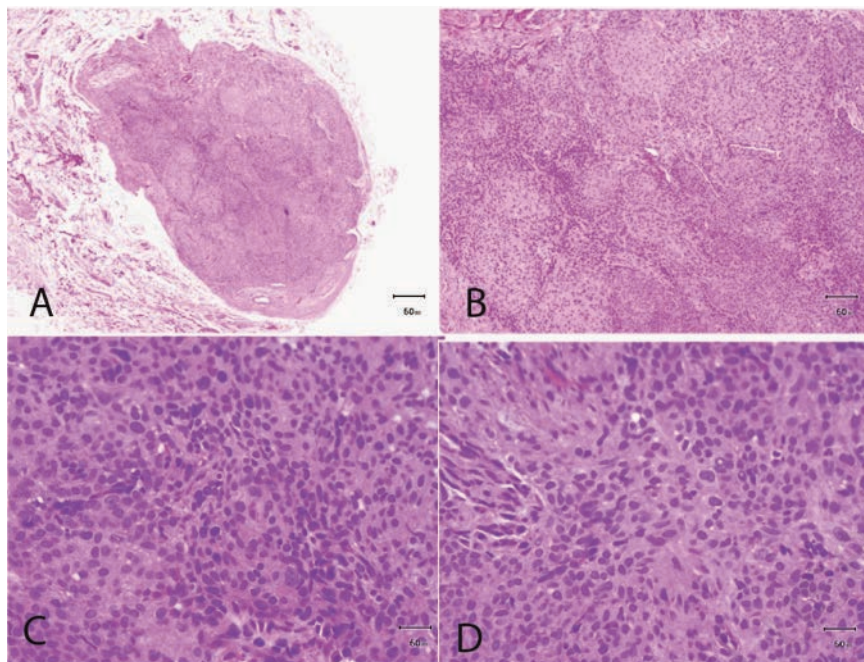
Furthermore, ER was reported to be positive in glomangiomyoma of the vagina among other organs in women.<sup>10</sup> Other differential diagnoses were suggested in the current case. However, none of them did fit

with the histology and IHC here. Meningioma-like tumor of the skin usually showed a whorled spindle cell proliferation, focally perivascular, with an IHC reaction to CD34 but not muscular markers.<sup>2</sup> One of

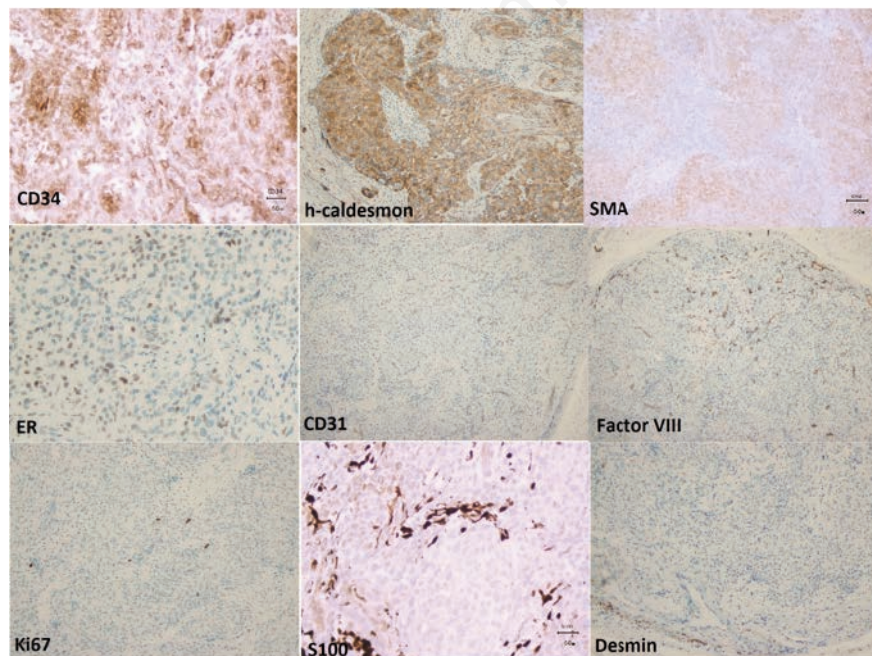
the reported MLTS showed a decuoid appearance like the current case. However, h-caldesmon was positive in the tumor here.

Polypoid dermal hemangiopericytoma looks like the present case in many aspects including lobulation and perivascular arrangement. However, a staghorn pattern of vascular channels, characteristic to hemangiopericytoma, was not seen here. Furthermore, CD34 expression is very unusual in hemangiopericytoma.<sup>11</sup>

Cellular neurothekeoma, a rare entity, has a marked resemblance to what we described herein, except for the myxoid matrix, and the diffuse positivity of CD34 which had not previously been described in neurothekeoma.<sup>12</sup>



**Figure 1. A) 5X Microscopic image (H&E stains): Well-circumscribed dermal lesion with scattered vessels and nerves at the periphery, B) 10X Microscopic images (H&E stains): Lesion reveals a compact whorled lobulated growth pattern with a minor capillary-sized vascular background, C and D) 40X Microscopic images (H&E stains): Tumor cells have abundant eosinophilic cytoplasm with bland-looking round, ovoid, focally spindled nuclei with focal nuclear inclusions. No mitosis or necrosis was seen.**



**Figure 2. The tumor is diffusely positive for CD34 and h-caldesmon, faintly positive for SMA and ER, and negative for Desmin and S100; Ki67 is very low (1%); CD31 and Factor VIII highlight the vascular background.**

## Conclusions

Accordingly, the most likely diagnosis of the present lesion is within the spectrum of glomus tumors that unusually, showed diffuse expression of CD34. However, other differential diagnoses still cannot be excluded.

## References

1. Barr RJ, Yi ES, Jensen JL, Wuerker RB, Liao SY. Meningioma-like tumor of the skin. An ultrastructural and immunohistochemical study. *Am J Surg Pathol* 1993;17:779-87.
2. Monteagudo C, Jiménez AI, Armandis A, Barr RJ. Meningioma-like Tumor of the Skin Revisited: A Distinct CD34+ Dermal Tumor With an Expanded Histologic Spectrum. *Am J Surg Pathol* 2019;43:1518-25.
3. Lee DW, Yang JH, Chang S, Won CH, Lee MW, Choi JH, et al. Clinical and pathological characteristics of extradigital and digital glomus tumours: a retrospective comparative study. *J Eur Acad Dermatol Venereol* 2011;25:1392-7.
4. Mravic M, LaChaud G, Nguyen A, Scott MA, Dry SM, James AW. Clinical and histopathological diagnosis of glomus tumor: an institutional experience of 138 cases. *Int J Surg Pathol* 2015;23:181-8.
5. Howitt BE, Fletcher CD. Mammary-type Myofibroblastoma: Clinicopathologic Characterization in a Series of 143 Cases. *Am J Surg Pathol* 2016;40:361-7.
6. Kishore M, Kaushal M, Bhardwaj M, Sharma N. Cutaneous Meningioma: A Cytomorphological Diagnosis. *Indian Dermatol Online J* 2017;8:201-4.
7. Choi JH, Ro JY. Epithelioid Cutaneous

- Mesenchymal Neoplasms: A Practical Diagnostic Approach. *Diagnostics (Basel)* 2020;10.
8. Mentzel T, Hugel H, Kutzner H. CD34-positive glomus tumor: clinicopathologic and immunohistochemical analysis of six cases with myxoid stromal changes. *J Cutan Pathol* 2002;29:421-5.
  9. Xu YY, Luo XM, Zhou SH, Zheng ZJ. CD34-positive expression in benign nasal glomus tumour: two case reports and a literature review. *J Int Med Res* 2010;38:2169-77.
  10. Rahimi S, Marani C, Balega J, Hirschowitz L. Glomangiomyoma of the Vagina: A Report of 2 Cases and Literature Review. *Int J Gynecol Pathol* 2017;36:334-8.
  11. Pollock AM, Sweeney EC. Polypoid dermal hemangiopericytoma: a case report. *Am J Dermatopathol* 1998;20:506-8.
  12. Kao EY, Kernig ML. Neurothekeoma. *StatPearls, Treasure Island (FL)*, 2020.

Non-commercial use only