

## Cephalexin-induced acute generalized exanthematous pustulosis

Matthew DaCunha, Sarah Moore,  
David Kaplan

University of Kansas Medical Center,  
Kansas City, Kansas, USA

### Abstract

Cephalexin is a cephalosporin antibiotic that is commonly used in the treatment of infectious diseases. We report a patient exhibiting a rare adverse effect of cephalexin: drug-induced Acute Generalized Exanthematous Pustulosis (AGEP). We present this case because of the scarcity of reports associating cephalexin with AGEP in hopes that clinicians will consider AGEP in their differential diagnosis in the appropriate clinical setting.

### Case Report

A 35-year-old female presented with a 10-day history of rash, starting on her left forearm, clinically diagnosed as a staphylococcal infection. The patient was started on cephalexin 500 mg three times a day by her primary care physician. She now presents with flat 2.0 cm superficially eroded plaques on her left forearm, which was the initial presenting lesion, as well as new erythematous eroding papules on the antecubital and popliteal fossa (Figure 1).

She describes the new lesions as both itchy and tender. She has stopped the antibiotics two days prior to this presentation. An initial bacterial culture taken by her primary care physician showed no growth. A repeat bacterial culture was obtained during this visit while starting a one-week course of trimethoprim/sulfamethoxazole. Mupirocin was also added to all affected areas. She returned four days later with more lesions appearing on the extremities (Figure 2).

A skin biopsy was obtained along with a CBC and chemistry panel as culture results again showed no growth. The histology was non-diagnostic, showing a neutrophilic inflammation within the epidermis and areas of confluent parakeratosis. She was again seen three days later as the rash continued to spread on the extremities. She complained of flu like symptoms including fever, sweats, and malaise. Her bloodwork was unremarkable. Skin biopsy was repeated since the previous was non-diagnostic.

Histology now showed intracorneal neutrophils and neutrophilic spongiosis along with pustule formation (Figure 3) consistent with Acute Generalized Exanthematous Pustulosis (AGEP), which correlated clinically. She was started on prednisone and resolved uneventfully over the next 2 weeks.

### Discussion

AGEP is a rare adverse reaction with only 3-5 cases per million per year.<sup>1-3</sup> Though AGEP is rare, more than 90% of AGEP cases are drug-induced with the most common offenders being beta-lactam antibiotics.<sup>1-4</sup> Cephalexin-induced AGEP, however, has only been reported in 3 case reports to our knowledge, making this case a probable 4<sup>th</sup> case supporting the connection between cephalexin and AGEP.<sup>5</sup> Cephalexin is an oral 1<sup>st</sup>-generation cephalosporin beta-lactam antibiotic that has been shown to have bactericidal activity via the inhibition penicillin-binding proteins.<sup>6</sup> In comparison to 2<sup>nd</sup> and 3<sup>rd</sup> generation cephalosporins, cephalexin has more activity against gram-positive organisms, with less activity against gram-negatives.<sup>1,2,7</sup> Common side effects of cephalexin include dyspepsia, gastritis, diarrhea, abdominal pain, and urticarial,<sup>1,2,7,8</sup> with AGEP being much rarer. Despite these adverse effects, cephalexin is a well-tolerated and effective bactericidal antibiotic used to treat gram-positive infections, making it a reasonable option in the treatment of common streptococcal and staphylococcal conditions including otitis media and pharyngitis.<sup>8</sup>

AGEP is a severe cutaneous reaction which is part of a group of pustular drug eruptions that commonly has a delayed diagnosis due to mimicking other rashes. Typically, the rash starts locally on flexor surfaces such as the groin and axilla, as in this case, before spreading into a more generalized distribution. AGEP presents as erythematous eruptions of pustules and papules. Although extremely uncommon, AGEP can present with signs of fever or malaise. Onset of rash usually occurs within 2 days of exposure to the offending agent, and typically resolves over the course of 1-2 weeks after discontinuation of the causative drug as the skin sheds and regenerates itself.<sup>1,9,10</sup>

Although biopsy can be used as a supportive measure in diagnosis, AGEP is often diagnosed clinically.<sup>1</sup> Treatment includes the discontinuation of the offending agent and infection prevention with topical anti-

Correspondence: David Kaplan, University of Kansas Medical Center, 4601 W 109th St., Suite 116, Overland Park, KS 66211, USA.  
E-mail: dookdoc@gmail.com

Acknowledgements: the authors would like to acknowledge Dr. Allison Lisle Cargnel for the histology image.

Key words: Tender; Erythematous; Pustular eruption; Drug reaction; Antibiotic.

Contributions: the authors contributed equally.

Conflict of interest: the authors declare no potential conflict of interest.

Funding: none.

Received for publication: 18 March 2018.

Revision received: 7 July 2018.

Accepted for publication: 19 July 2018.

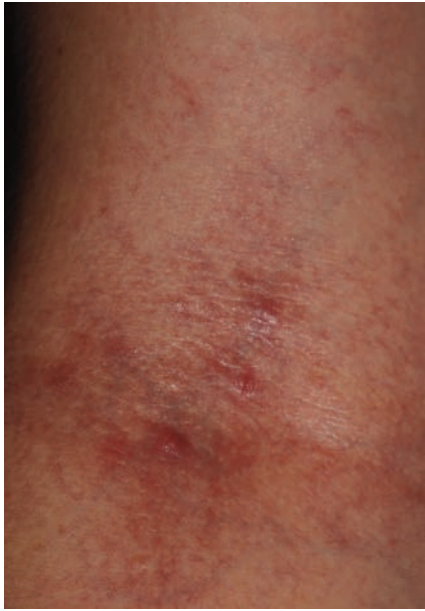
This work is licensed under a Creative Commons Attribution-NonCommercial 4.0 International License (CC BY-NC 4.0).

©Copyright M. DaCunha et al., 2018  
Licensee PAGEPress, Italy  
Dermatology Reports 2018; 10:7686  
doi:10.4081/dr.2018.7686

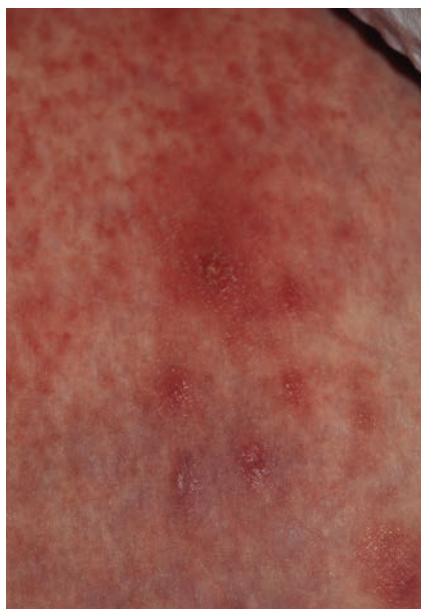otics. Additionally, topical corticosteroids are beneficial in the treatment of AGEP.<sup>9</sup>

### Conclusions

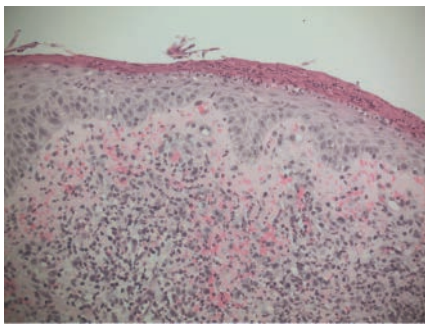
We present the challenges of diagnosing AGEP as its presentation can mimic other pustular eruptions. It can be difficult for the clinician to make an accurate and timely diagnosis. Clinical clues to diagnosis include flexural involvement of the rash, negative bacterial cultures, a recent exacerbation of symptoms while on appropriate antibiotic therapy. Clinical assessment diagnosis can be supported by histology with a skin biopsy.<sup>10</sup> We present this particular case because of the paucity of reports associating cephalexin with AGEP in hopes of having clinicians consider AGEP in their differential diagnosis in the appropriate clinical setting. To our knowledge, cephalexin-induced AGEP has only been reported in 3 previous case reports.<sup>5</sup> Although this case cannot conclusively say that AGEP was directly caused by cephalexin due to the delay in diagnosis, AGEP is the most likely diagnosis with cephalexin being the most probable cause. This would be the 4<sup>th</sup> probable case of cephalexin-induced AGEP. It is imperative for dermatologists to recognize the signs and symptoms of



**Figure 1.** Tender erythematous eroding papules on the antecubital fossa.



**Figure 2.** Tender erythematous papulopustular eruption of the proximal lower extremity.



**Figure 3.** Intracorneal neutrophils and neutrophilic spongiosis with subcorneal neutrophils forming pustule.

AGEP, as it may require the discontinuation of antibiotics such as cephalexin and prompt the use of alternative medications.<sup>1,9</sup> It is also important to communicate to the patient and interdisciplinary team members that the condition may be resolved more rapidly with the use of topical corticosteroids in addition to discontinuation of the offending agent.<sup>9,10</sup>

### References

1. Sidoroff A. Acute generalized exanthematous pustulosis. *Hautarzt* 2014;65:430-5.

2. Sidoroff A, Halevy S, Bavinck JN, et al. Acute generalized exanthematous pustulosis (AGEP)-a clinical reaction pattern. *J Cutan Pathol* 2001;28:113-9.
3. Cranga TA, Simpson MA, Featherstone P. Acute generalised exanthematous pustulosis (AGEP)-a potential pitfall for the acute physician. *Acute Med* 2016;15:140-4.
4. Roujeau JC, Bioulac-Sage P, Bourseau C, et al. Acute generalized exanthematous pustulosis. Analysis of 63 cases. *Arch Dermatol* 1991;127:1333-8.
5. Holscher CM, Mauck SK, Armstrong L, Buchanan JA. Man with rash and nausea. Acute generalized exanthematous pustulosis after cephalexin use. *Ann Emerg Med* 2011;58:508-16.
6. Williamson R, Collatz E, Gutmann L. Mechanisms of action of beta-lactam antibiotics and mechanisms of non-enzymatic resistance. *Presse Med* 1986;15:2282-9.
7. Gerald R, Donowitz MD, Gerald L, Mandell MD. Beta-Lactam Antibiotics. *N Engl J Med* 1988;318:490-500.
8. Thienvibul C, Vachiramon V, Chanprapaph K. Five-year retrospective review of acute generalized exanthematous pustulosis. *Dermatol Res Pract* 2015;2015:260928.
9. Kley C, Murer C, Maul JT, et al. Rapid involution of pustules during topical steroid treatment of acute generalized exanthematous pustulosis. *Case Rep Dermatol* 2017;9:135-9.
10. Speeckaert MM, Speeckaert R, Lambert J, Brochez L. Acute generalized exanthematous pustulosis: an overview of the clinical, immunological and diagnostic concepts. *Eur J Dermatol* 2010;20:425-33.