



Dermatology Reports

<https://www.pagepress.org/journals/index.php/dr/index>

eISSN 2036-7406



Publisher's Disclaimer. E-publishing ahead of print is increasingly important for the rapid dissemination of science. **Dermatology Reports** is, therefore, E-publishing PDF files of an early version of manuscripts that undergone a regular peer review and have been accepted for publication, but have not been through the copyediting, typesetting, pagination and proofreading processes, which may lead to differences between this version and the final one. The final version of the manuscript will then appear on a regular issue of the journal. E-publishing of this PDF file has been approved by the authors.

Please cite this article as: Corrado Zengarini, Claudia Sapigni, Mattia Benati, et al. An out-of-season cold: filler-induced vascular occlusion of the columellar artery causing necrosis of the cartilaginous anterior nasal septum case report and a literature review Dermatol Rep 2024 [Epub Ahead of Print] doi: 10.4081/dr.2024.10061

 © the Author(s), 2024
Licensee [PAGEPress](https://www.pagepress.org), Italy

Submitted 07/06/24 – Accepted 23/08/24

Note: The publisher is not responsible for the content or functionality of any supporting information supplied by the authors. Any queries should be directed to the corresponding author for the article.

All claims expressed in this article are solely those of the authors and do not necessarily represent those of their affiliated organizations, or those of the publisher, the editors and the reviewers. Any product that may be evaluated in this article or claim that may be made by its manufacturer is not guaranteed or endorsed by the publisher.

An out-of-season cold: filler-induced vascular occlusion of the columellar artery causing necrosis of the cartilaginous anterior nasal septum case report and a literature review

Corrado Zengarini,^{1,2} Claudia Sapigni,^{3,4} Mattia Benati,^{3,4} Giovanni D'Agostino,⁵ Bianca Maria Piraccini,^{1,2} Davide Melandri,^{1,3} Antonio Russo,^{3,4} Società Italiana di Dermatologia Chirurgica, Oncologica, Correttiva ed Estetica (SIDCO)

¹Dipartimento di Scienze Mediche e Chirurgiche, Università degli Studi di Bologna, Bologna;

²IRCCS Azienda Ospedaliero-Universitaria di Bologna, Bologna;

³Skin-Clinic, Forlì, Forlì-Cesena;

⁴SOC Centro Grandi Ustionati/Dermatologia Cesena (Forlì), AUSL Romagna, Forlì-Cesena;

⁵Otorinolaringoiatria, ORL Ospedali Privati Forlì S.p.a., Forlì-Cesena, Italy;

Corresponding author: Corrado Zengarini, Dipartimento di Scienze Mediche e Chirurgiche, Università di Bologna, via Massarenti 1, 40138 Bologna, Italy.

Tel. +39051-2144849. Fax +39-0512144867.

E-mail: corrado.zengarini@studio.unibo.it

Key words: FIVO, septal branch, superior labial artery.

Authors' contributions: all the authors made a substantive intellectual contribution. All the authors have read and approved the final version of the manuscript and agreed to be held accountable for all aspects of the work.

Conflict of interest: the authors declare no potential conflict of interest.

Funding: none.

Ethics approval and consent to participate: not required.

Informed consent: the patient in this manuscript has given written informed consent to publish her case details.

Availability of data and materials: data is available upon request from the authors.

Abstract

In their recent publication, George Kroumpouzou *et al.* provided a comprehensive update on the complications caused by filler procedures in the lips and perioral area. These injections have been associated with various arterial accidents and an incidence of vision loss mainly when such procedures are performed at the level of the central facial massif.

Among the various cases of vascular involvement reported in the literature, we have found what we believe to be a rare occurrence of columellar artery occlusion with a noteworthy discrepancy between the expected symptoms and the actual described vascular effects. The necrosis of the columellar artery following hyaluronic acid injections showed some peculiarities: its frequency is unknown, and recognition can be troublesome due to the presentation of subtle symptoms. We want to exemplify these characteristics in this case, which, fortunately, optimally resolved itself, underscoring its unique nature.

Introduction

In their recent publication, George Kroumpouzos *et al.*¹ provided a comprehensive update on the complications caused by filler procedures in the lips and perioral area. These injections have been associated with various arterial accidents and an incidence of vision loss mainly when such procedures are performed at the level of the central facial massif.

Among the various cases of vascular involvement reported in the literature, we have found what we believe to be a rare occurrence of columellar artery occlusion with a noteworthy discrepancy between the expected symptoms and the actual described vascular effects. The necrosis of the columellar artery following hyaluronic acid injections showed some peculiarities: its frequency is unknown, and recognition can be troublesome due to the presentation of subtle symptoms. We want to exemplify these characteristics in this case, which, fortunately, optimally resolved itself, underscoring its unique nature.

Case Report

A 30-year-old Italian female was consulted for an aesthetic treatment for the nose, which presented a slightly convex curvature (c+) and a sub-projection (p-) in the lateral plane.² After carrying out a full-face cosmetic approach,³ we proposed a rhino-filler treatment with 1.2 ml of high-visco-elastic crosslinked hyaluronic acid added with lidocaine.

To enhance lateral nasal projection, 0.8 ml of product was injected at the root of the nasal bones and 0.4 ml on the periosteal plane at the columellar-nose angle. All maneuvers were executed with a 27-gauge needle already in dotation without using a cannula. The filler was administered in bolus, and a gentle aspiration was executed before every injection.

Subsequently, the patient was kept in observation for one hour and sent home without reported signs or symptoms.

The patient initially reported excellent satisfaction with the aesthetic profile at the two-week follow-up. However, two to three days after the treatment, she began experiencing a constant runny nose and

a peculiar perception of air as cold. These symptoms, which were initially subtle, led us to suspect a complication caused by the injections, prompting a rhinoscopy examination that revealed a full-thickness necrosis of the anterior wall of the nasal septum (Figure 1A).

The use of a bolus injection of 1.200 U.I of hyaluronidase, 1/2 vial at the injection site at the level of the columellar area and the other half around the lesion at the level of the septal mucosa, the prescription of 100mg of aspirin daily, and the application of local mupirocin resolved the ulcer and reported symptoms in two weeks (Figure 1B).

The potential trigger that could have induced this condition was damage to the Kiesselbach area, and the most plausible explication was compression or embolization of the septal branch of the superior labial artery after injection at the nasolabial angle.

The columnar artery of the nose, also known as the septal branch of the superior labial artery, is a minor anastomotic vessel of Kiesselbach's plexus (Little's area) and supplies blood to a small part of the nasal cavity and the anterior nasal septum. Kiesselbach plexus also regulates blood flow to the mucosa, which helps maintain the appropriate hydration level and oxygenation to the nasal cavity. Additionally, this plexus is a common location for *epistaxis* (nosebleeds) due to the fragility of the vessels in this area. Its main tributary arteries are the anterior ethmoidal artery, a branch of the internal carotid artery, and the greater palatine artery and sphenopalatine artery, which are branches of the maxillary artery. These two account for most of the blood supply of Little's area, but in some anatomical variants, the blood inflow of the columnar artery can be so crucial that its closure may not be sufficiently overcome by other vessels in the anterior portion of the cartilaginous nasal septum, causing its necrosis.^{3,4} Since nasal mucosal is fundamental to heat the air circulating from the exterior to the upper airways, it explains the "cold air" symptoms the patient expressed.

Similar cases in the literature

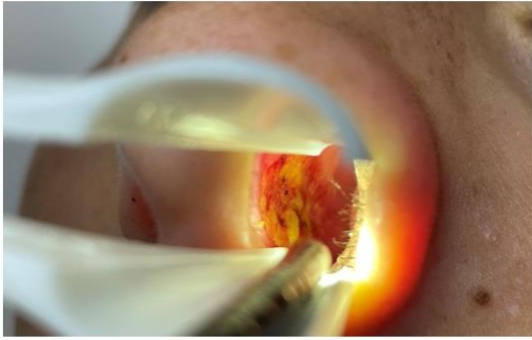
We performed an extensive literature review looking for similar cases reported using the search strings on MEDLINE and SCOPUS databases: Columellar AND (Filler OR Occlusion OR Ischemia, Nasal AND (Septal OR septum) AND (Wound OR Ulcer OR Ischemia).

To date, only one case described by Souza *et al.*⁵ seemed to have a similar course, while another reported by Kim KS *et al.*⁶ had much more intense symptoms and included a turbinate vascular involvement. However, as already stated by other authors,¹ it is recognized that filler adverse effects are underdiagnosed and underreported, and it is reasonable to assume that there could be many similar cases.

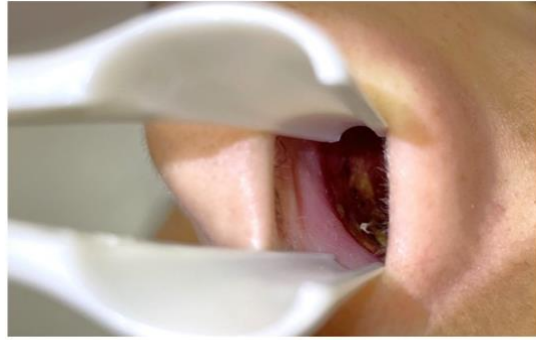This case is a stark reminder of the need for vigilance and prompt action in the face of filler complications. It underscores that these complications should always be considered, even weeks after the procedures, even in the absence of overt symptoms and visible dermatological changes.

References

1. Kroumpouzos G, Harris S, Bhargava S, Wortsman X. Complications of fillers in the lips and perioral area: Prevention, assessment, and management focusing on ultrasound guidance. *Journal of Plastic, Reconstructive & Aesthetic Surgery*. 2023;84:656-69.
2. Kienstra MA, Gassner HG, Sherris DA, Kern EB. A Grading System for Nasal Dorsal Deformities. *Archives of Facial Plastic Surgery*. 2003;5:138-43.
3. Mağden O, Edizer M, Atabey A, et al. Cadaveric Study of the Arterial Anatomy of the Upper Lip: *Plastic and Reconstructive Surgery*. 2004;114:355-9.
4. MacArthur FJD, McGarry GW. The arterial supply of the nasal cavity. *Eur Arch Otorhinolaryngol*. 2017;274:809-15.
5. Souza Felix Bravo B, Mariano Da Rocha CR, Gonçalves Bravo L, et al. Septal Ulcer After Nasal Filling with Hyaluronic Acid. *J Clin Aesthet Dermatol*. 2021;14:24-6.
6. Kim KS, Min HJ. Delayed Diagnosis of Septal Ulcer after Hyaluronic Acid Nasal Filler Injection. *Journal of Craniofacial Surgery*. 2024;35:e185.



A



B

Figure 1. A) rhinoscopy of the left nasal mucosal septum, where we can note the ulceration of the anterior mucosal area. B) rhinoscopy of the left nasal mucosal septum four weeks after treatments of hyaluronidase and aspirin, where it showed a complete resolution of the wound.